

RESULTS OF ARTHROSCOPIC MINIMAL EXCISION ARTHROPLASTY OF THE ACROMIOCLAVICULAR JOINT

C.K. Yiannakopoulos, A. Marsh, A.Iossifidis

Shoulder Unit, Mayday University Hospital,
London, UK

The acromioclavicular joint (ACJ) is a common but overlooked source of shoulder problems.

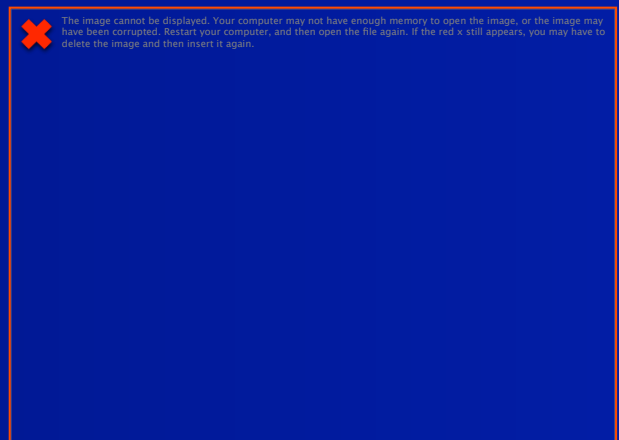Degenerative disease of the ACJ accompanies:

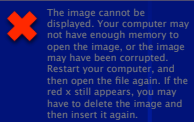
- ✓ extrinsic impingement
- ✓ cuff deterioration
- ✓ isolated (osteolysis)
- ✓ osteoarthritis

 The image cannot be displayed. Your computer may not have enough memory to open the image, or the image may have been corrupted. Restart your computer, and then open the file again. If the red x still appears, you may have to delete the image and then insert it again.

Acromioclavicular Joint Arthritis

- ✓ Debridement /Synovectomy
- ✓ Excision Arthroplasty
- ✓ Arthrodesis



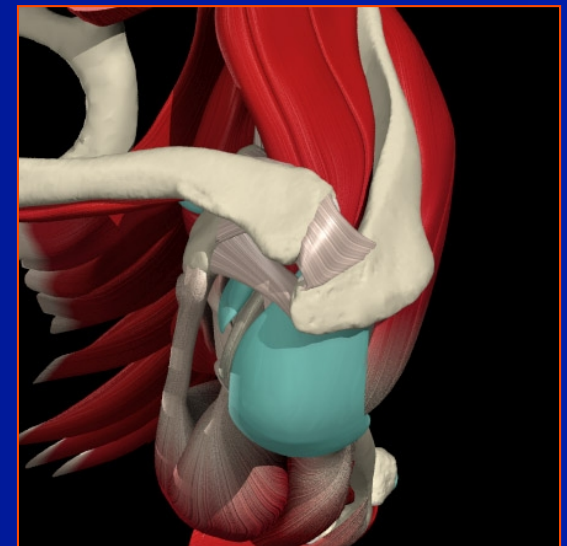


Arthroscopic ACJ Arthroplasty

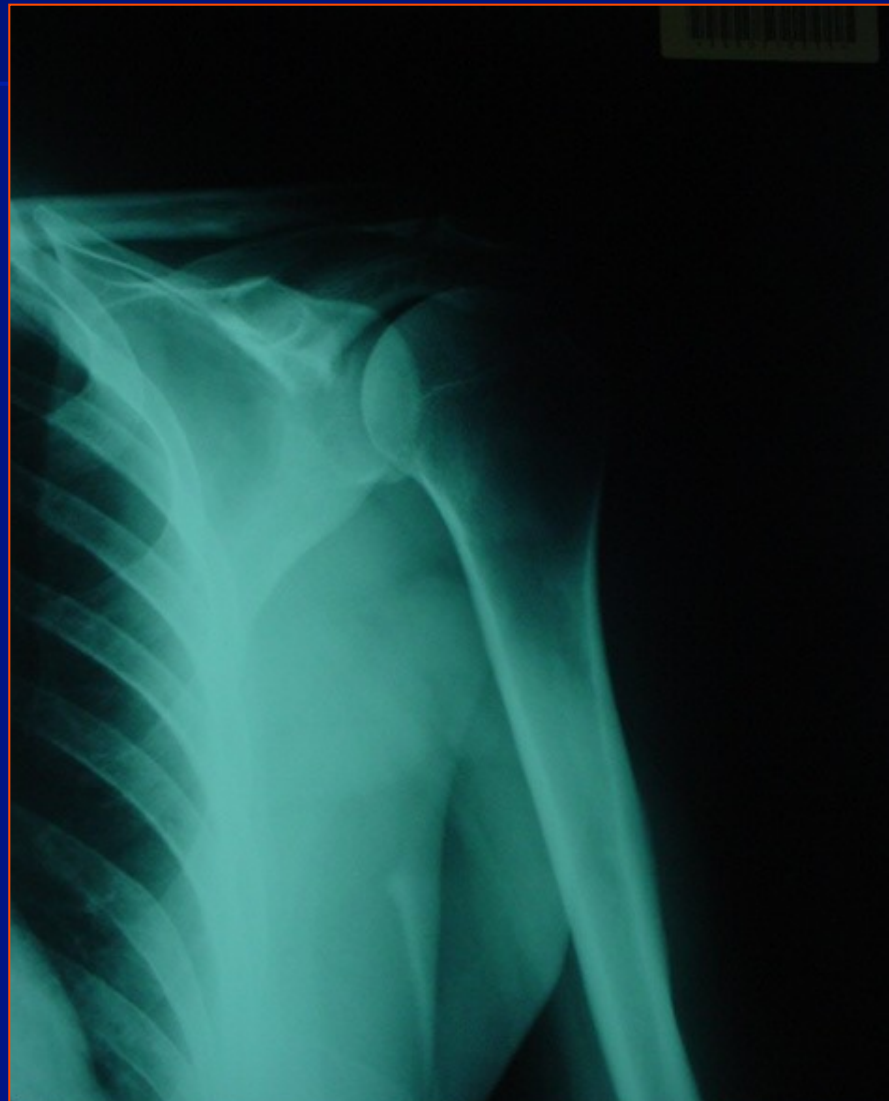
- ✓ 218 arthroscopies (2002-2003)
- ✓ 22 patients , 15 F
- ✓ Mean age: 51 (38 to 64)
- ✓ Prospective assessment
- ✓ Mean follow-up: 17 months (12 to 29)

Arthroscopic ACJ Arthroplasty

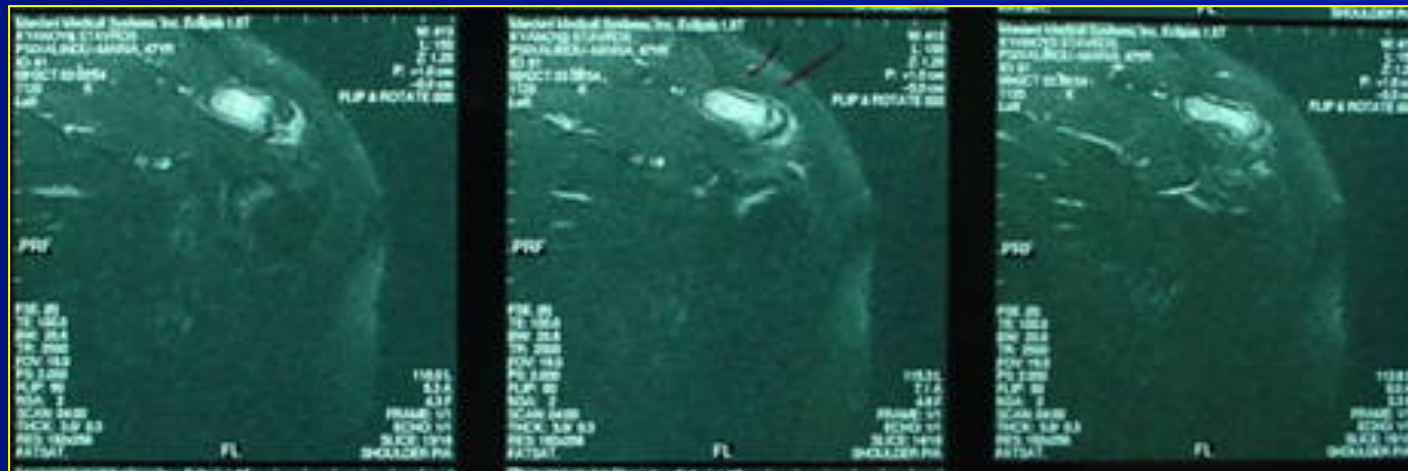
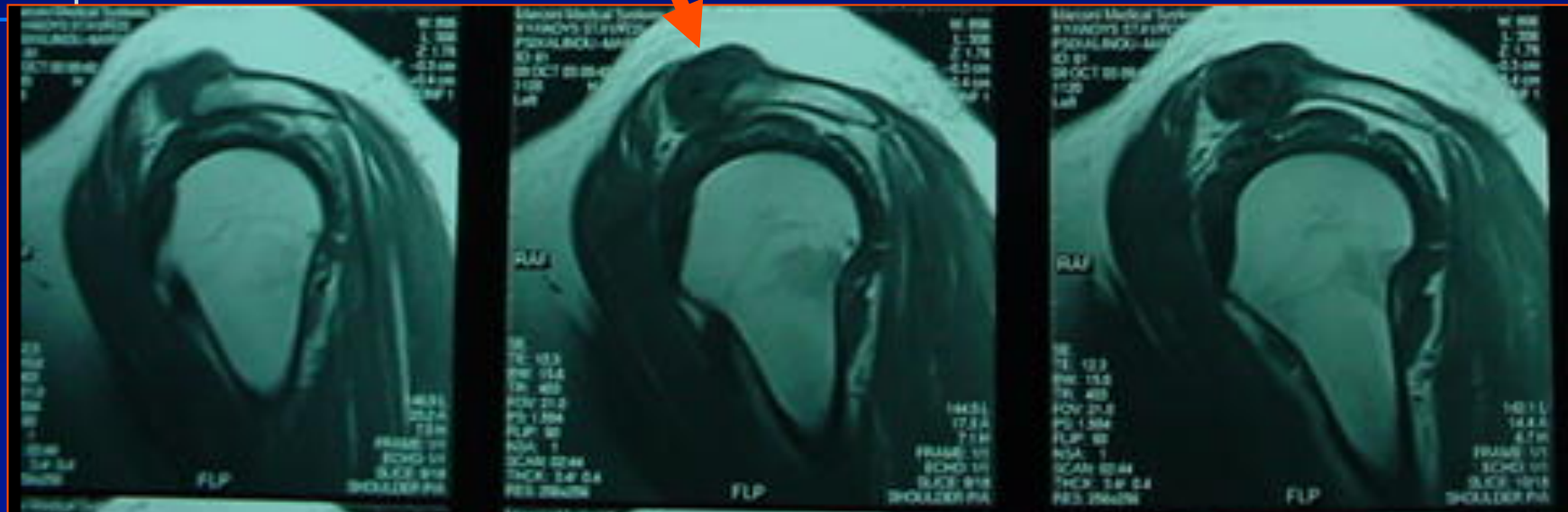
- ✓ ACJ symptoms for > 6 months
- ✓ High Painful arc
- ✓ Positive provocative & injection tests



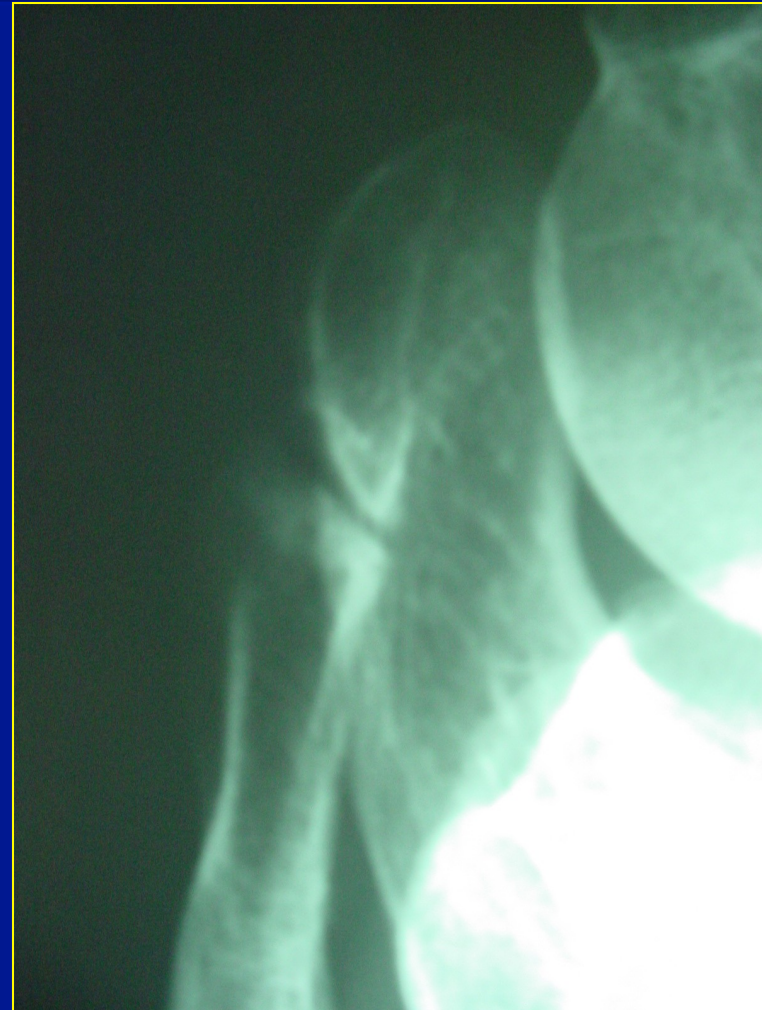
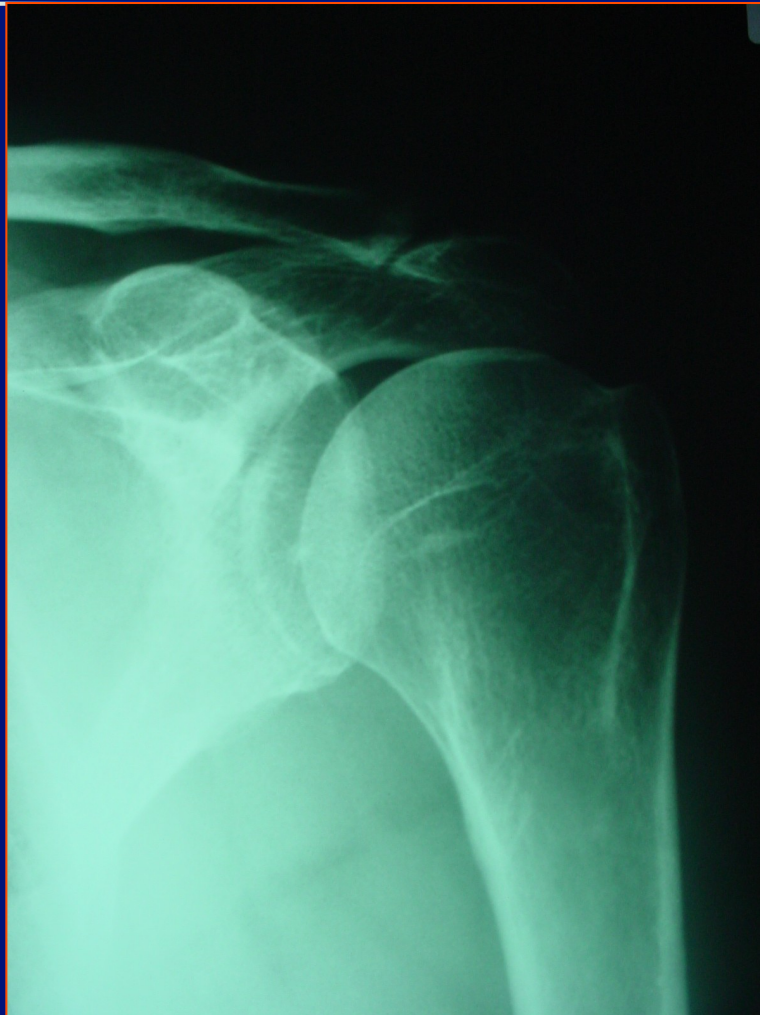Radiographic Evaluation of the ACJ



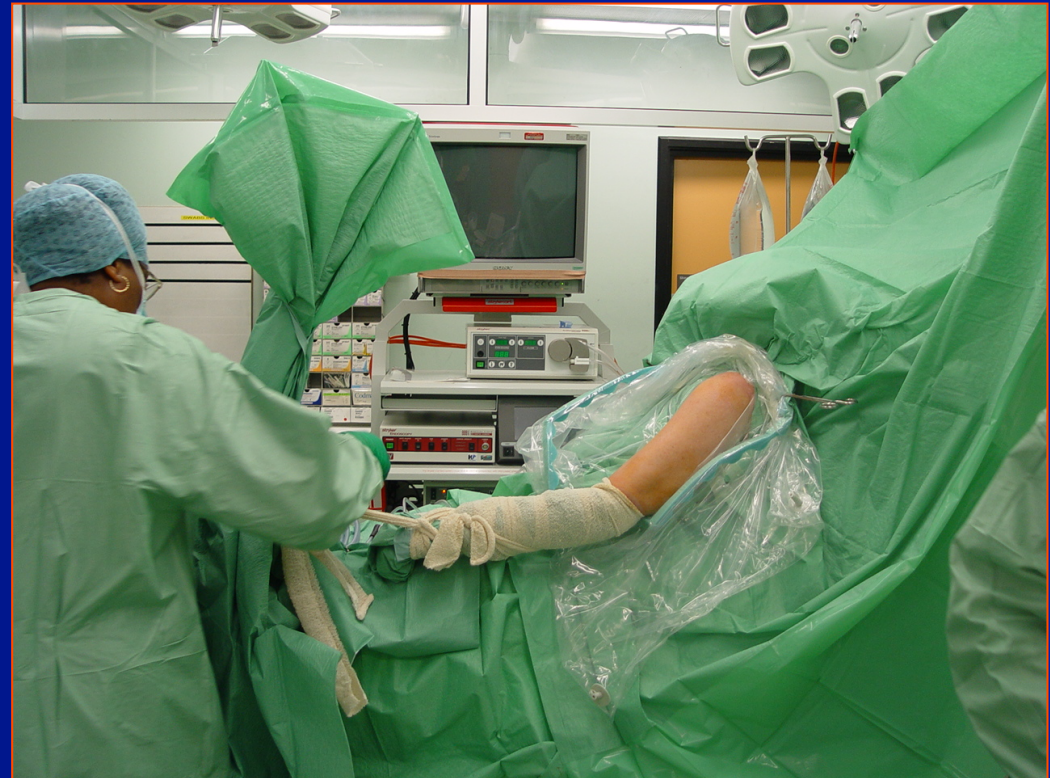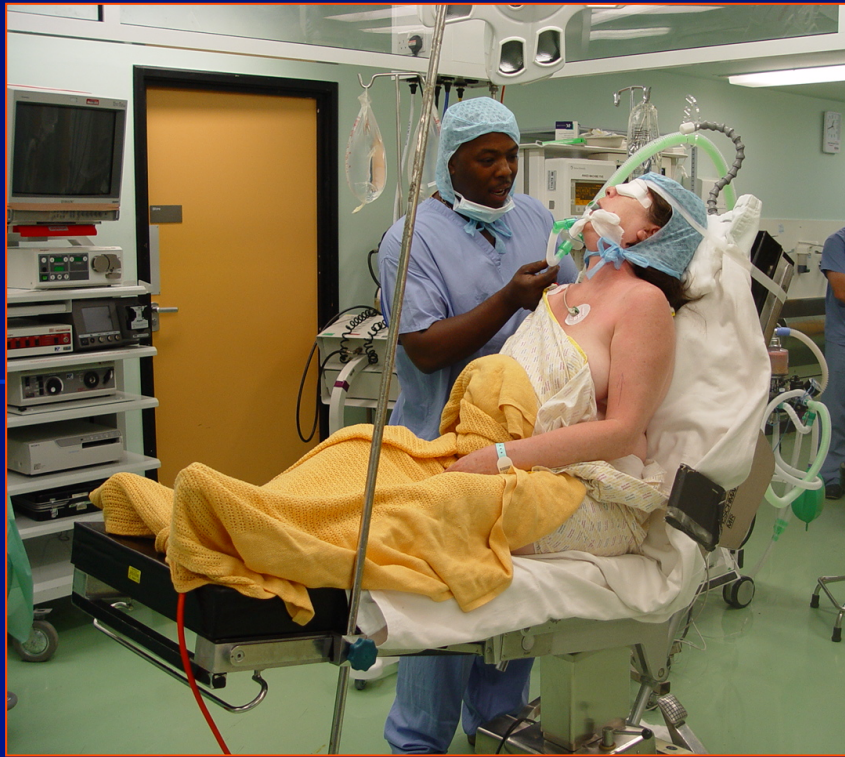Radiographic Evaluation of the ACJ



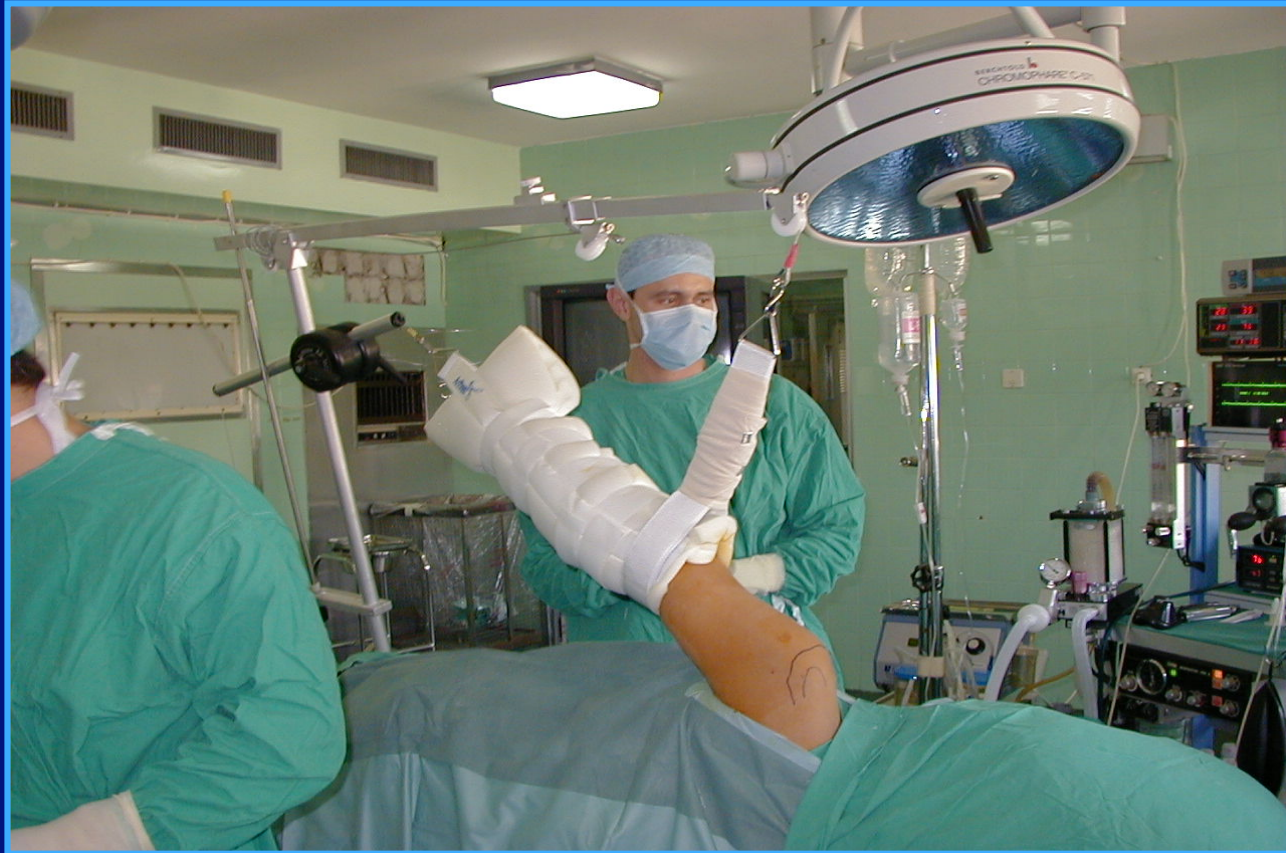Radiographic Evaluation of the ACJ



Beach Chair Position



Lateral Decubitus Position

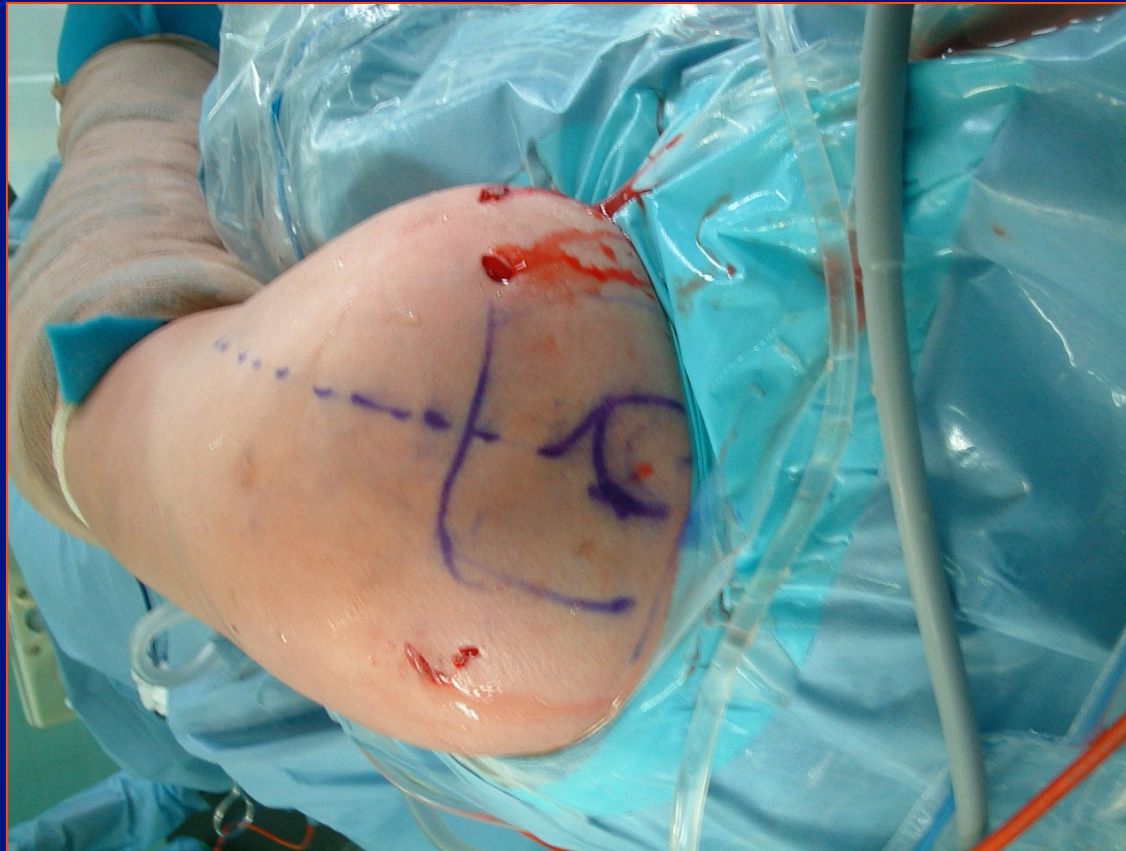

Arthroscopic Subacromial Excision of the ACJ

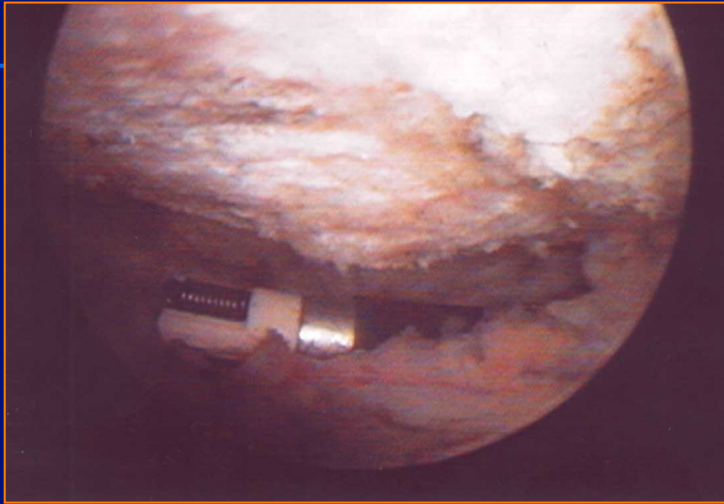


The image cannot be displayed. Your computer may not have enough memory to open the image, or the image may have been corrupted. Restart your computer, and then open the file again. If the red x still appears, you may have to delete the image and then insert it again.

Arthroscopic Portals

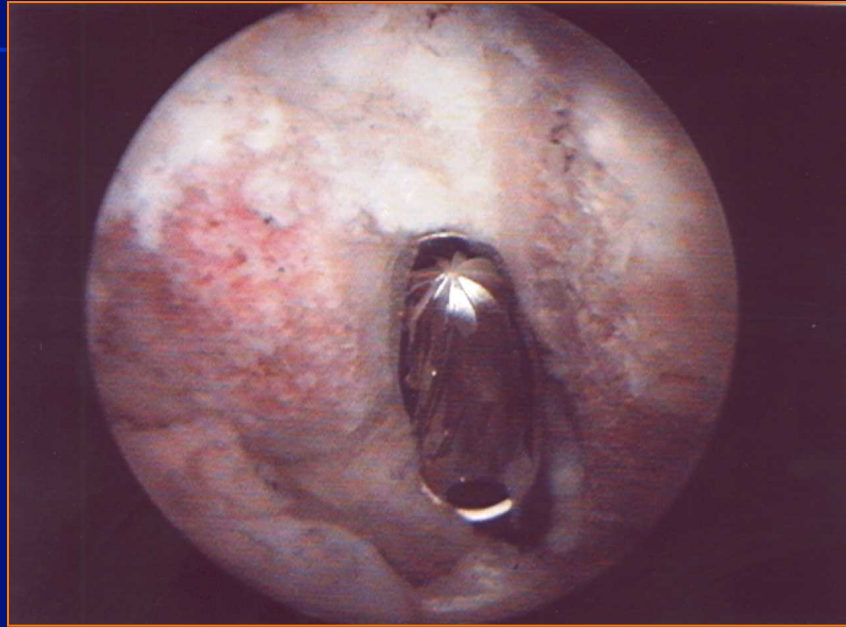


Arthroscopic ACJ arthroplasty

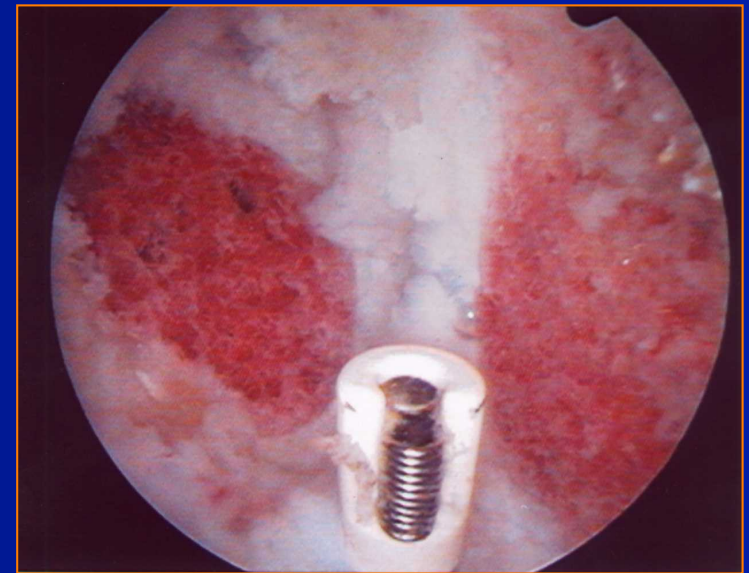


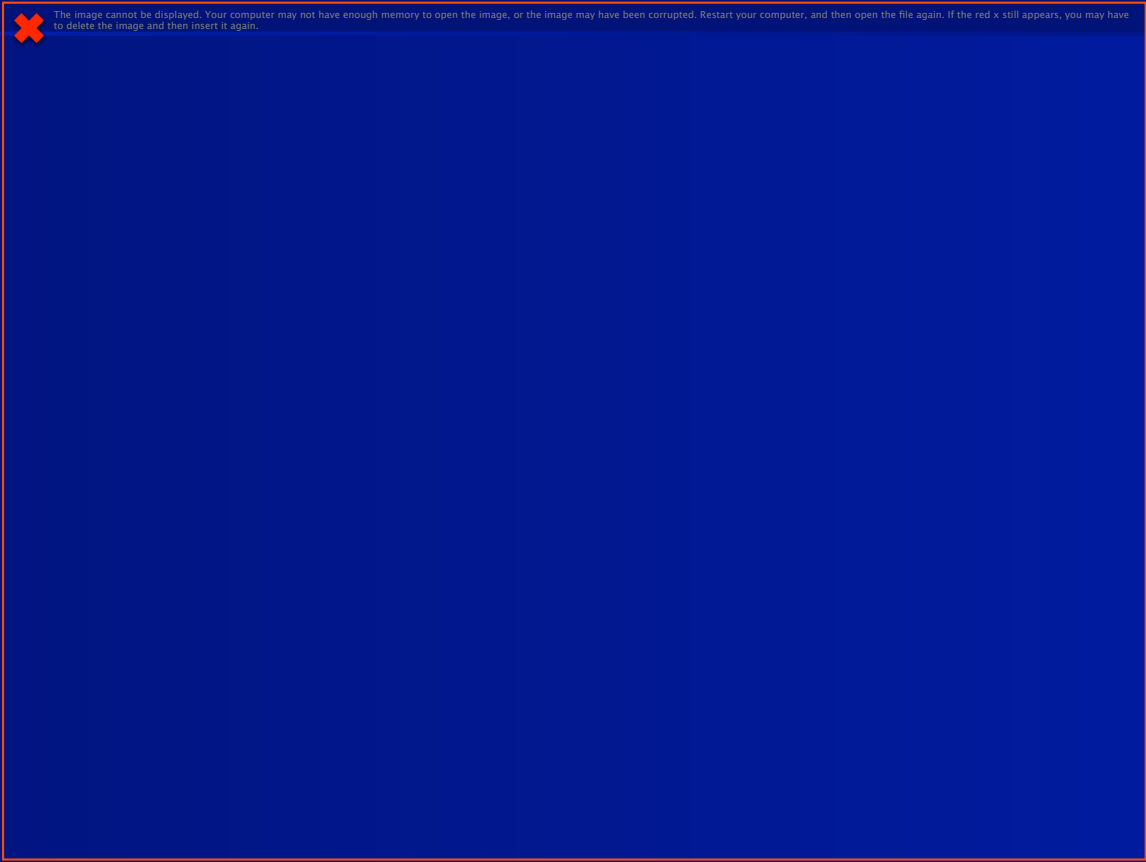
The image cannot be displayed. Your computer may not have enough memory to open the image, or the image may have been corrupted. Restart your computer, and then open the file again. If the red x still appears, you may have to delete the image and then insert it again.


Arthroscopic ACJ Arthroplasty



15 mm of bone is resected
15 mm of bone is resected



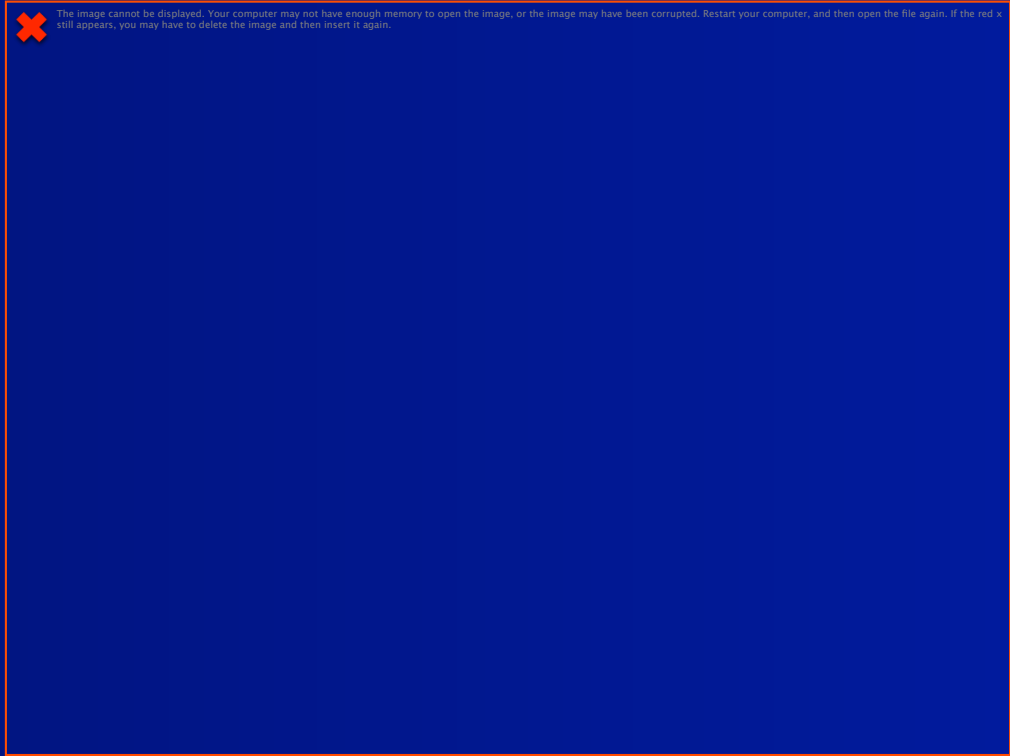






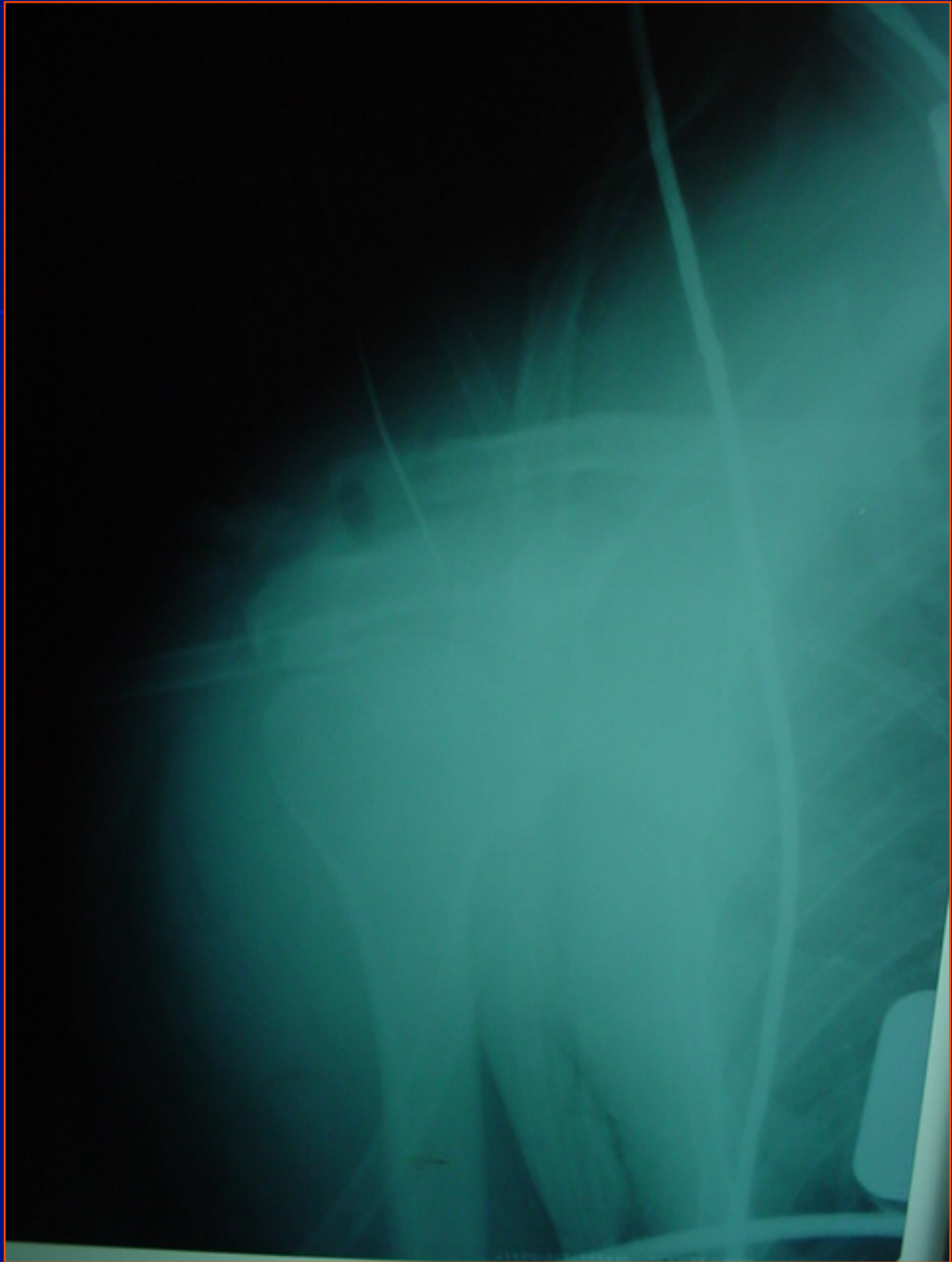

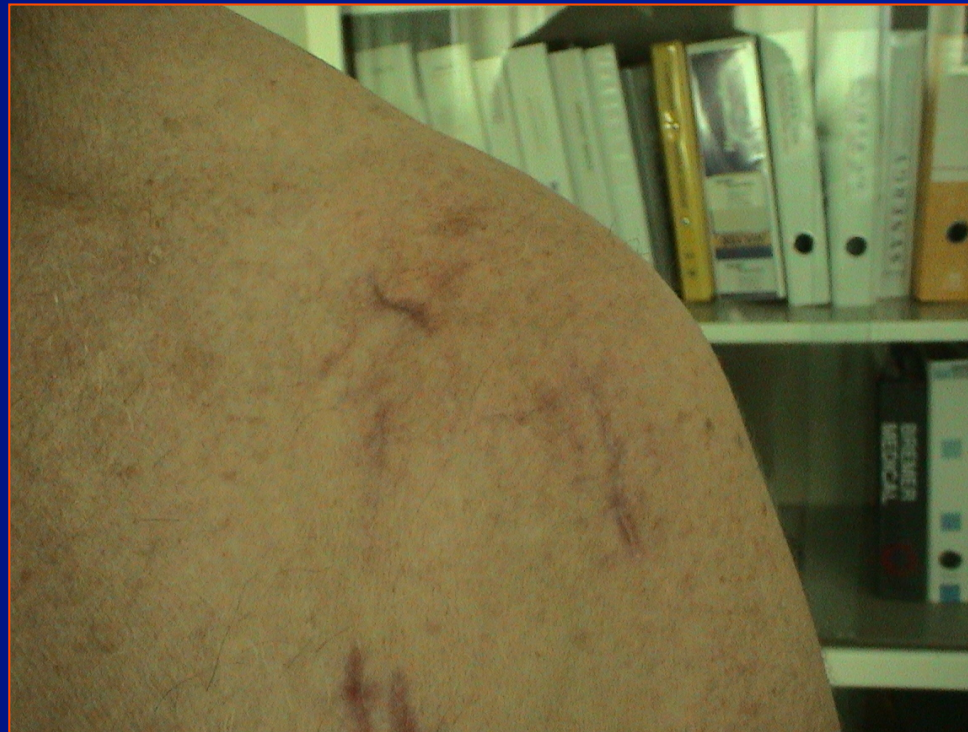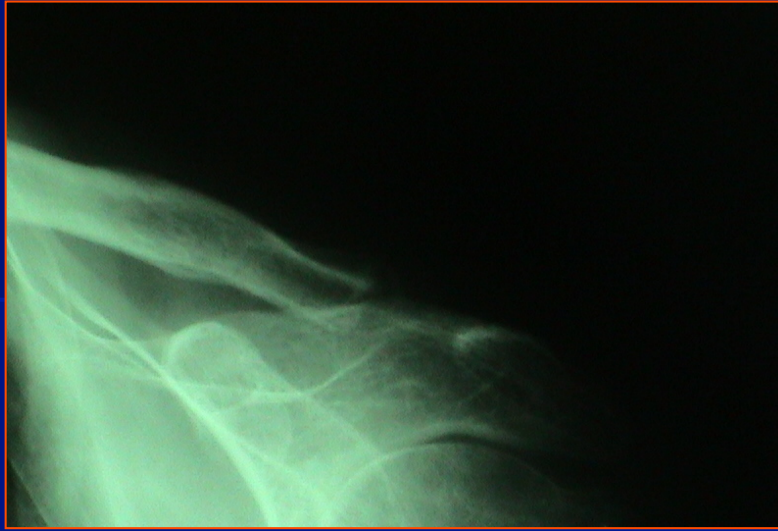
The image cannot be displayed. Your computer may not have enough memory to open the image, or the image may have been corrupted. Restart your computer, and then open the file again. If the red x still appears, you may have to delete the image and then insert it again.





The image cannot be displayed. Your computer may not have enough memory to open the image, or the image may have been corrupted. Restart your computer, and then open the file again. If the red x still appears, you may have to delete the image and then insert it again.







Postoperative Evaluation

- ✓ Constant score
- ✓ Self Assessment Questionnaire
 - ✓ 11 activities of daily living
 - ✓ shoulder function
 - ✓ satisfaction

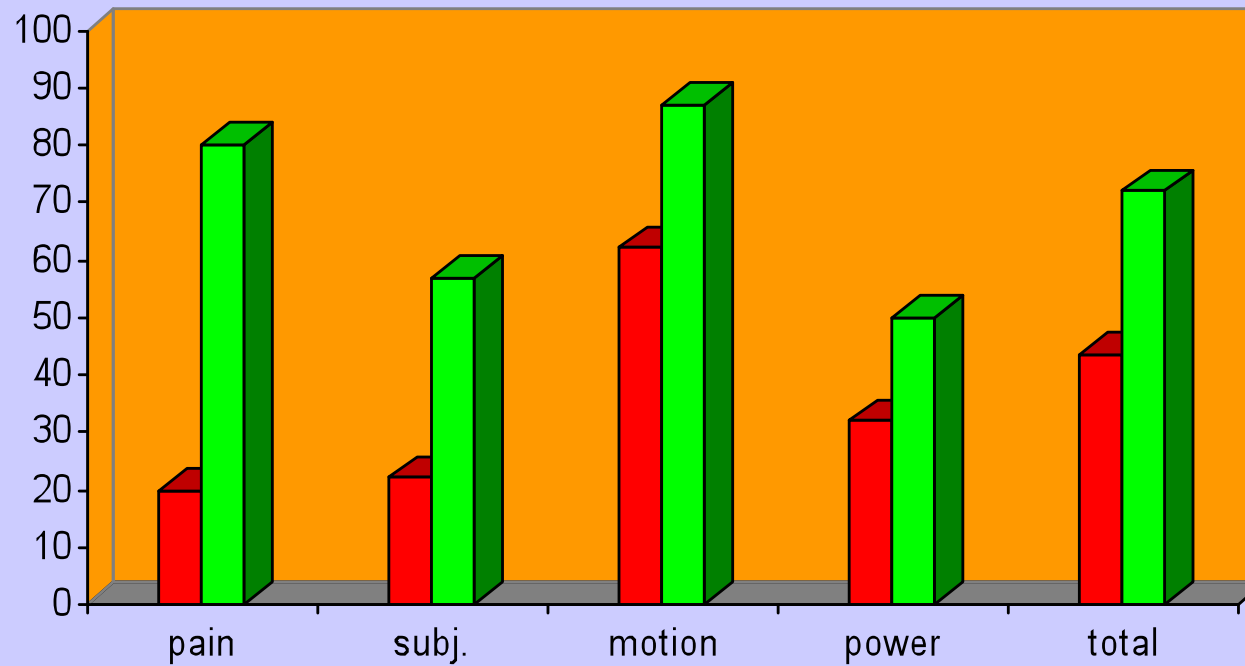
Constant score

	pre-op	post-op	normal
pain	2,3	12	15
subjective	7,6	15,6	35
motion	15	33,5	40
power	3,5	10,3	25
total	28,4	71,4	100

Arthroscopic ACJ Arthroplasty

Constant Score

pre-op post-op

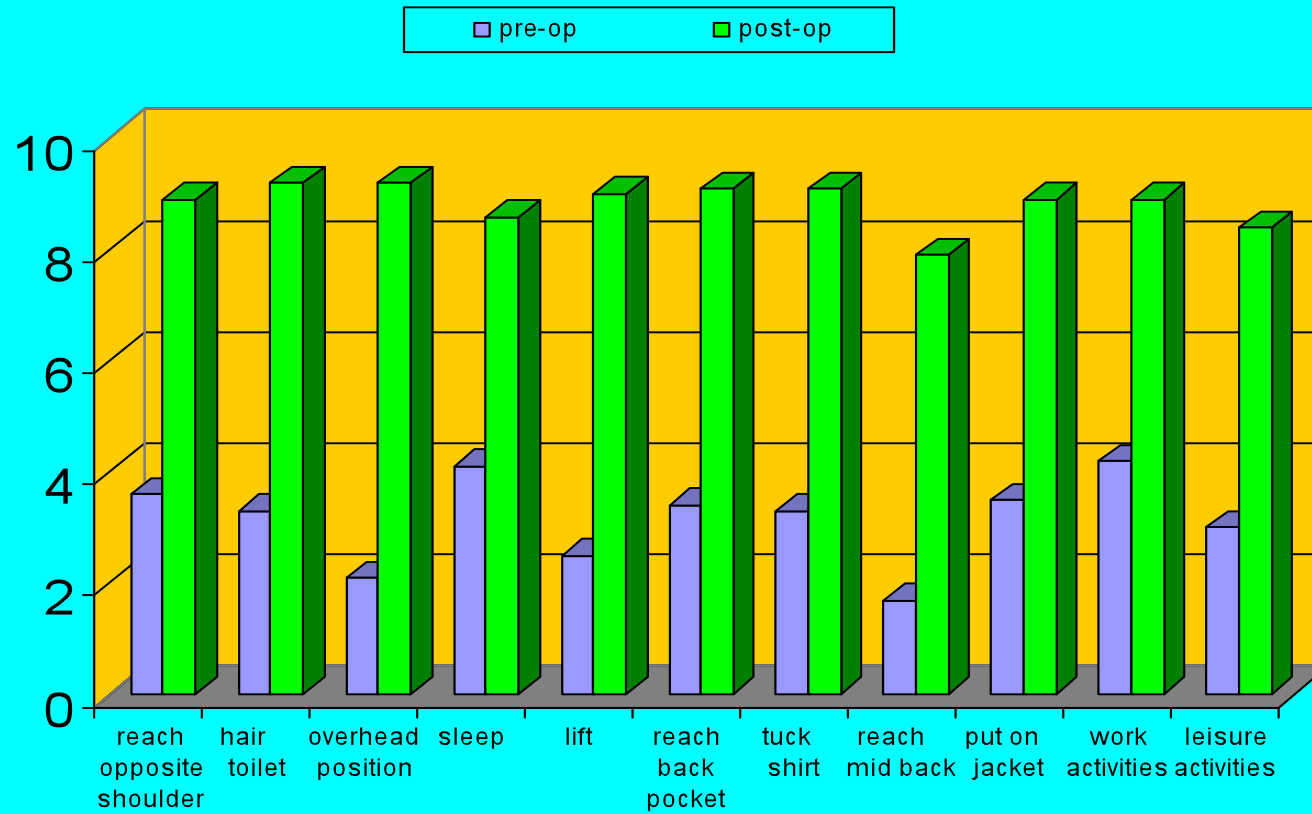


Arthroscopic ACJ Arthroplasty

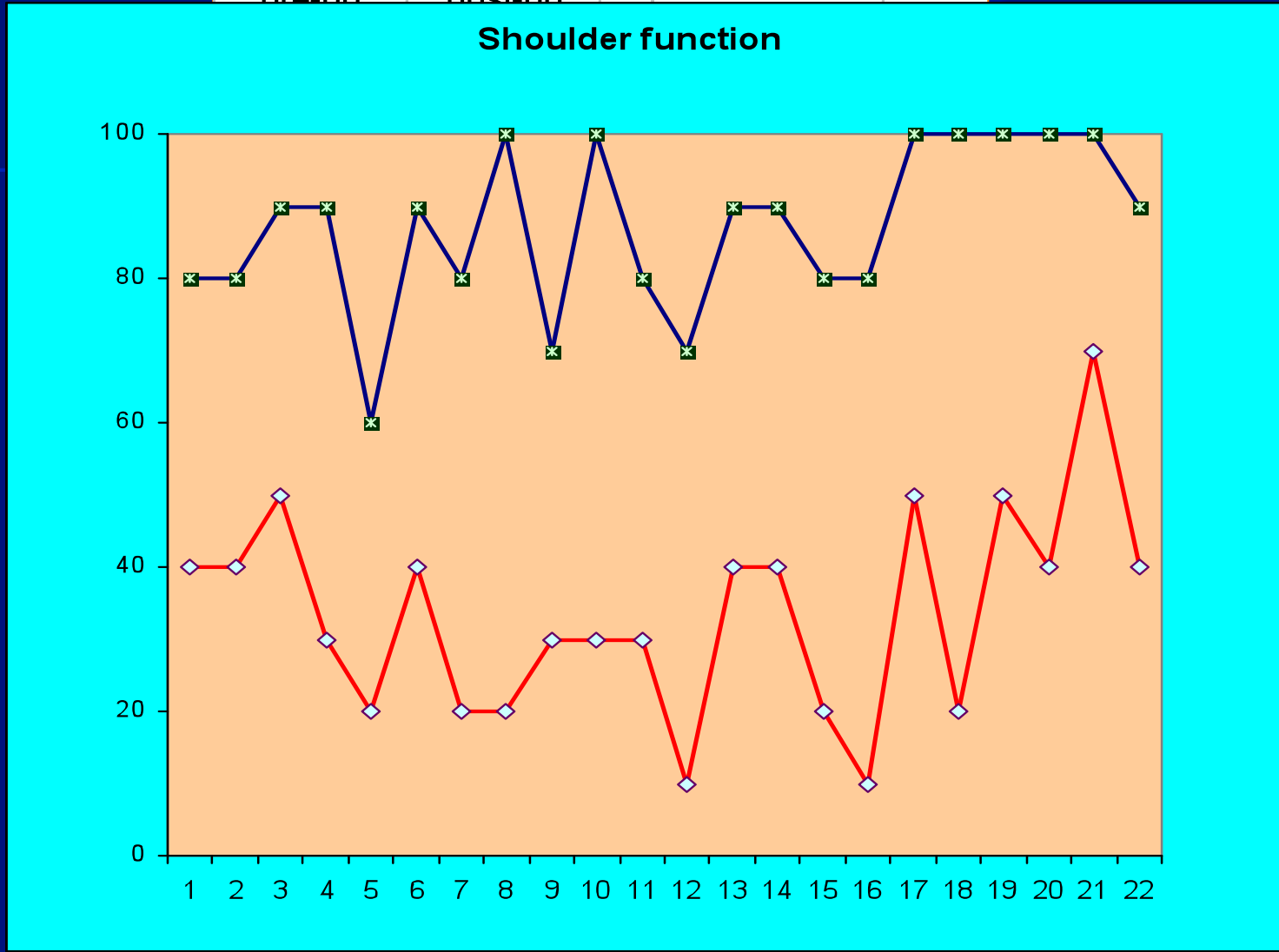
ADL	pre-op	post-op
reach opposite shoulder	3,6	8,9
hair toilet	3,3	9,2
overhead position	2,1	9,2
sleep	4,1	8,6
lift	2,5	9
reach back pocket	3,4	9,1
tuck shirt	3,3	9,1
reach mid back	1,7	7,9
put on jacket	3,5	8,9
work activities	4,2	8,9
leisure activities	3	8,4
AVERAGE	3,1	8,8

Arthroscopic ACJ Arthroplasty

ADL



shoulder function		satisfaction	
pre-op	post-op		




40	90	100	
----	----	-----	--

Arthroscopic ACJ Arthroplasty




The image cannot be displayed. Your computer may not have enough memory to open the image, or the image may have been corrupted. Restart your computer, and then open the file again. If the red x still appears, you may have to delete the image and then insert it again.




Advantages of Arthroscopic ACJ Excision

- ✓ less soft tissue trauma
- ✓ less pain
- ✓ improved cosmesis
- ✓ concurrent exam of the glenohumeral joint and subacromial bursa

 The image cannot be displayed. Your computer may not have enough memory to open the image, or the image may have been corrupted. Restart your computer, and then open the file again. If the red x still appears, you may have to delete the image and then insert it again.


Disadvantages of Arthroscopic ACJ Excision

- ✓ technically more demanding
- ✓ equipment dependent
- ✓ steep learning curve

 The image cannot be displayed. Your computer may not have enough memory to open the image, or the image may have been corrupted. Restart your computer, and then open the file again. If the red x still appears, you may have to delete the image and then insert it again.

Conclusion

In appropriately selected patients ACJ excision provides favorable functional results combining limited morbidity and minimal complications

 The image cannot be displayed. Your computer may not have enough memory to open the image, or the image may have been corrupted. Restart your computer, and then open the file again. If the red x still appears, you may have to delete the image and then insert it again.



Thank You