

# Παθήσεις του Ώμου

## Διάγνωση και Αντιμετώπιση

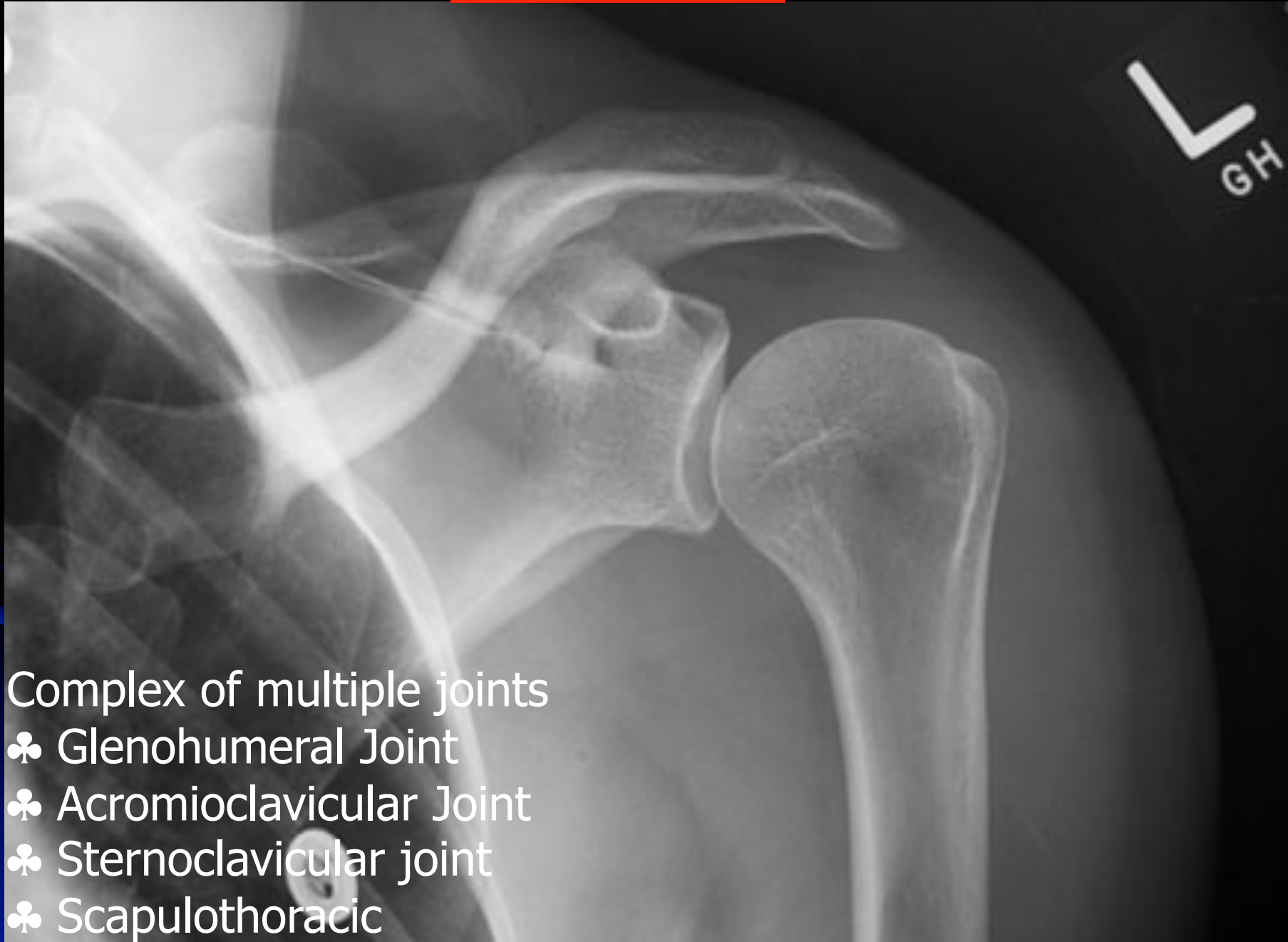Δρ. Χρήστος Κ. Γιαννακόπουλος

Ορθοπαιδικός Χειρουργός

Κέντρο Αρθροσκοπικής Χειρουργικής και  
Χειρουργικής Ώμου

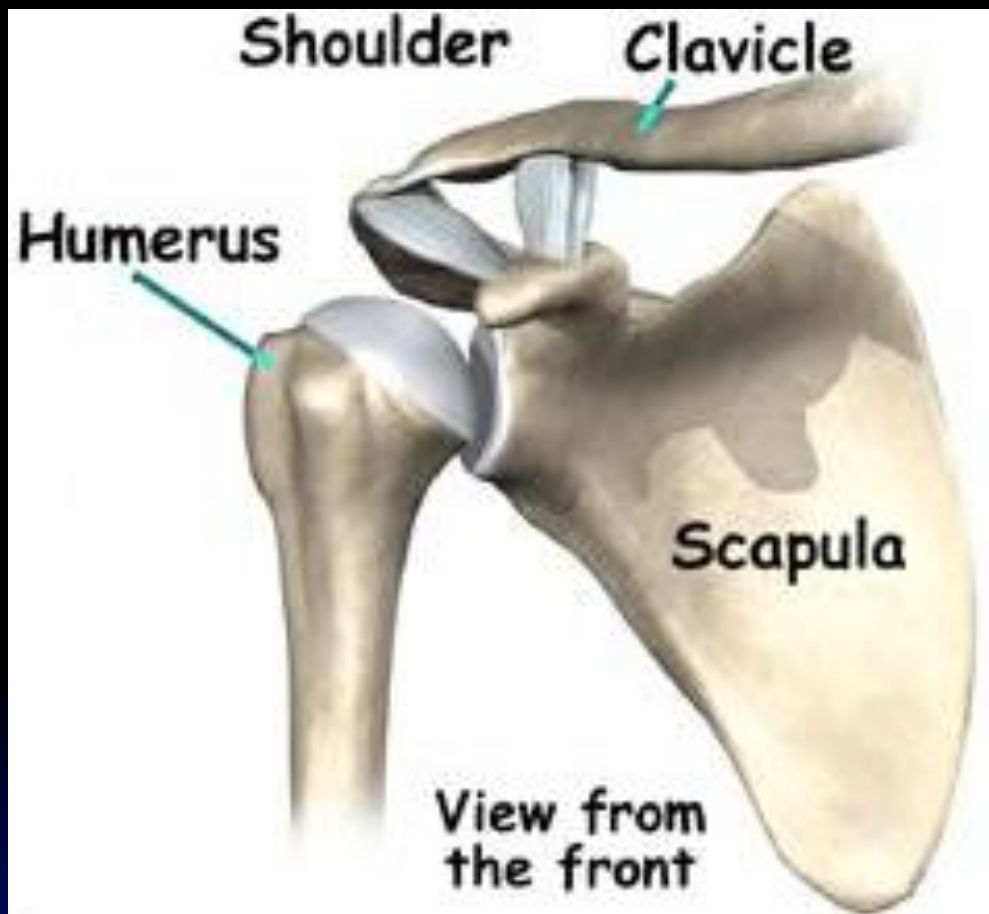
Νοσοκομείο ΙΑΣΩ General, Αθήνα

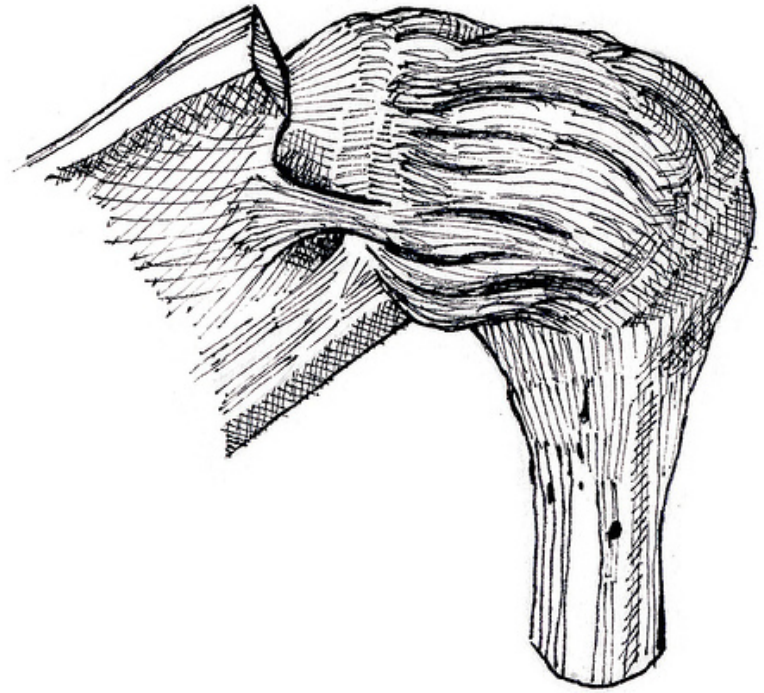
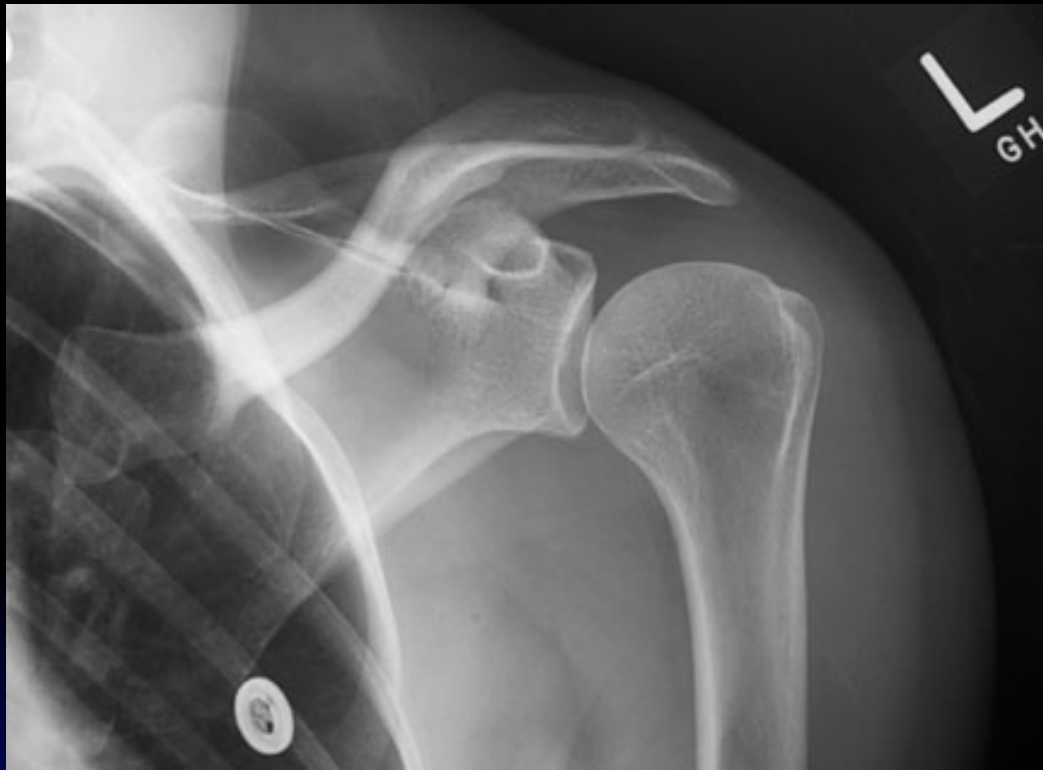# Όμος



Complex of multiple joints


- ♣ Glenohumeral Joint
- ♣ Acromioclavicular Joint
- ♣ Sternoclavicular joint
- ♣ Scapulothoracic






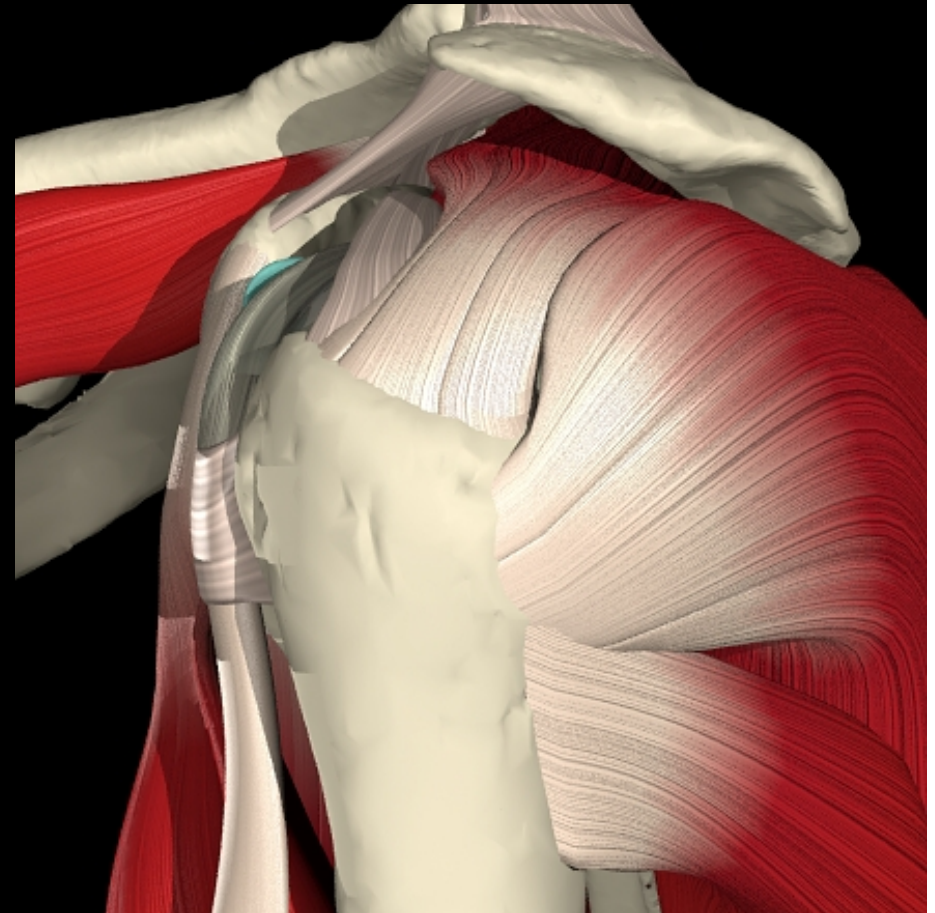
CAPSULE OF THE SHOULDER JOINT

# 18 muscles involved in shoulder girdle motion



# Rotator Cuff Muscles


- Stabilizers of the GH joint
- Known by the acronym S.I.T.S.
  - Supraspinatus
  - Infraspinatus
  - Teres Minor
  - Subscapularis



## Principles of Physical Examination

- General “picture” of the patient
- Inspection (muscle wasting, deformity, surgical scars)
- Palpation of known anatomical sites
- Range of motion (active & passive) with careful documentation
- Strength testing
- Neurological examination
- Stability and laxity measurements
- Special Tests

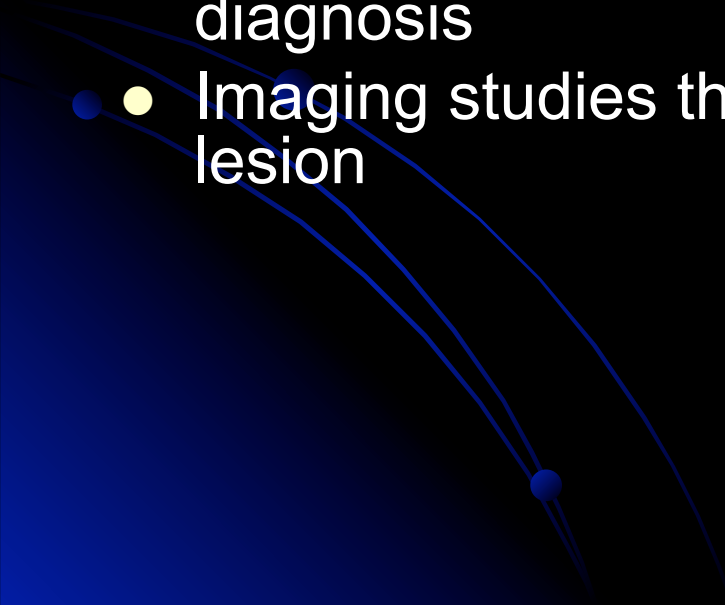
INSPECT  
PALPATE  
MOVE





# PROGRESS IN DIFFERENTIAL DIAGNOSIS

## DEFINE CHIEF COMPLAINT

- Ask history questions that will narrow the differential
  - Perform clinical examination tests that will establish the diagnosis
  - Imaging studies that will demonstrate the anatomic lesion
- 

# Chief complaint: Pain

## CAUSES

- Impingement
  - classic outlet impingement
  - internal impingement
  - subcoracoid impingement
- Rotator cuff
  - tendinosis
  - partial thickness tear
  - full thickness tear
- Instability
  - anterior
  - posterior
  - multidirectional MDI
- AC joint pathology
- Biceps and labral pathology
- Chondral defects Arthritis
- Neurologic
  - cervical spine root compression
  - brachial neuritis
  - thoracic outlet syndrom
  - suprascapular nerve entrapment

# Chief complaint: Pain

## LOCATION

**Whole hand over deltoid in rubbing motion**

Impingement /rot cuff

**Greater tuberosity**

Impingement /rot cuff

**One finger on top of distal clavicle**

AC joint

**In the back when the arm is in the throwing position**

Internal impingement/ posterior SLAP

**Down the neck and scapula medial border**

Neck pathology

**In front within deltopectoral groove**

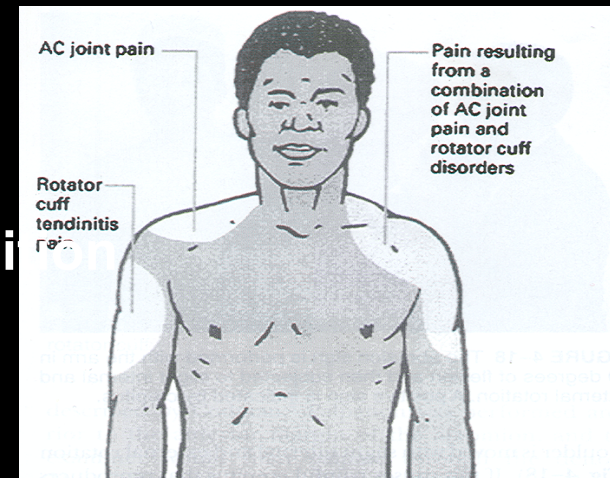
Biceps tendon/subscapularis

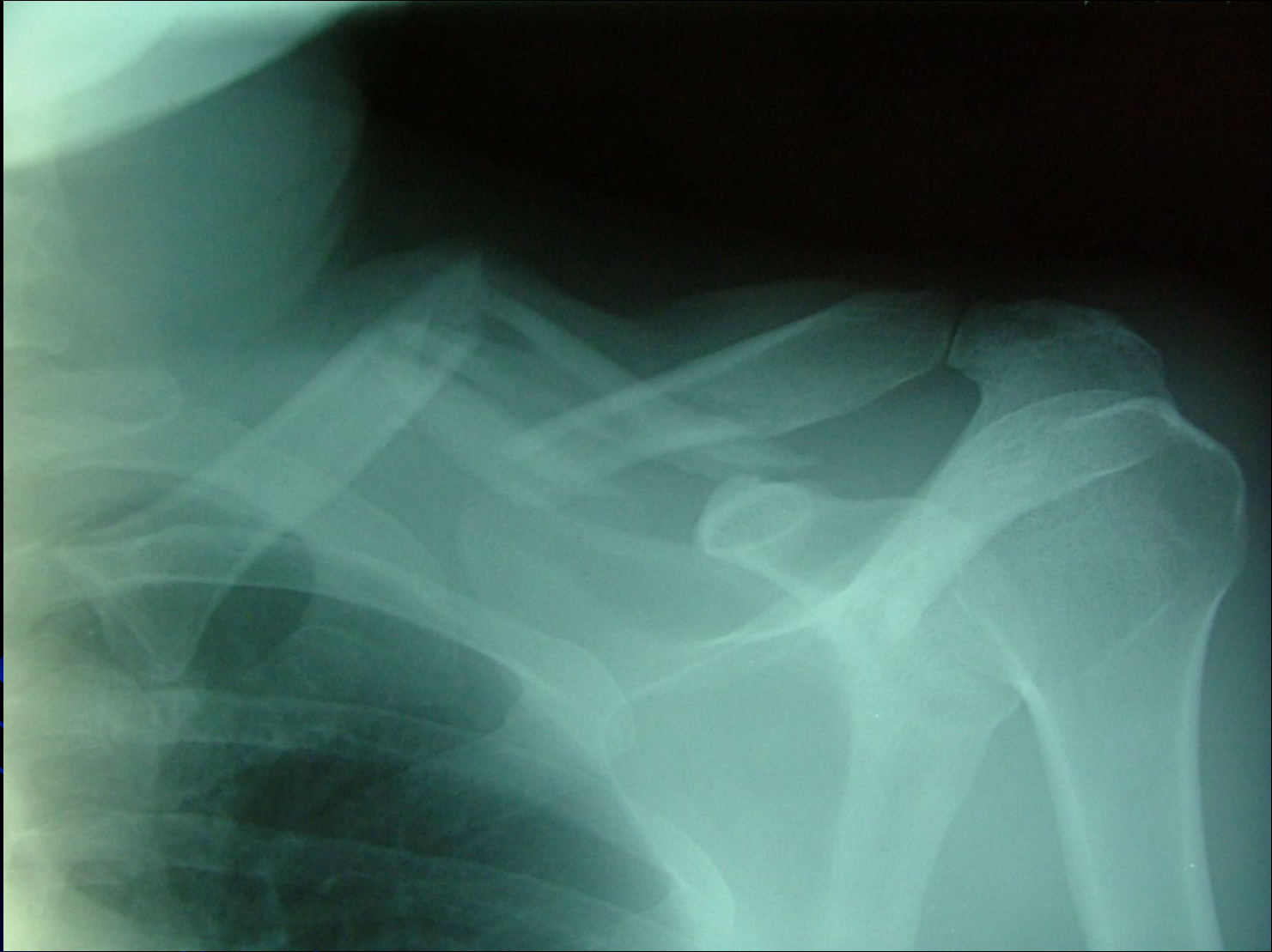
**Deep inside**

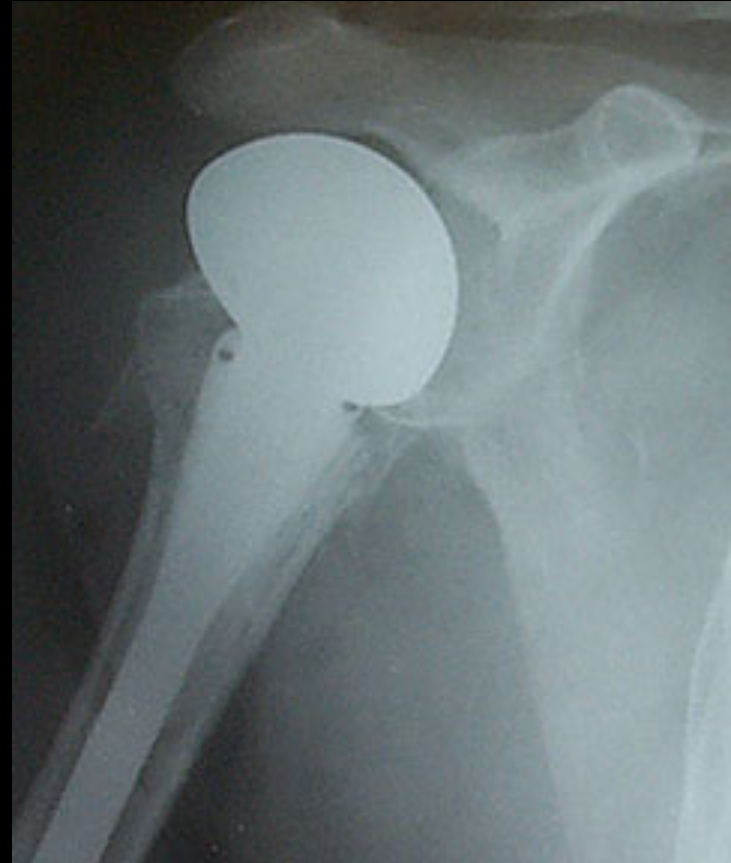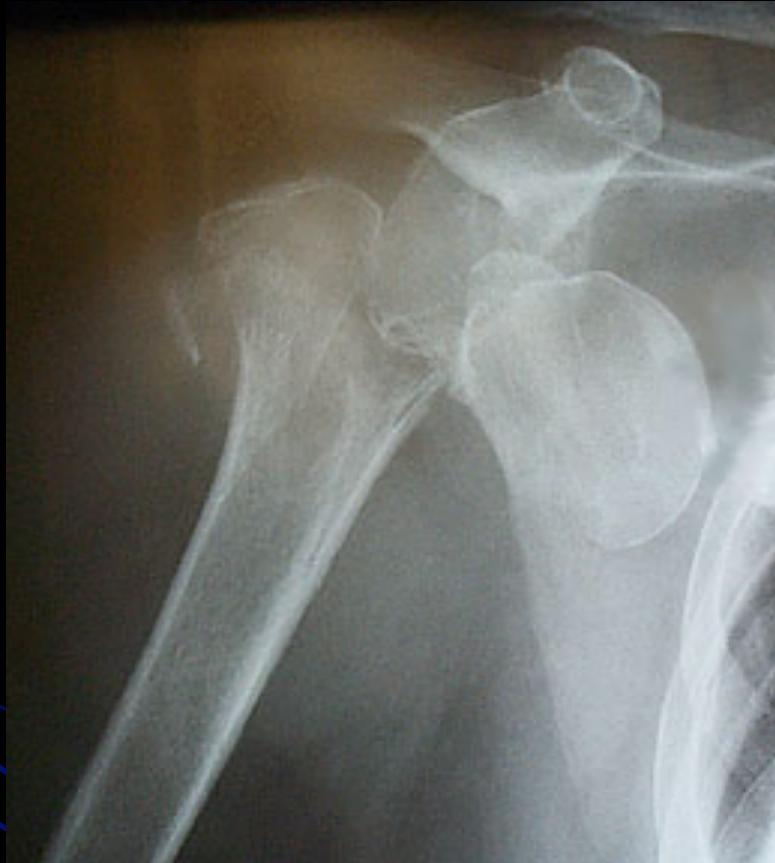Labral or articular cartilage lesion

**Vague and diffuse down arm**

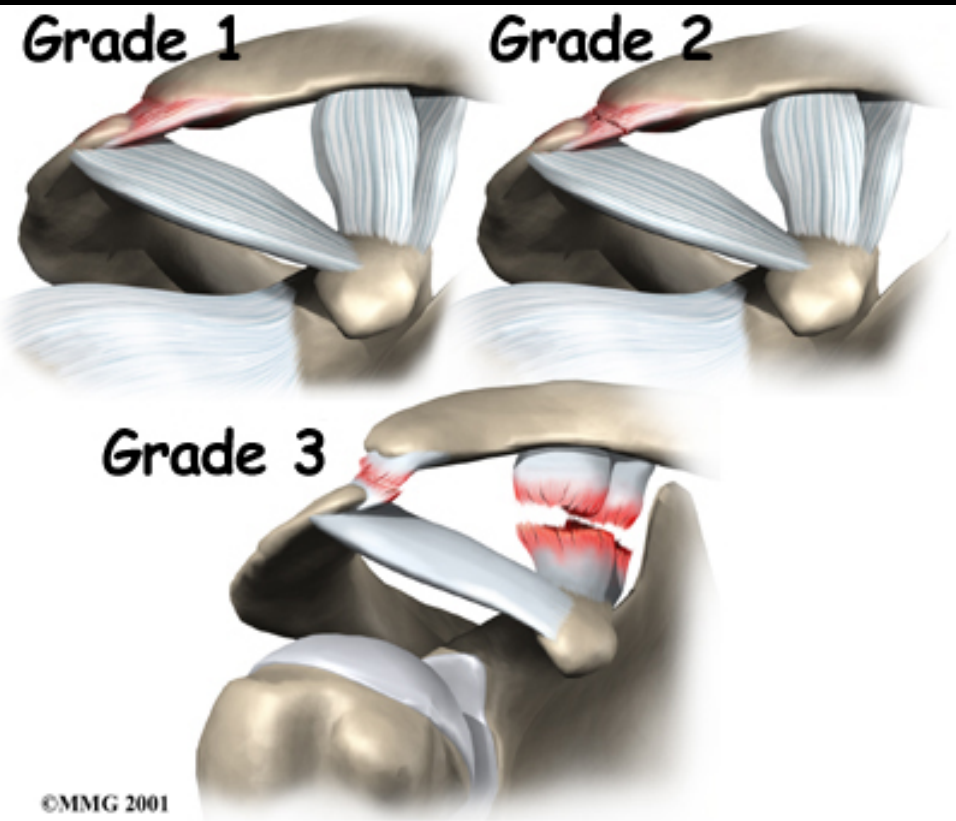
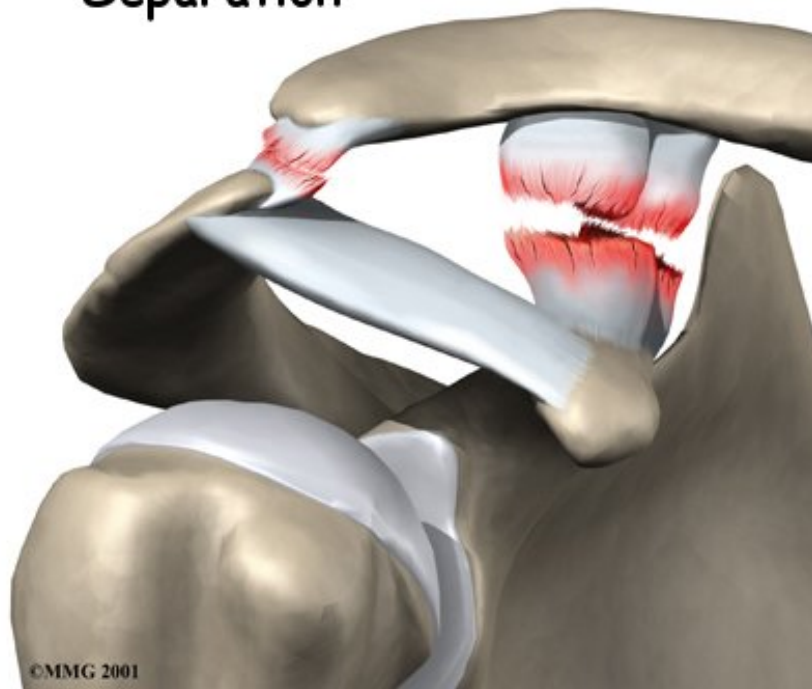Brachial neuritis /thoracic outlet




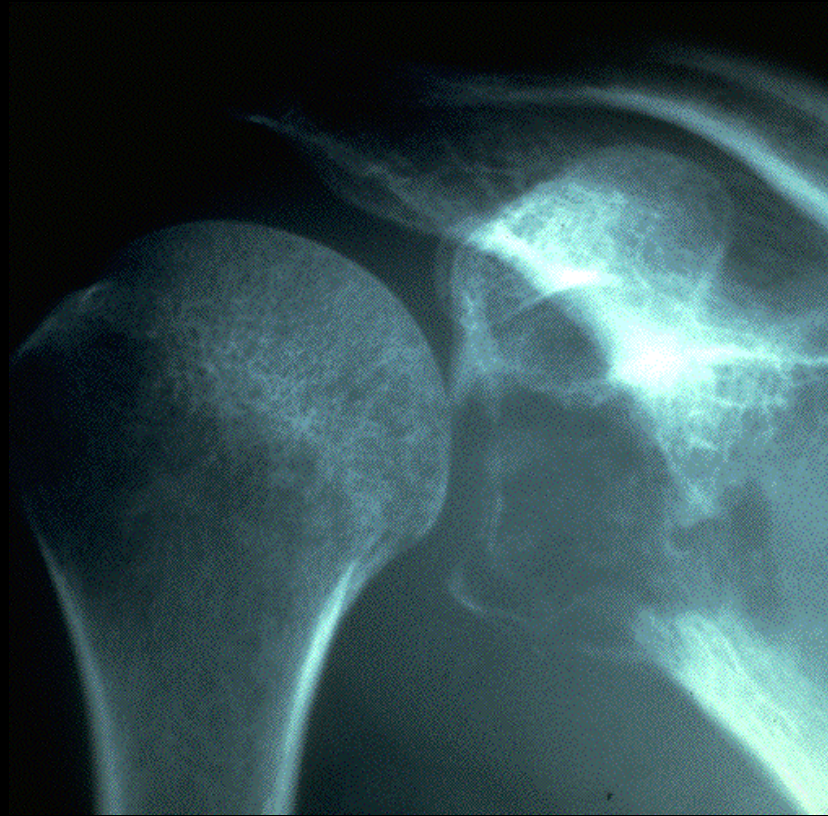



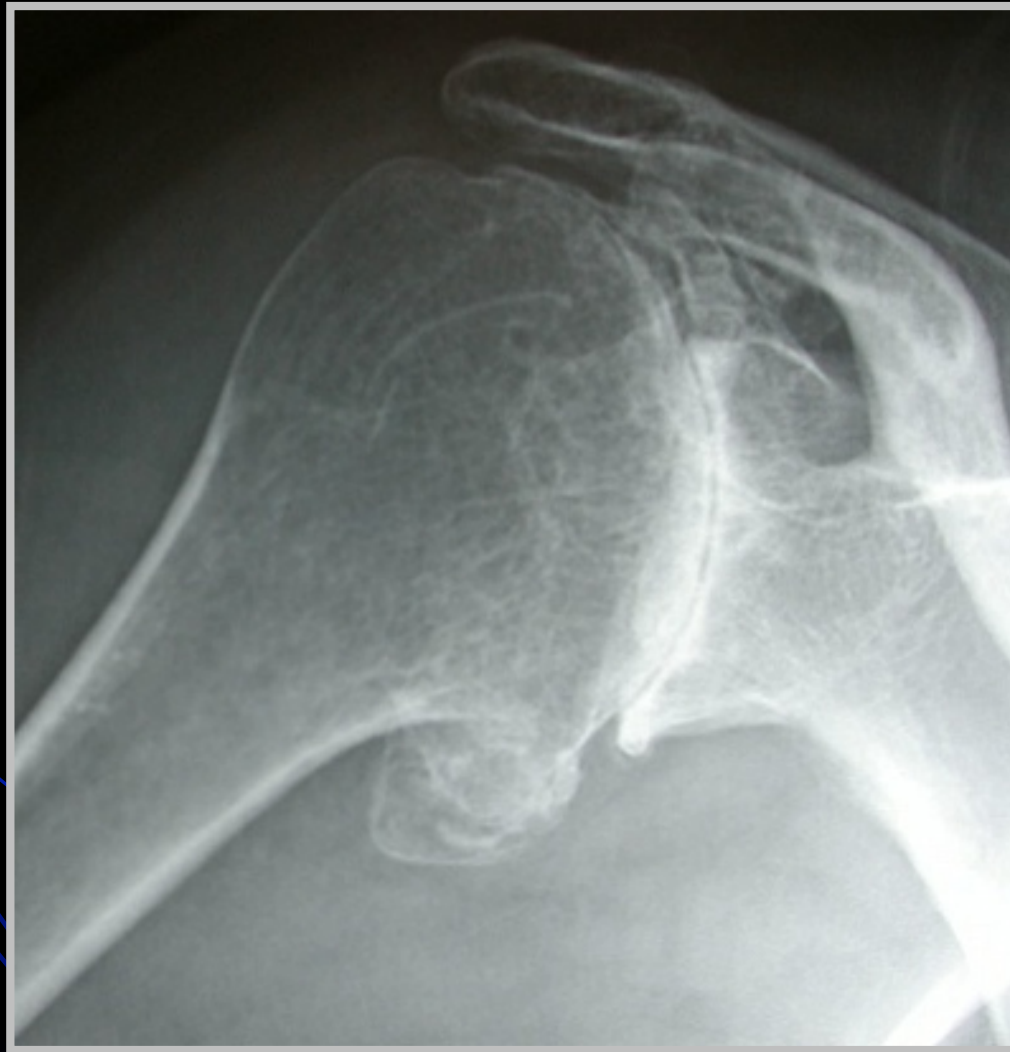
## Acromioclavicular Separation



# Tumor



# Glenohumeral OA





# Πόνος στον Ώμο



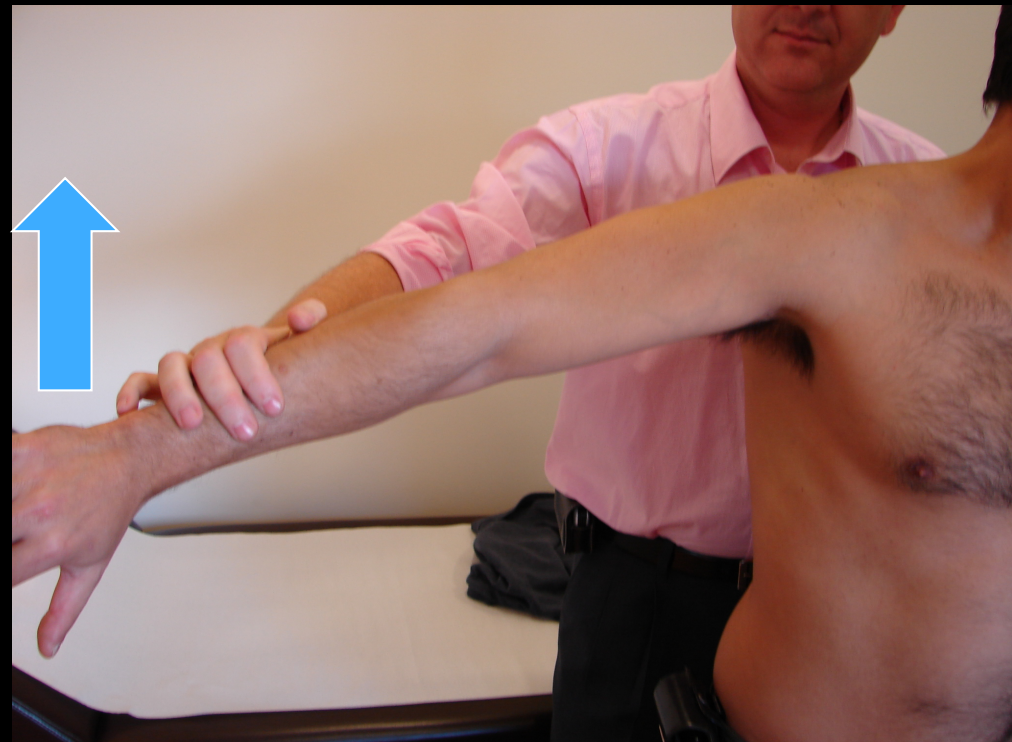- Σύνδρομο πρόσκρουσης
- Ρήξη τενοντίου πετάλου
- Εξάρθρωμα ώμου
- Ασβεστοποιός τενοντίτιδα
- Αρθρίτιδα ΑΚΑ-ΓΒΑ

# Chief complaint: Pain

## Provocative Tests

Tests for  
Weakness

Jobe's Test

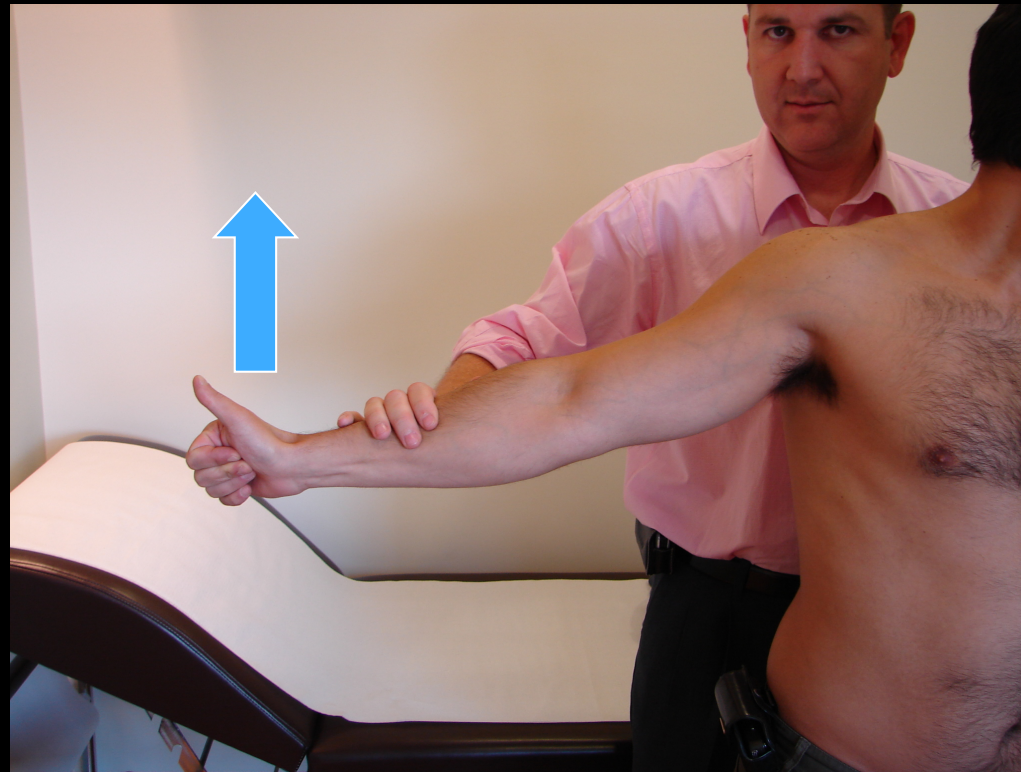


# Chief complaint: Pain

## Provocative Tests

Tests for  
Weakness

Full Can Test

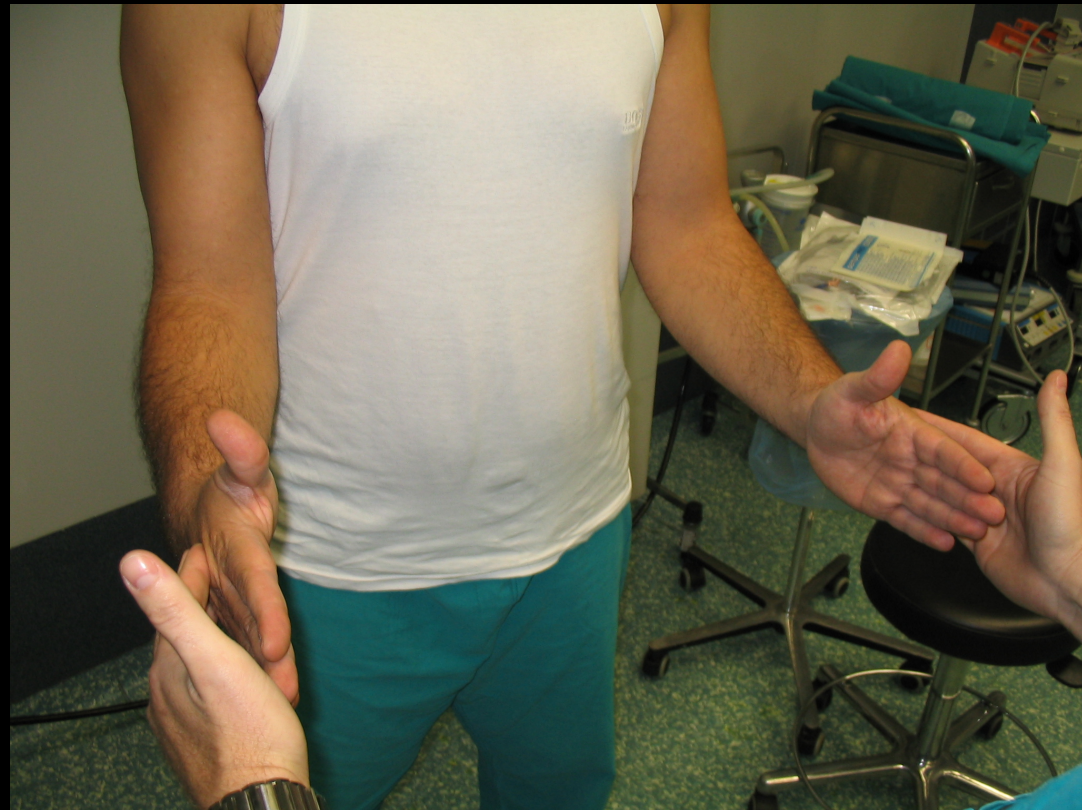

# Chief complaint: Pain

## Provocative Tests

Tests for Weakness

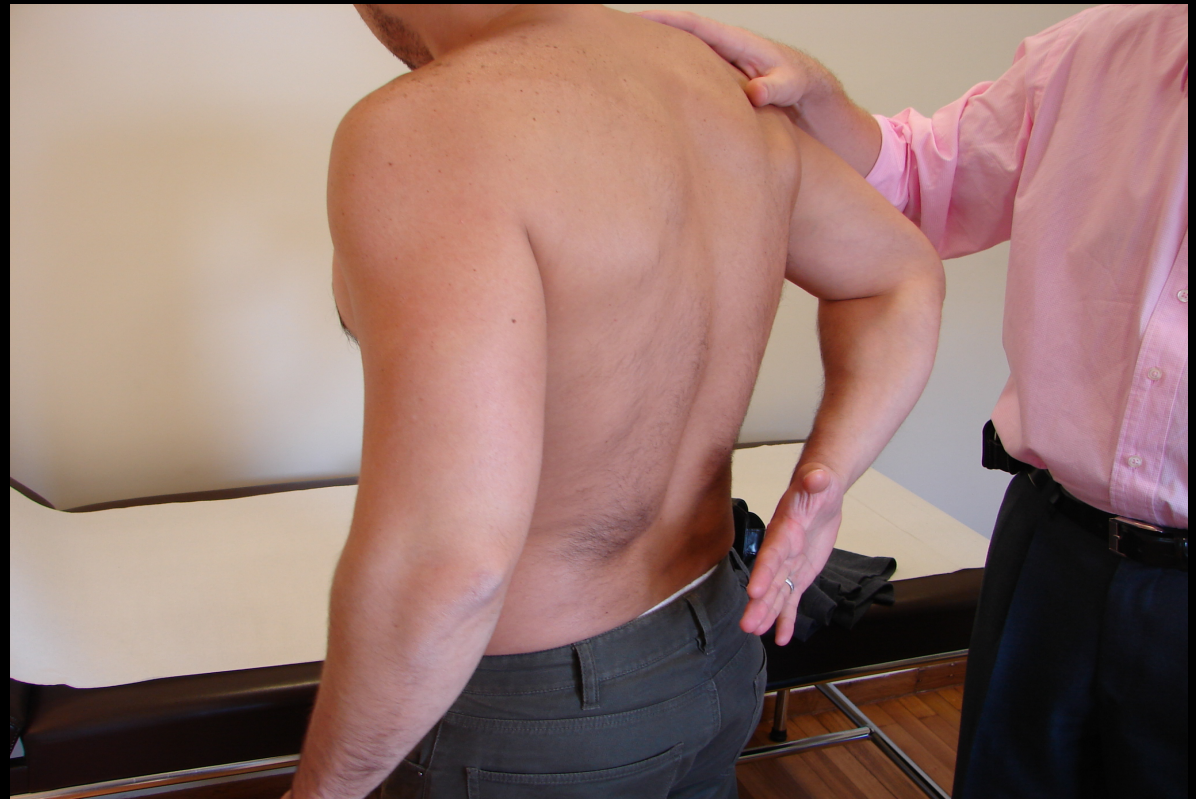**Resisted External  
Rotation**



# Chief complaint: Pain Provocative Tests

Tests for Weakness

**Lift-Off Test**

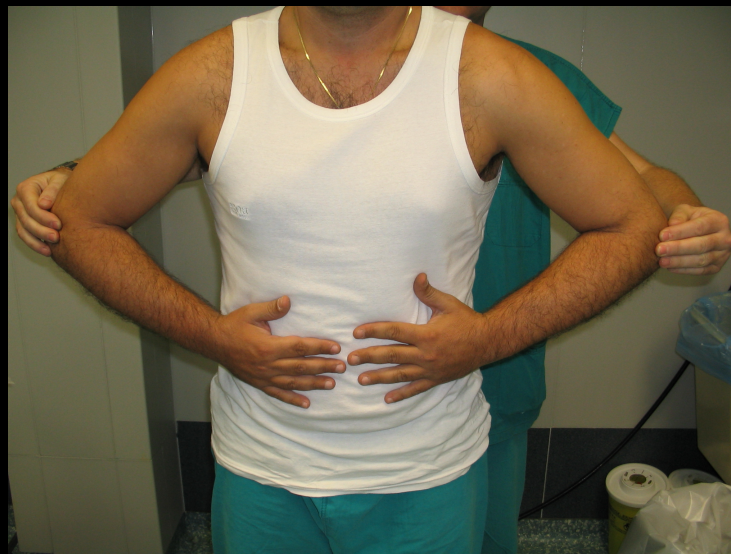
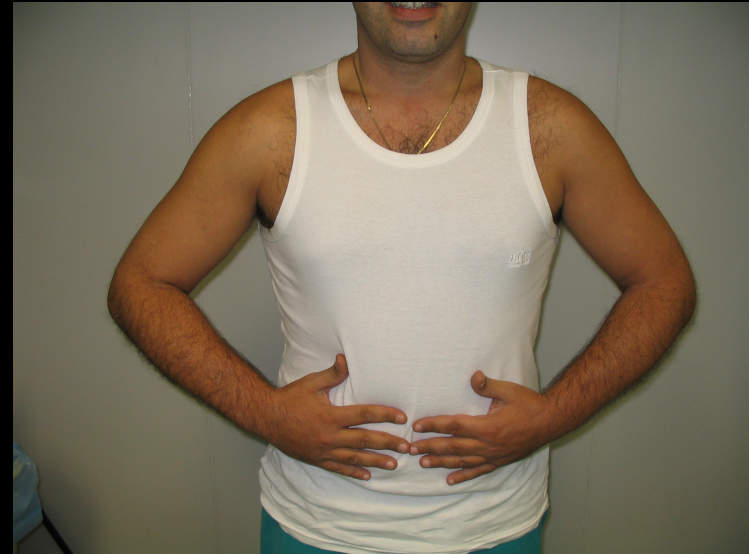

# Chief complaint: Pain

## Provocative Tests

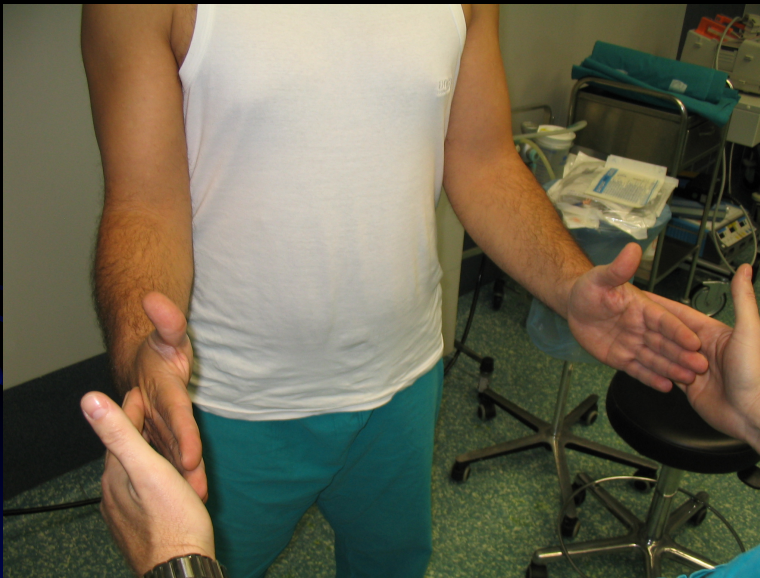Tests for Weakness

**Belly-press Test**

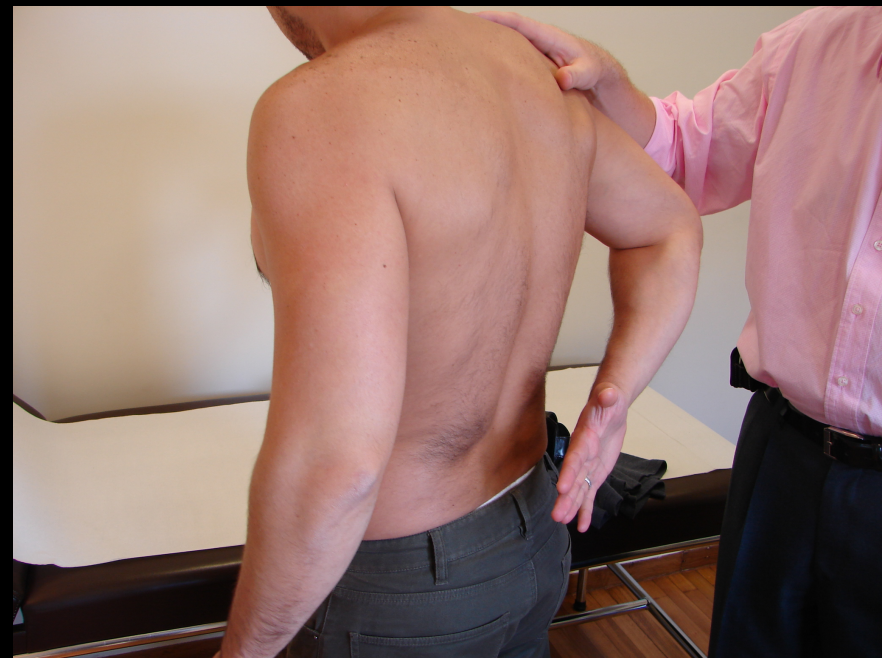

# Lag Signs

## Infraspinatus



## Subscapularis

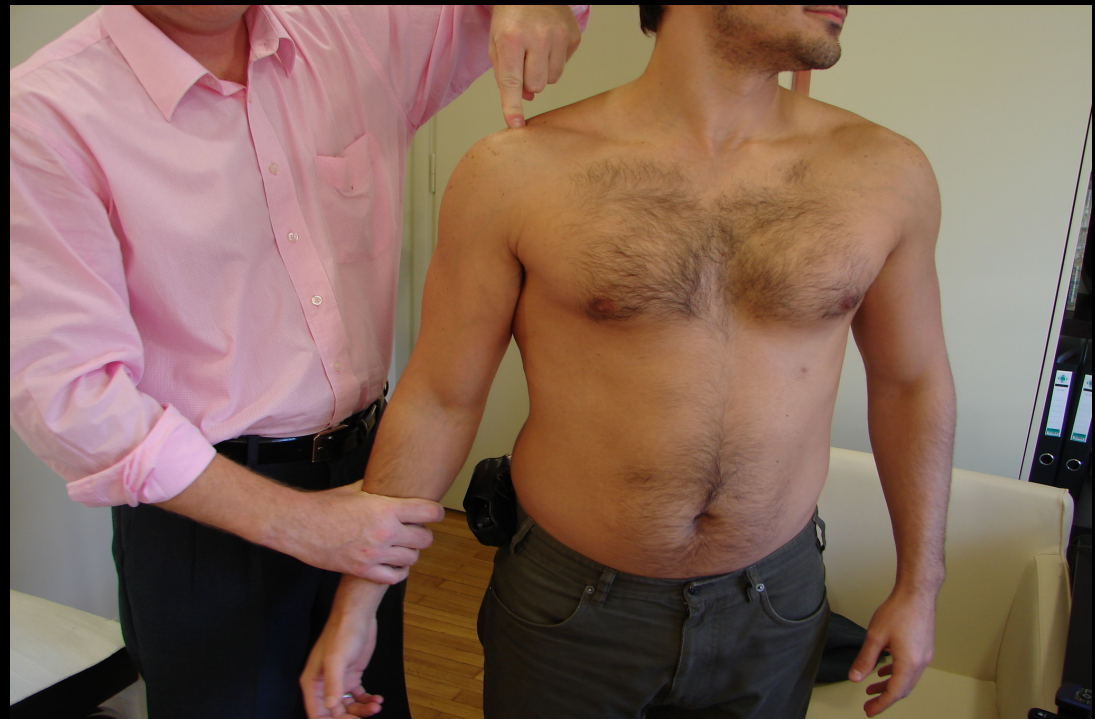

# Chief complaint: Pain

## Provocative Tests

### Acromioclavicular Joint Tests

#### One Finger Test





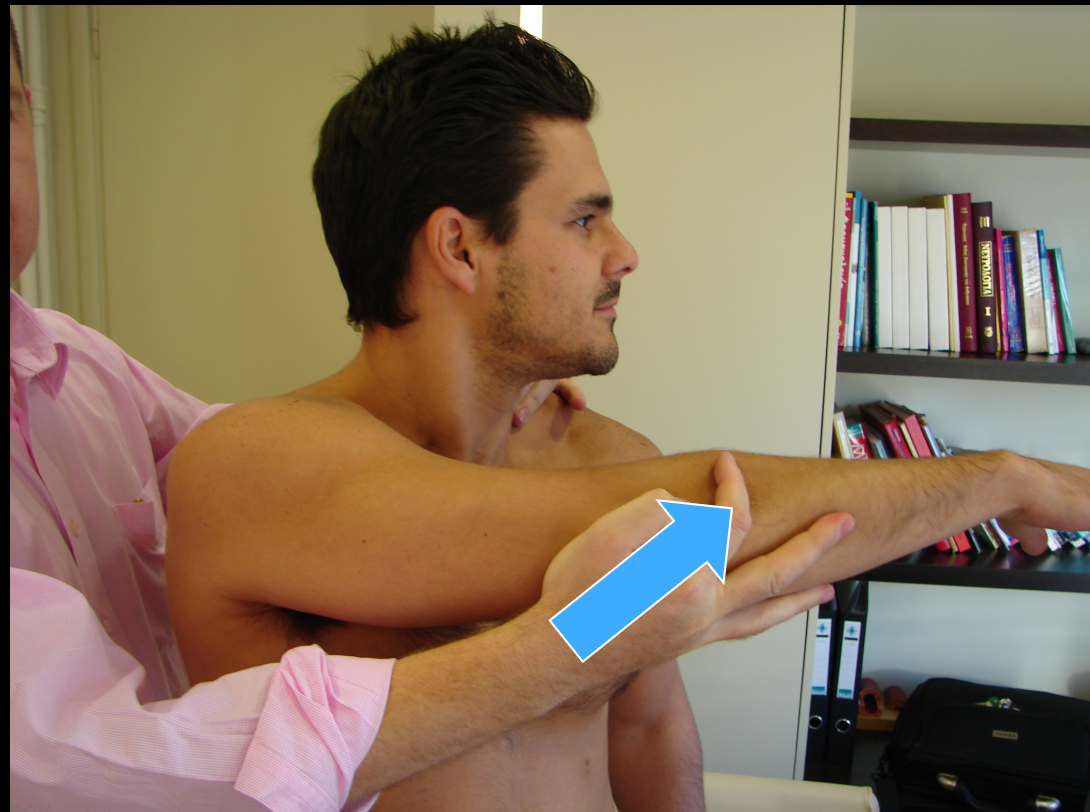# Chief complaint: Pain

## Provocative Tests

### Acromioclavicular Joint Tests

**AC Compression Test**

**Pain on top of the shoulder**

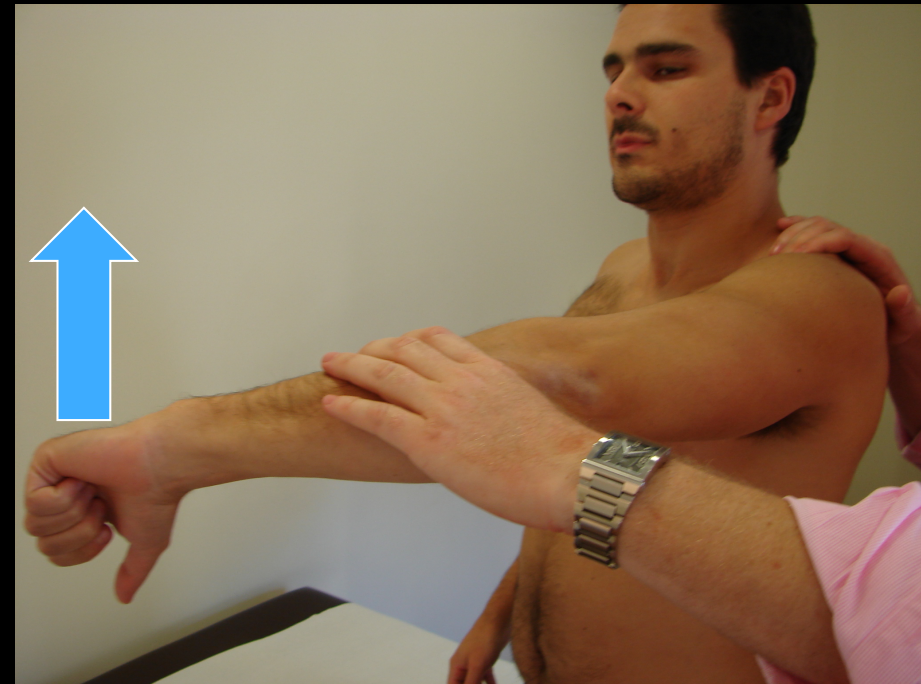

**Chief complaint: Pain  
on top of the shoulder  
Provocative Tests  
Acromioclavicular Joint Tests**

**Active  
Compression  
Test**

**(O'Brien's Test)**

**Pain on top of the  
shoulder**

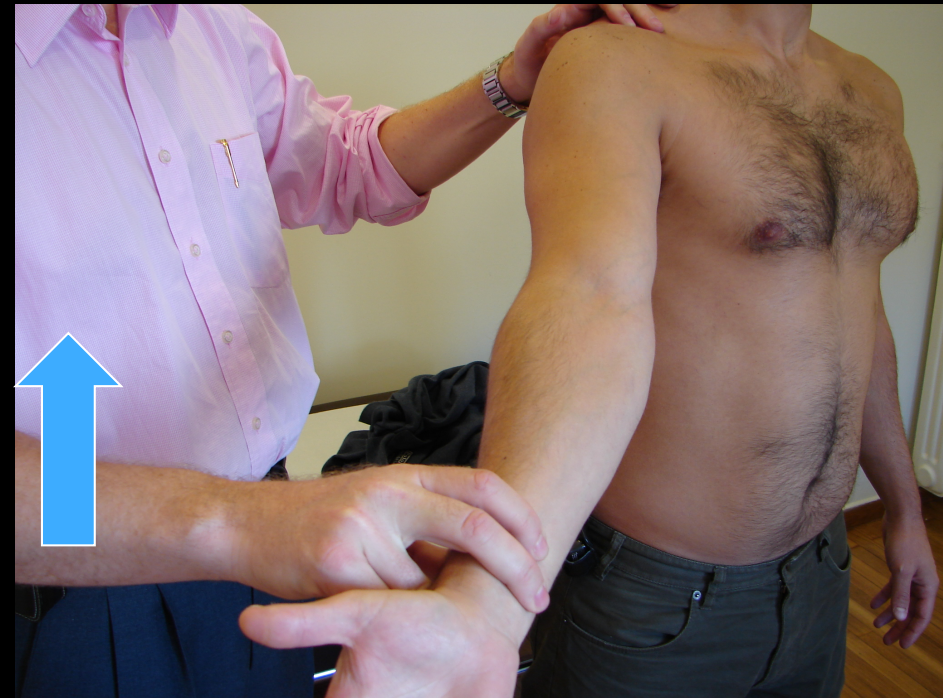

# Chief complaint: Pain in front of the shoulder

## Provocative Tests

Biceps  
Pathology

Speed's Test

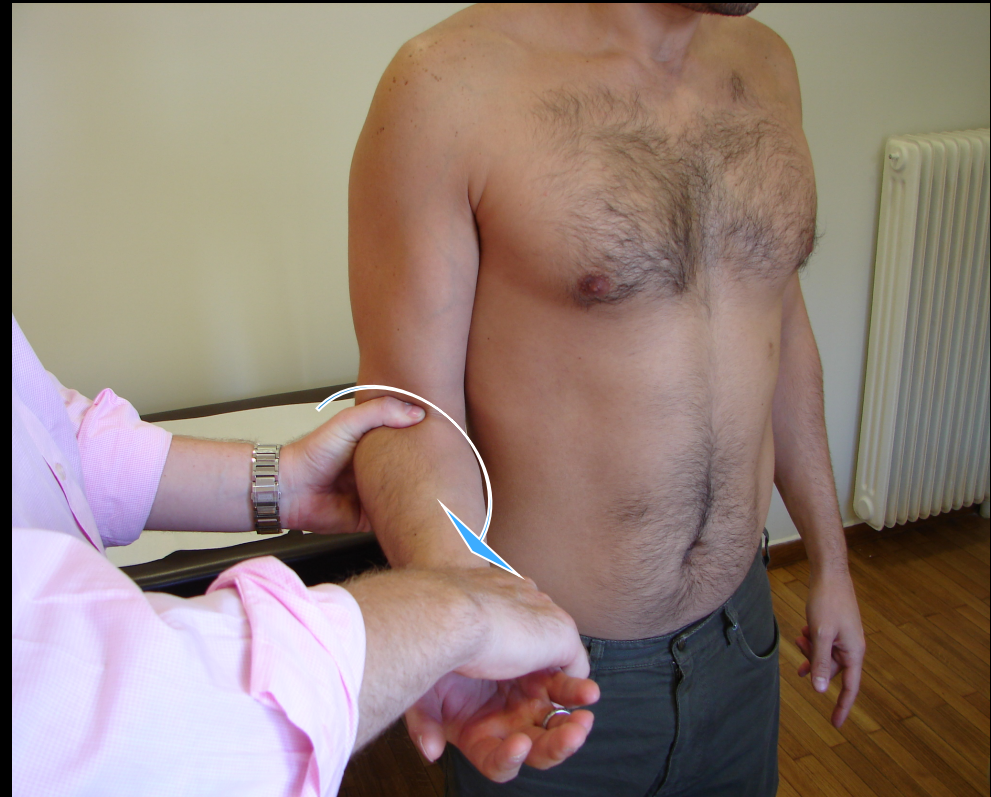


# Chief complaint: Pain in front of the shoulder

## Provocative Tests

Biceps Pathology

Yergason's Test



Chief complaint: Deep pain in the  
shoulder

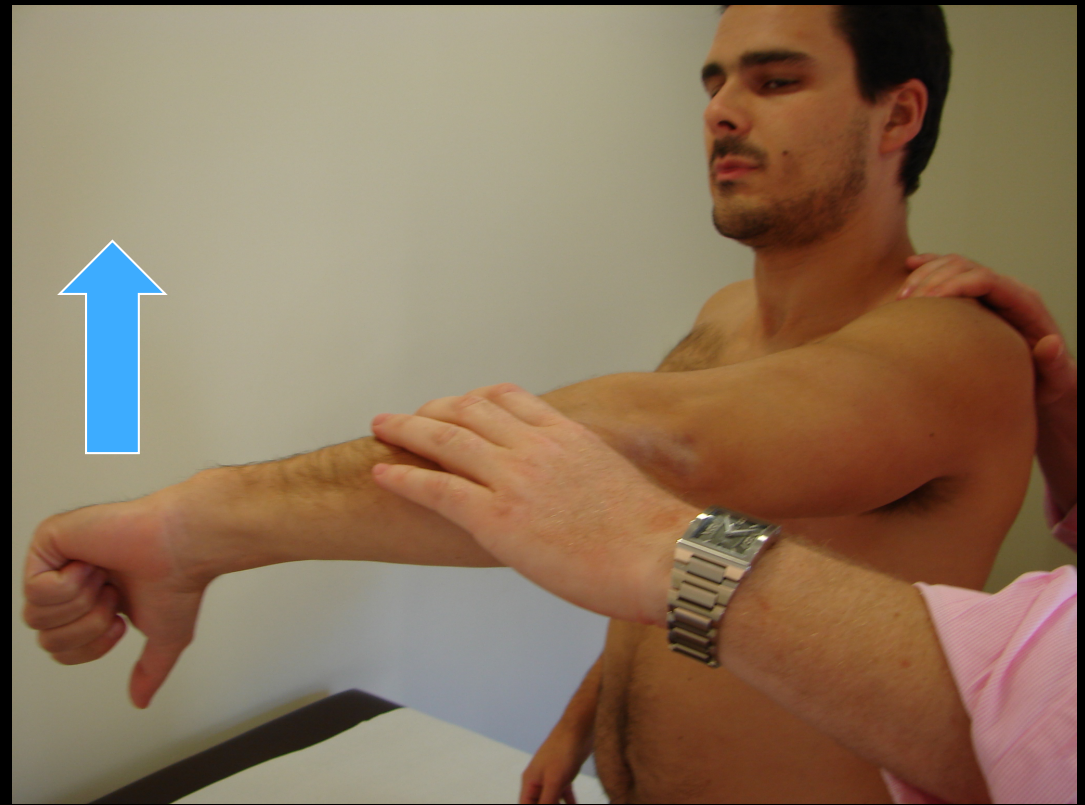## Provocative Tests

### Superior Labral Pathology

Active Compression  
Test

(O'Brien's Test)

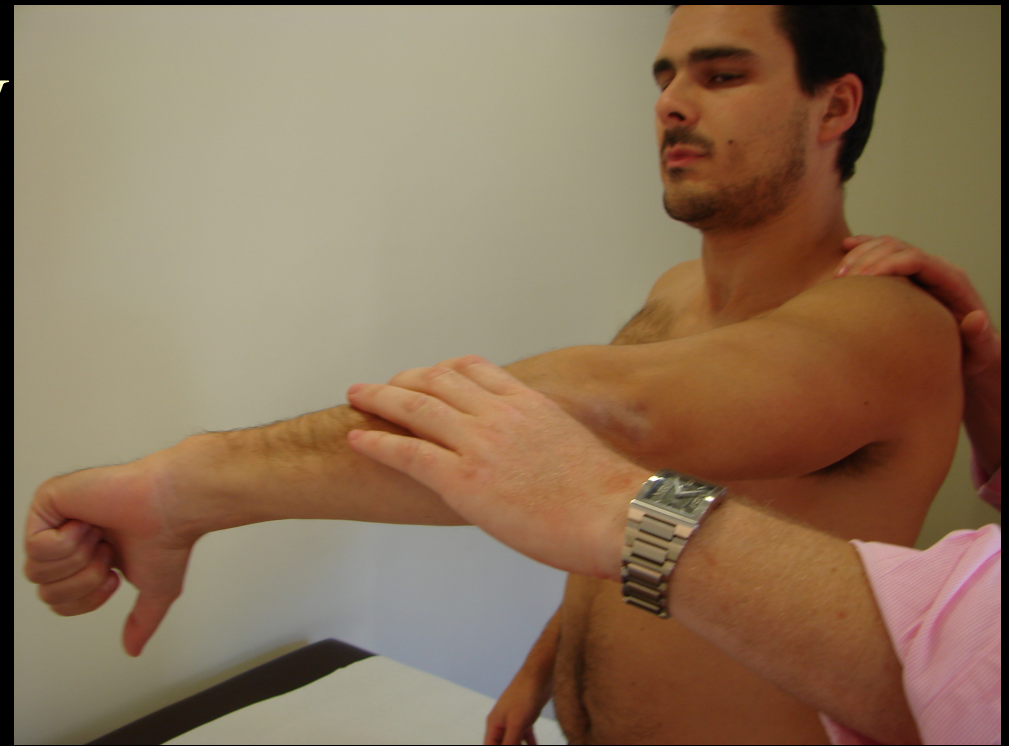95% sensitive but low  
specificity



# Chief complaint: Deep pain in the shoulder

## Provocative Tests

Superior Labral Pathology  
“SLAP”prehension test

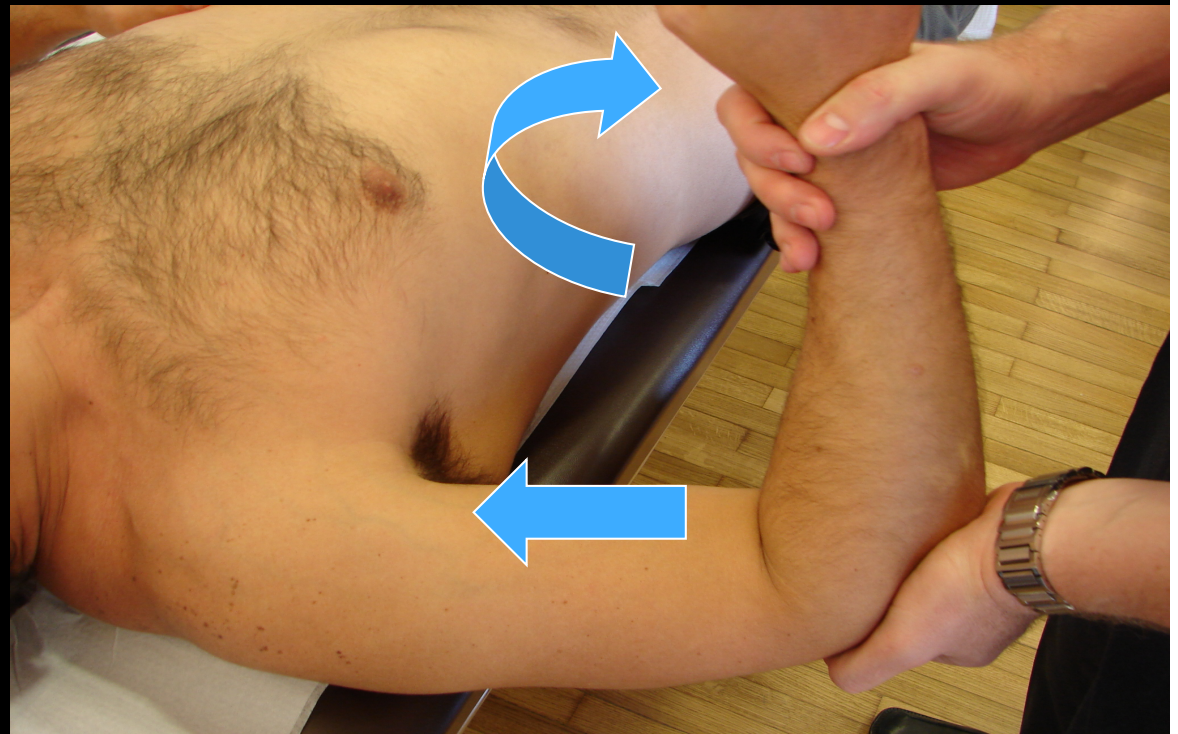


# Chief complaint: Pain deep in the shoulder

## Provocative Tests

Superior Labral Pathology

Compression  
Rotation  
Sign

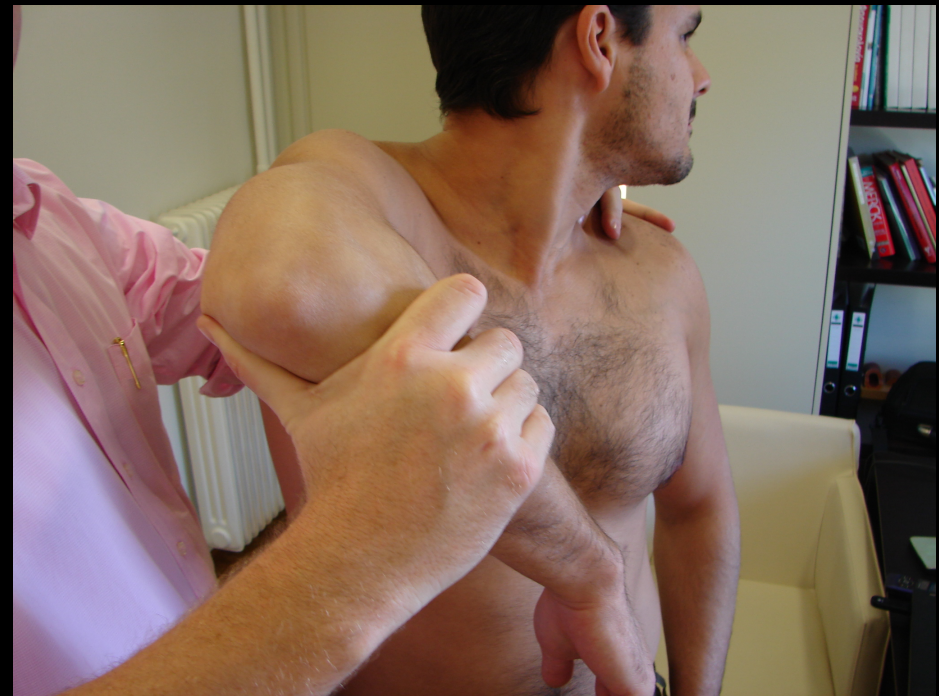

# Chief complaint. Pain at coracoid. Provocative tests

Coracoid impingement  
sign

Similar to the Hawkins  
test with

Less horizontal adduction

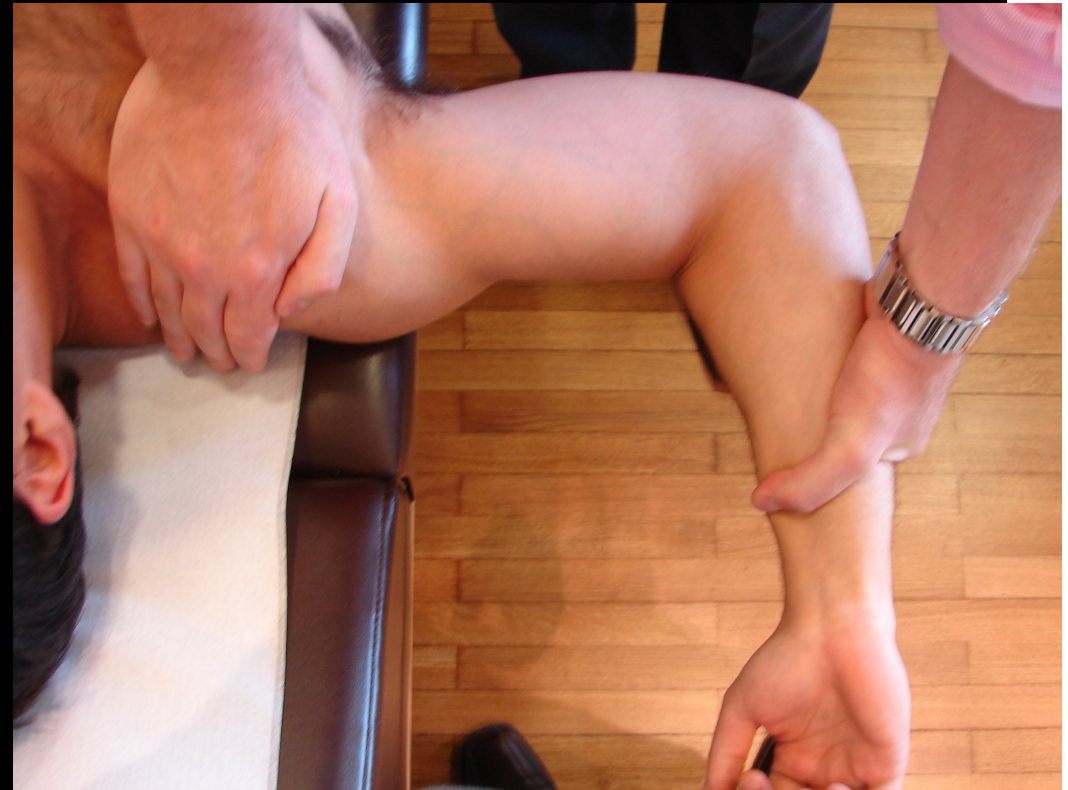



# Chief complaint pain secondary to instability

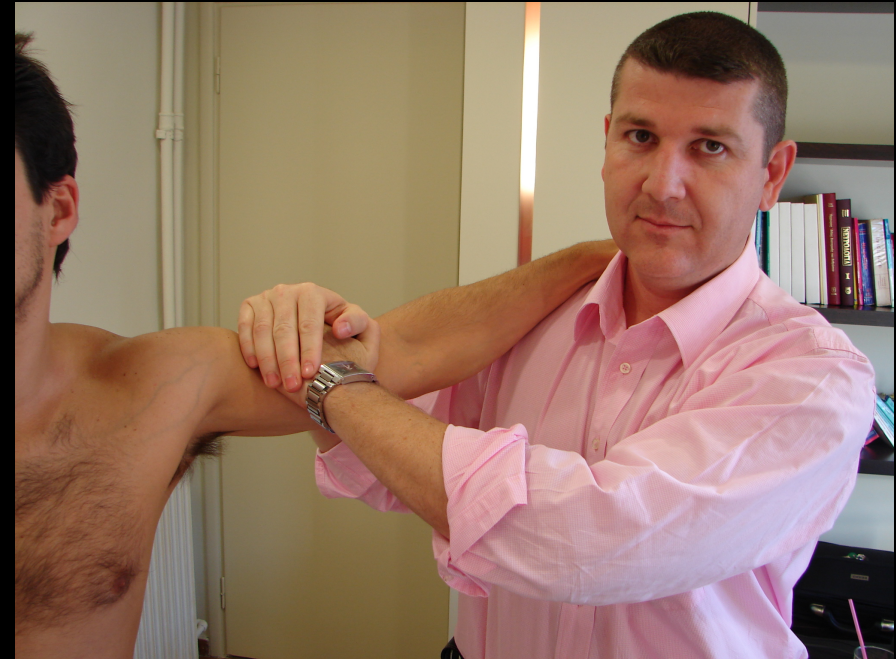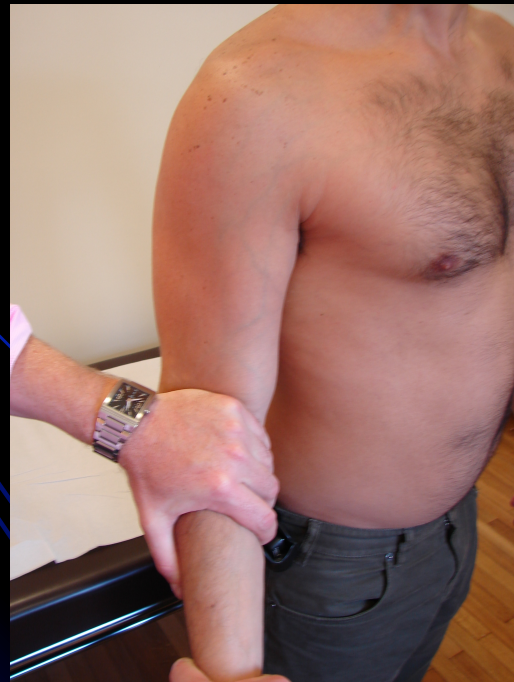Instability coexisting with internal impingement or SLAP tears can present as posterior pain with maximum abduction and external rotation

Relocation test positive

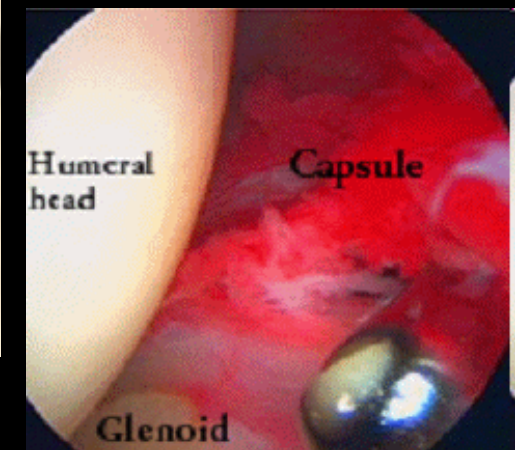
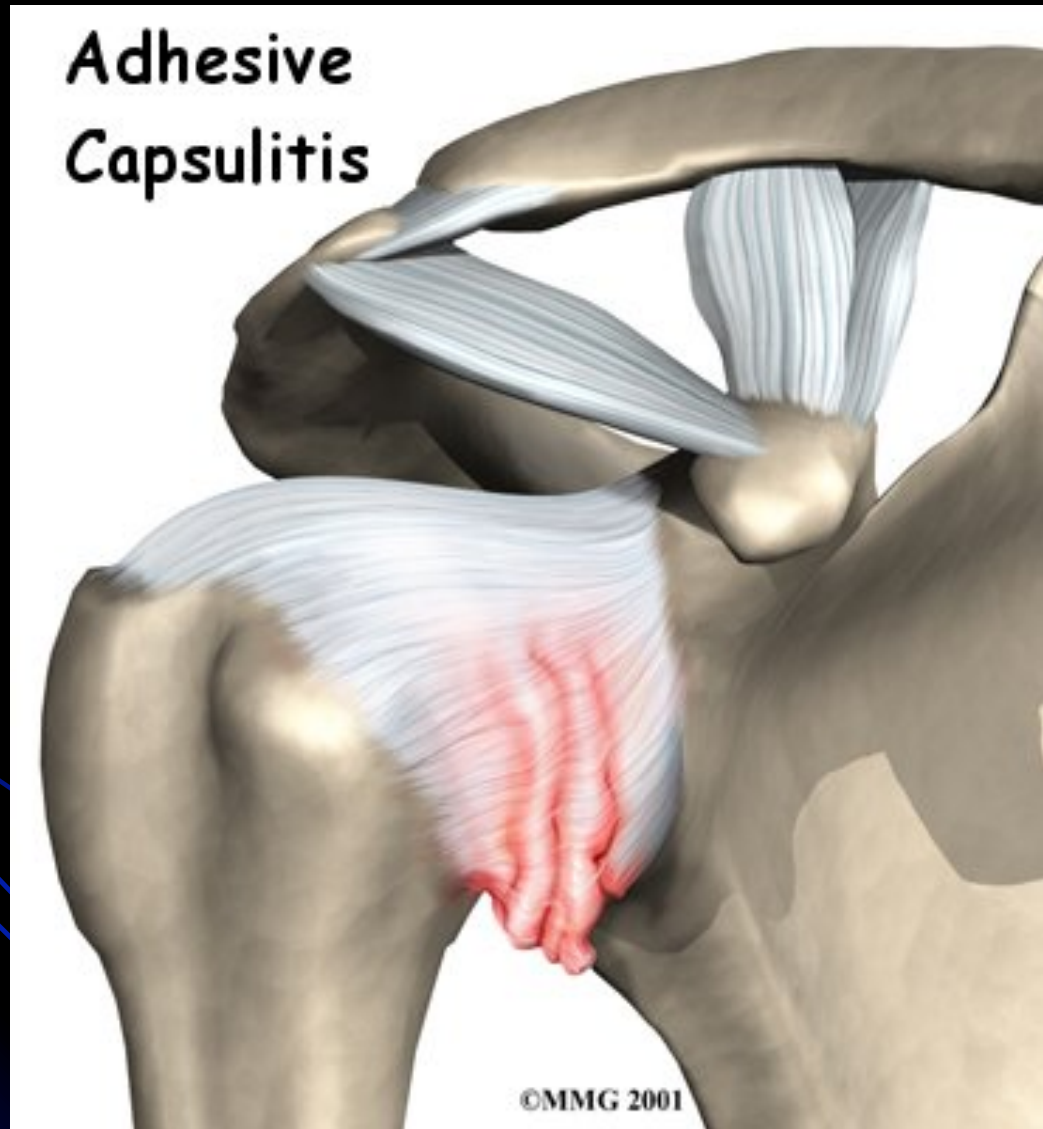


# Pain secondary to instability

- Inferior sulcus test for pain in adduction and 90 of abduction reproduces the pain



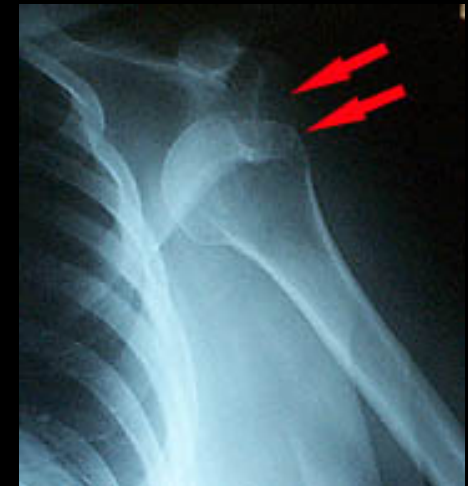# Παγωμένος Ώμος



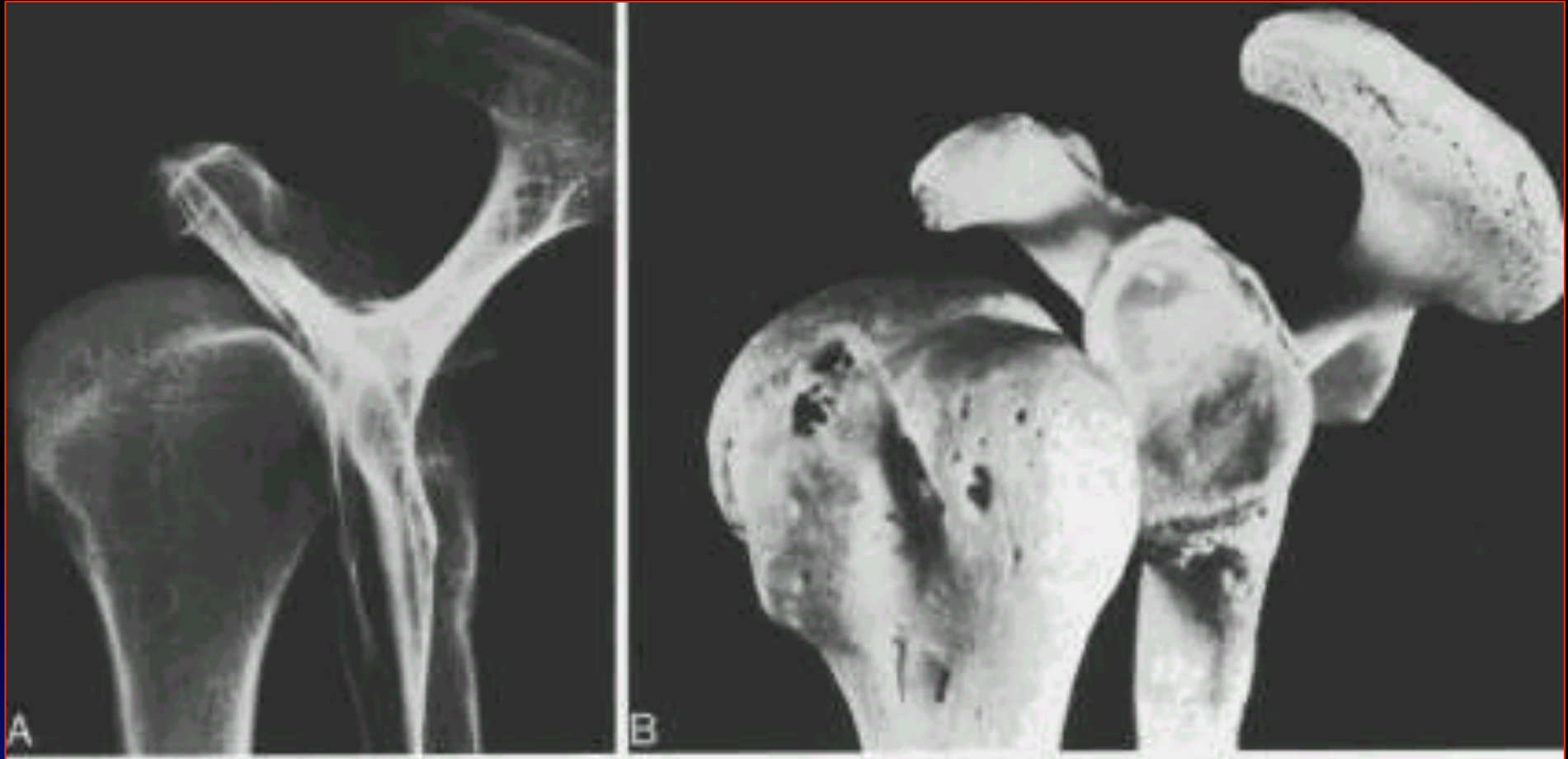# Εξάρθρωμα του Ώμου

2% του γενικού πληθυσμού

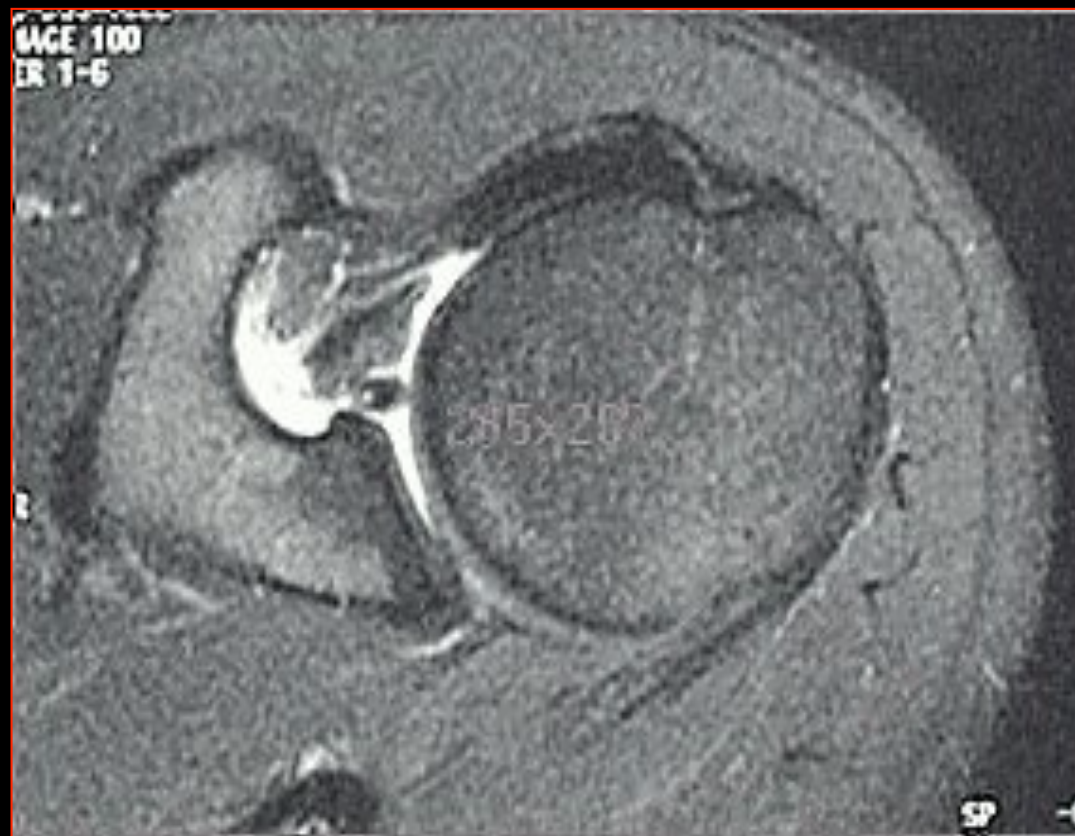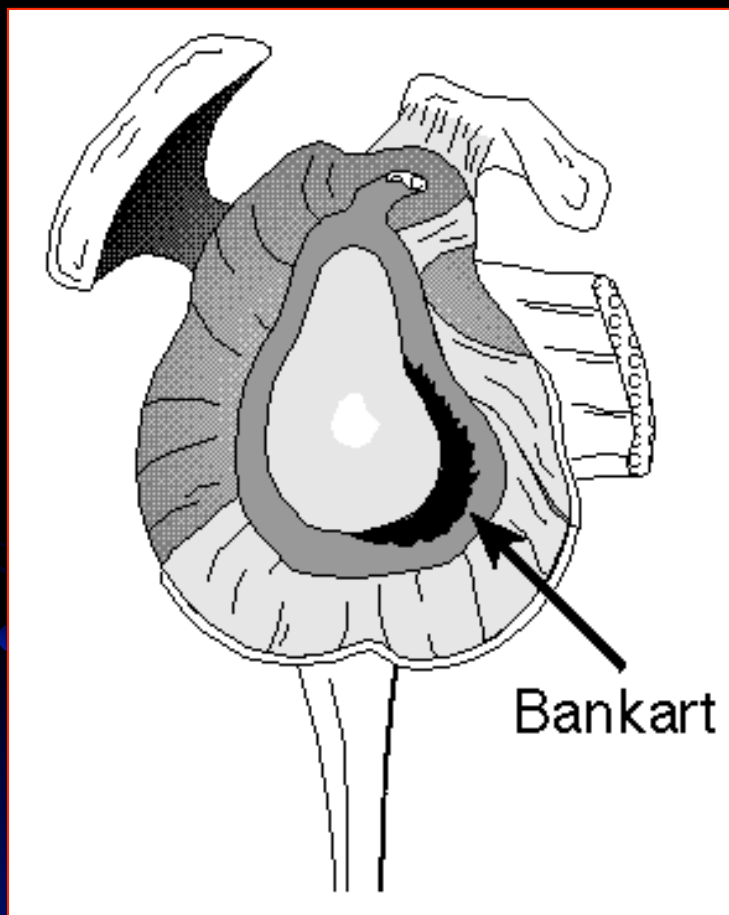
90% πρόσθιο



# Πρόσθιο Εξάρθρημα του Ώμου

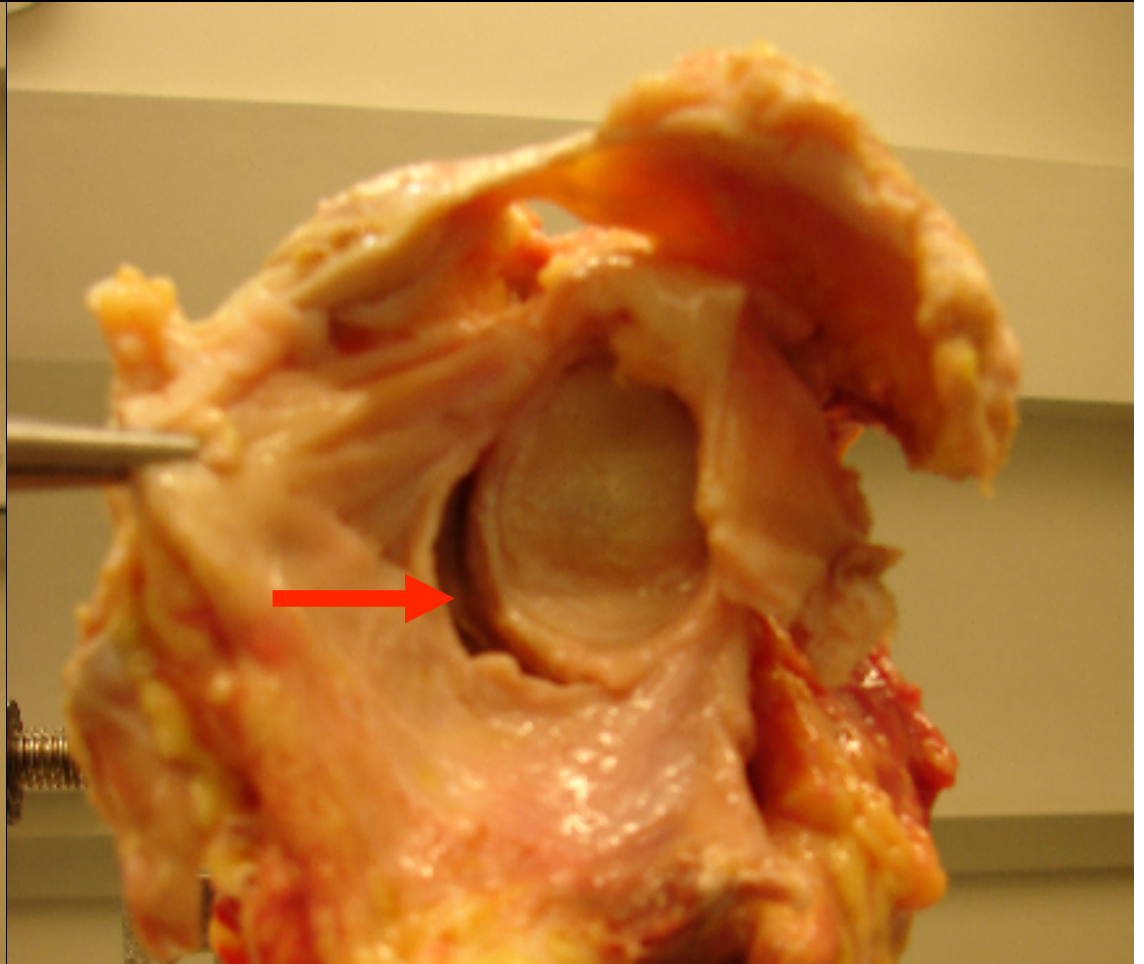
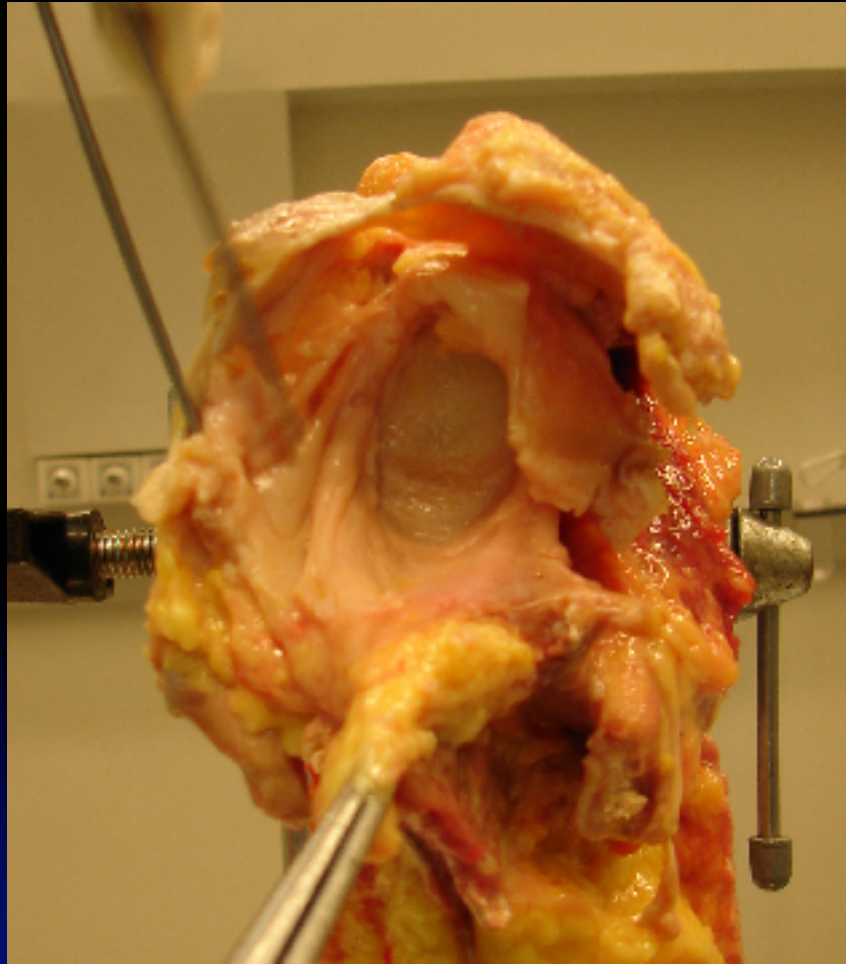


## Βλάβη Bankart 80 - 90%

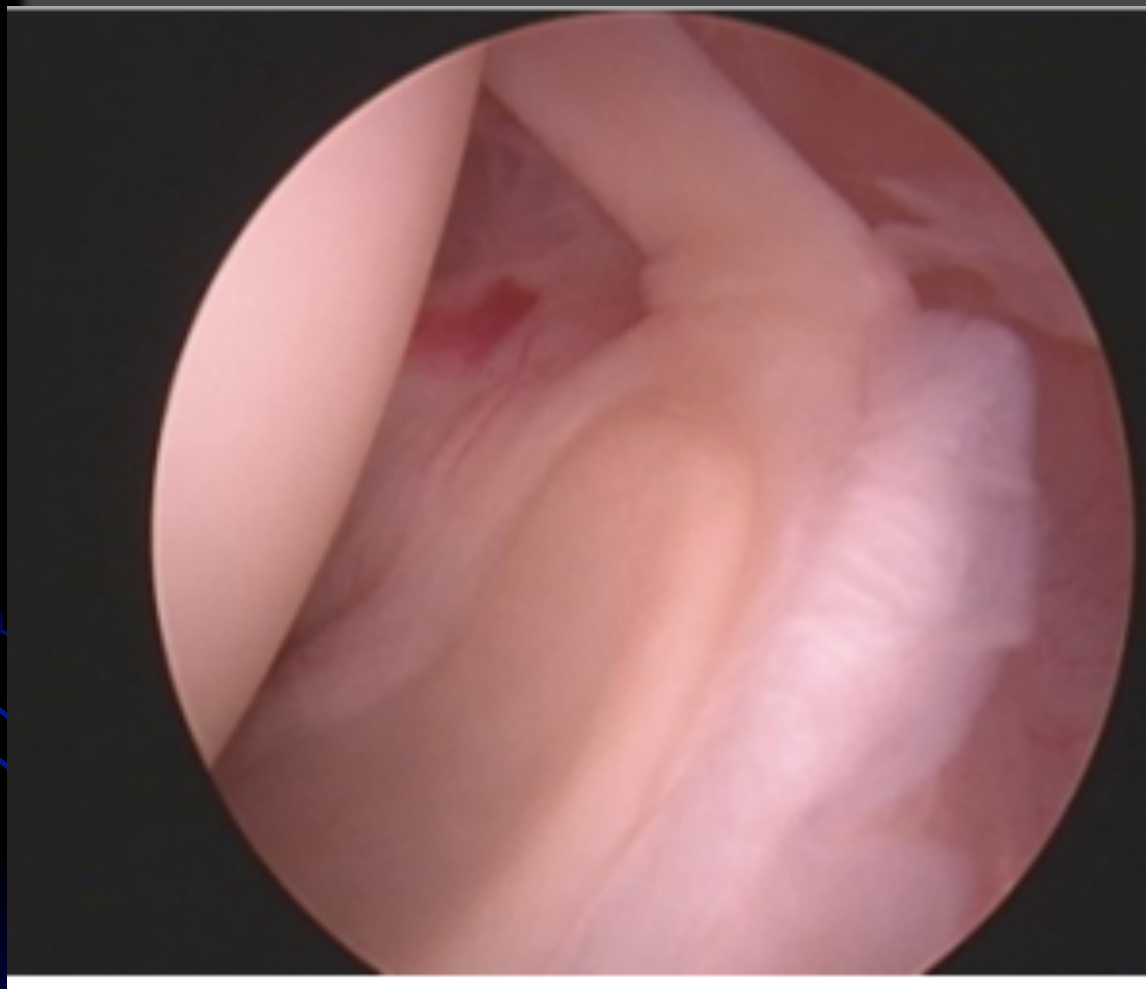


Μαγνητική Τομογραφία

# Βλάβη Bankart

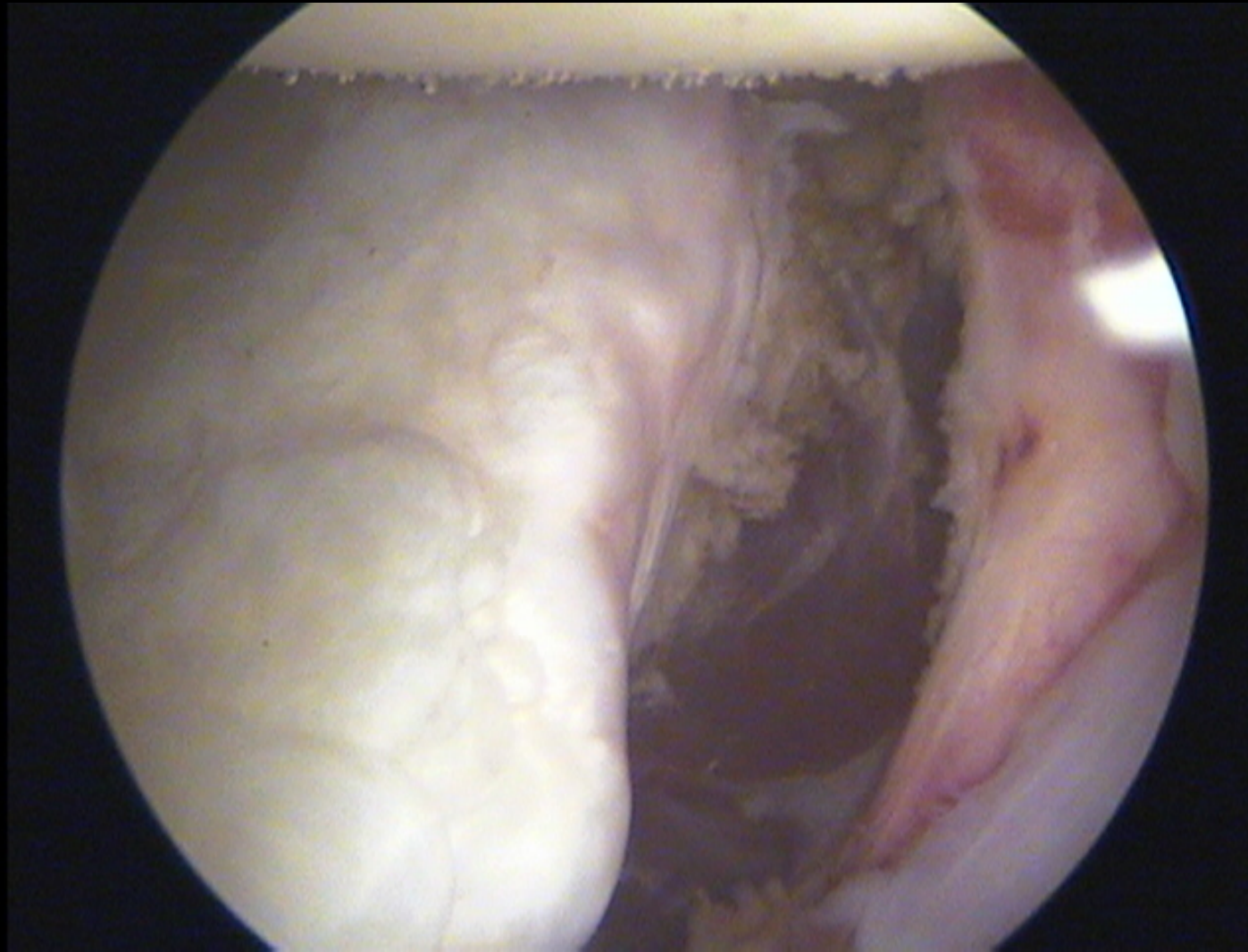


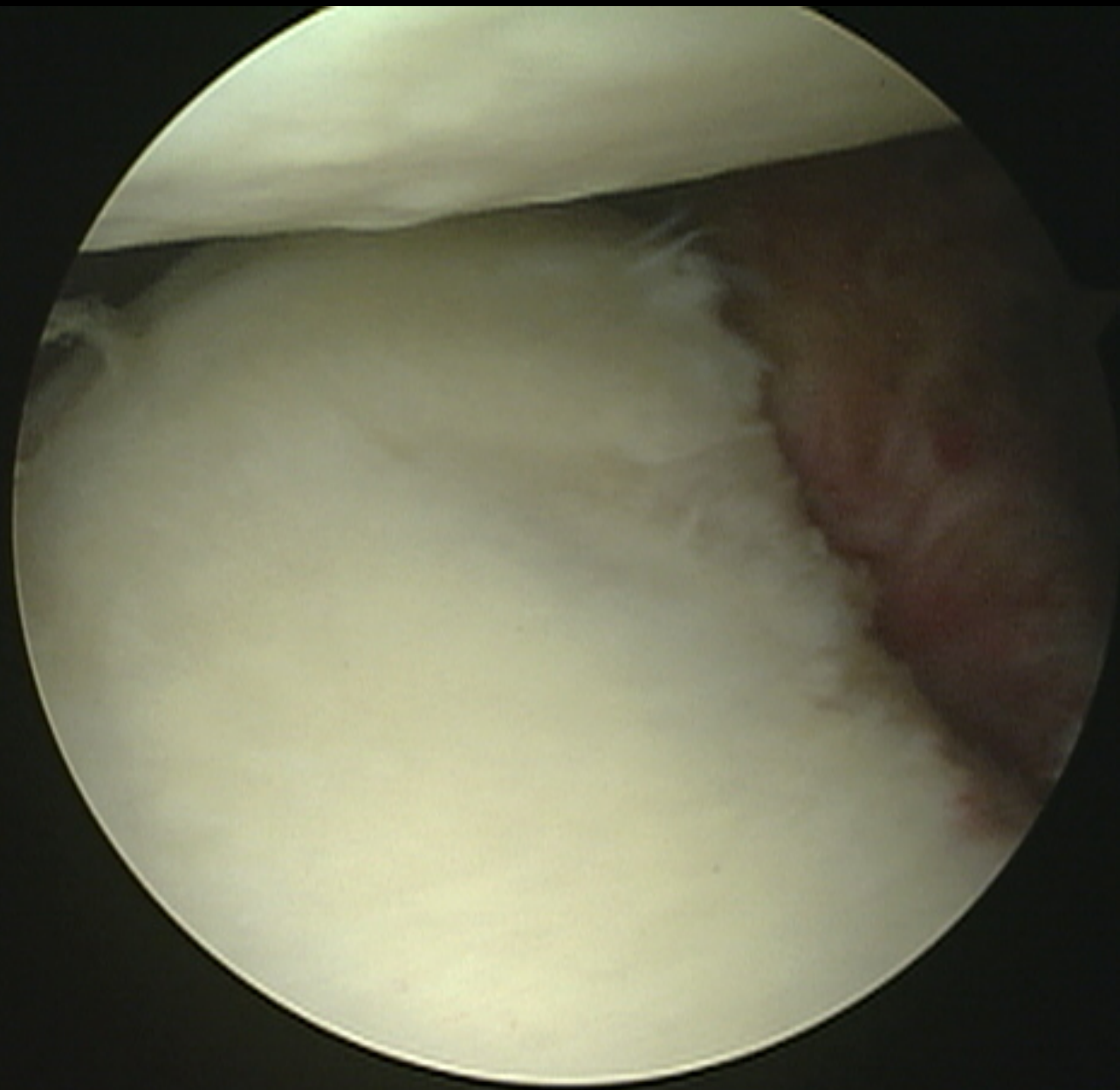
# Normal Biceps Anchor




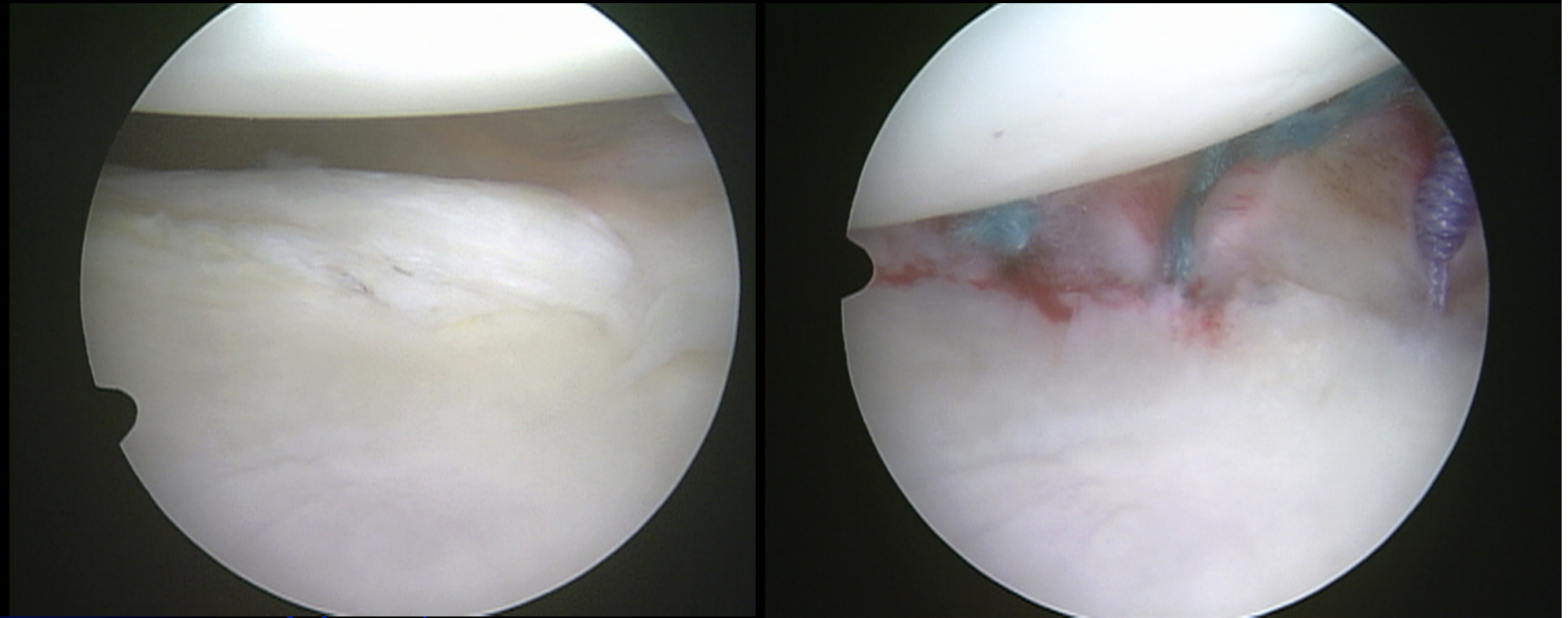


# Anterior Shoulder Instability






# Ανακατασκευή Επιχείλιου Χόνδρου “Labral bumper”



# Υποτροπή Εξαρθρήματος του Ώμου

17% έως 96% (μέσος όρος 67%)



Ο κυριότερος προγνωστικός παράγοντας  
υποτροπής είναι η ηλικία

Υποτροπή


< 20 έτη 64%

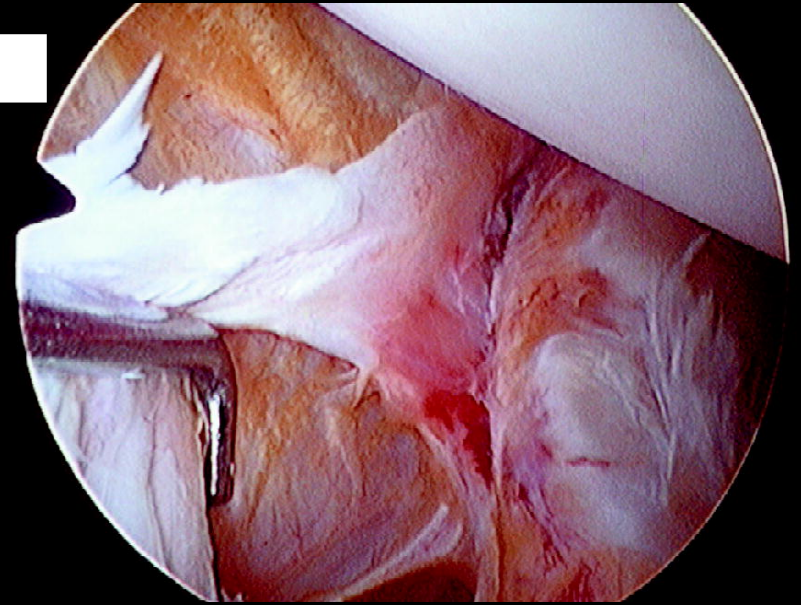
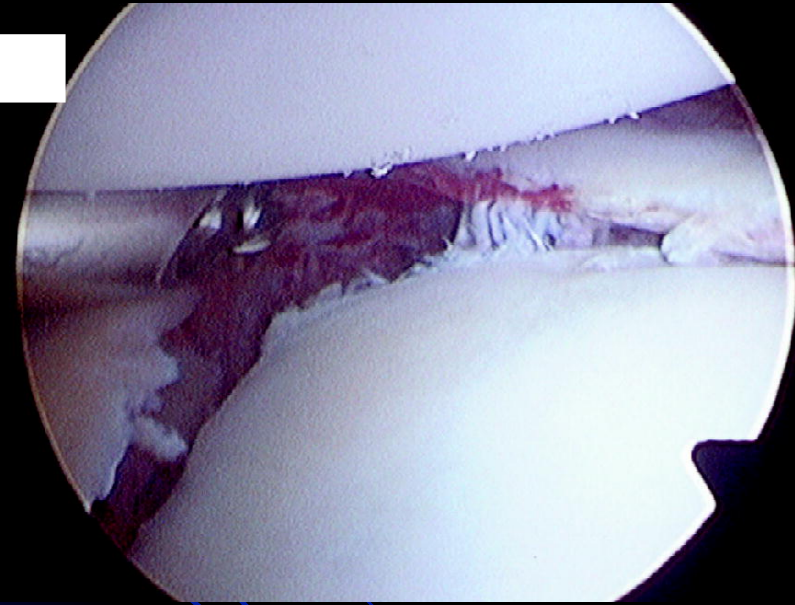
>40 έτη 6%



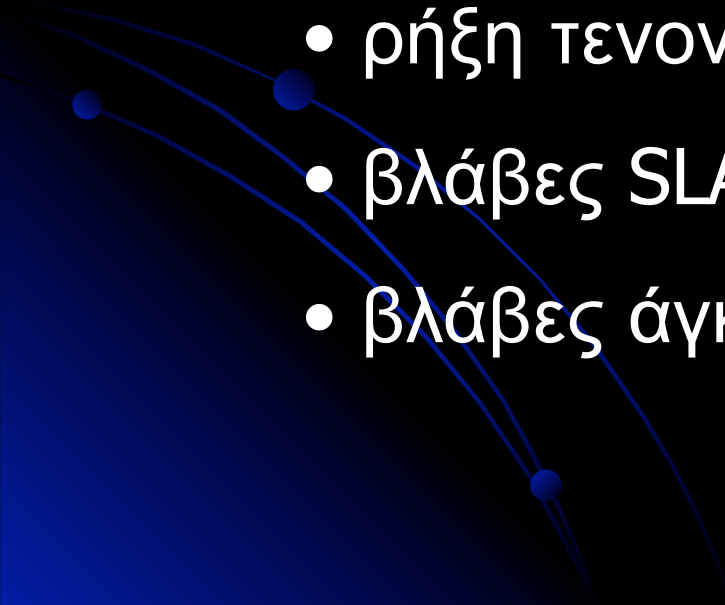
Slaa, JBJS 2004

Η βαρύτητα των δευτερογενών  
βλαβών μετά από εξάρθρημα του  
ώμου αυξάνει ανάλογα με τον αριθμό  
των εξαρθημάτων



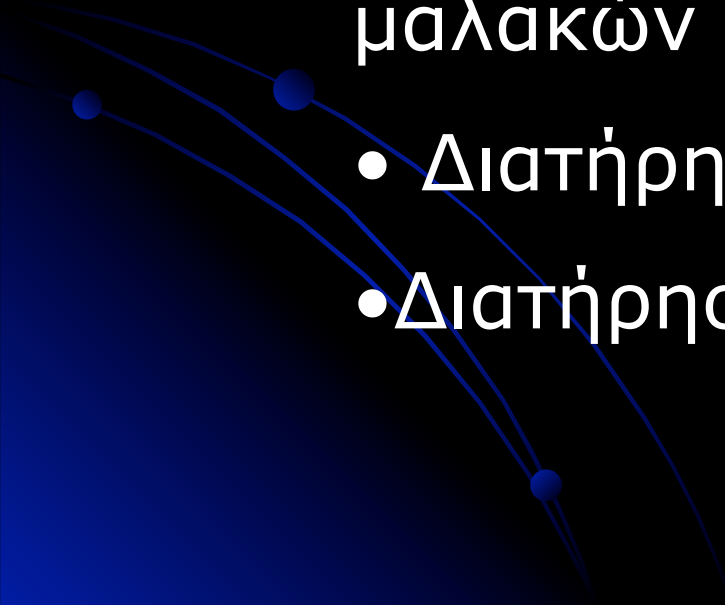


## Δευτερογενείς Κακώσεις

- οστική απώλεια (κεφαλή και ωμογλήνη)
  - διάταση θυλάκου
  - διάταση συνδέσμων
  - ρήξη τενοντίου πετάλου
  - βλάβες SLAP
  - βλάβες άγκυρας δικεφάλου
- 



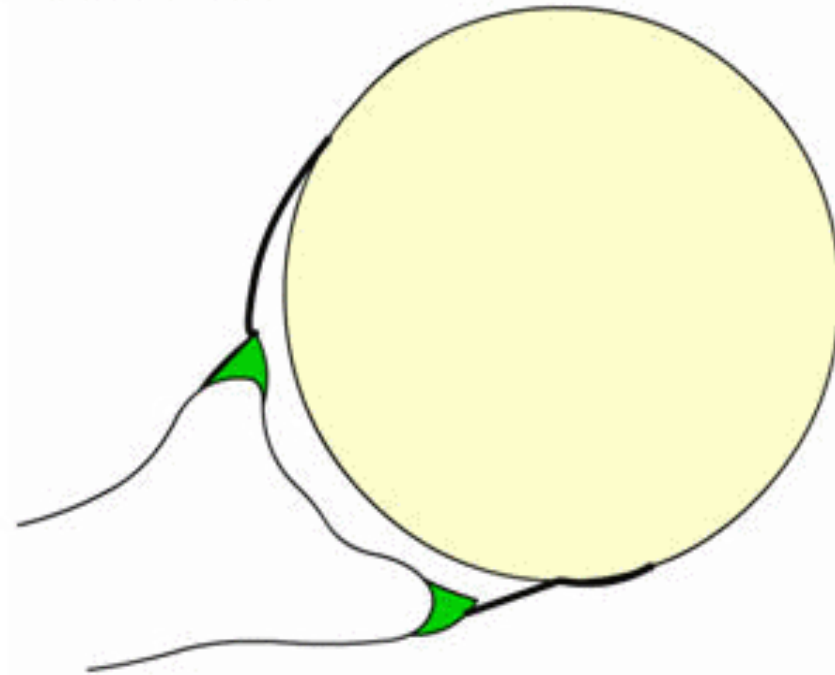
## Στο πρώτο εξάρθημα

- Καλύτερη κατάσταση συνδέσμων
  - Λιγότερες δευτερογενείς βλάβες
  - Πιθανά καλύτερη επούλωση μαλακών μορίων
  - Διατήρηση ιδιοδεκτικότητας
  - Διατήρηση μυϊκού περιβλήματος
- 

# Ακίνητοποίηση σε Έξω Στροφή



Normal

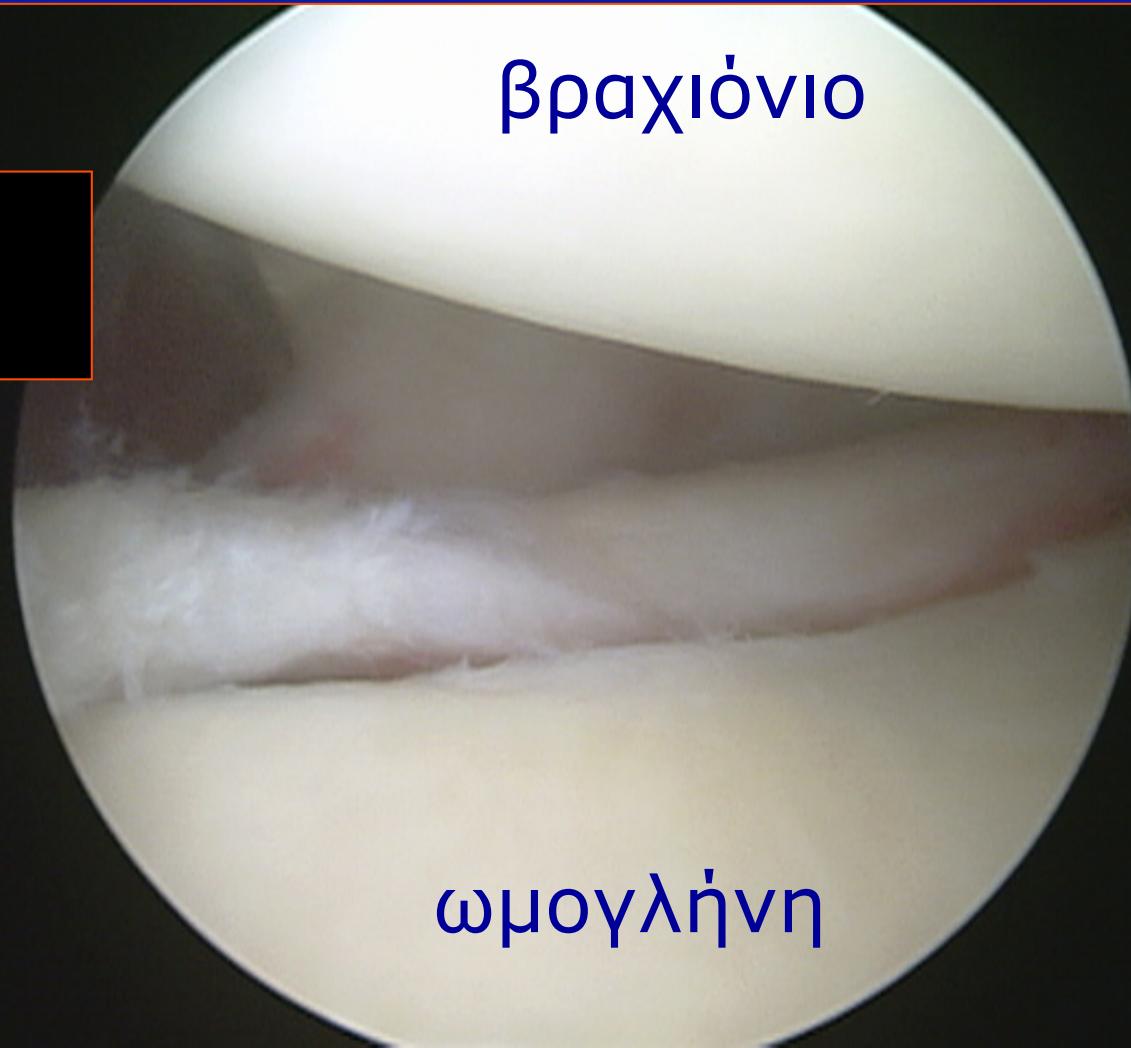


# 1. Αναγνώριση Παθολογικών Αλλοιώσεων

βραχιόνιο

Βλάβη  
Bankart

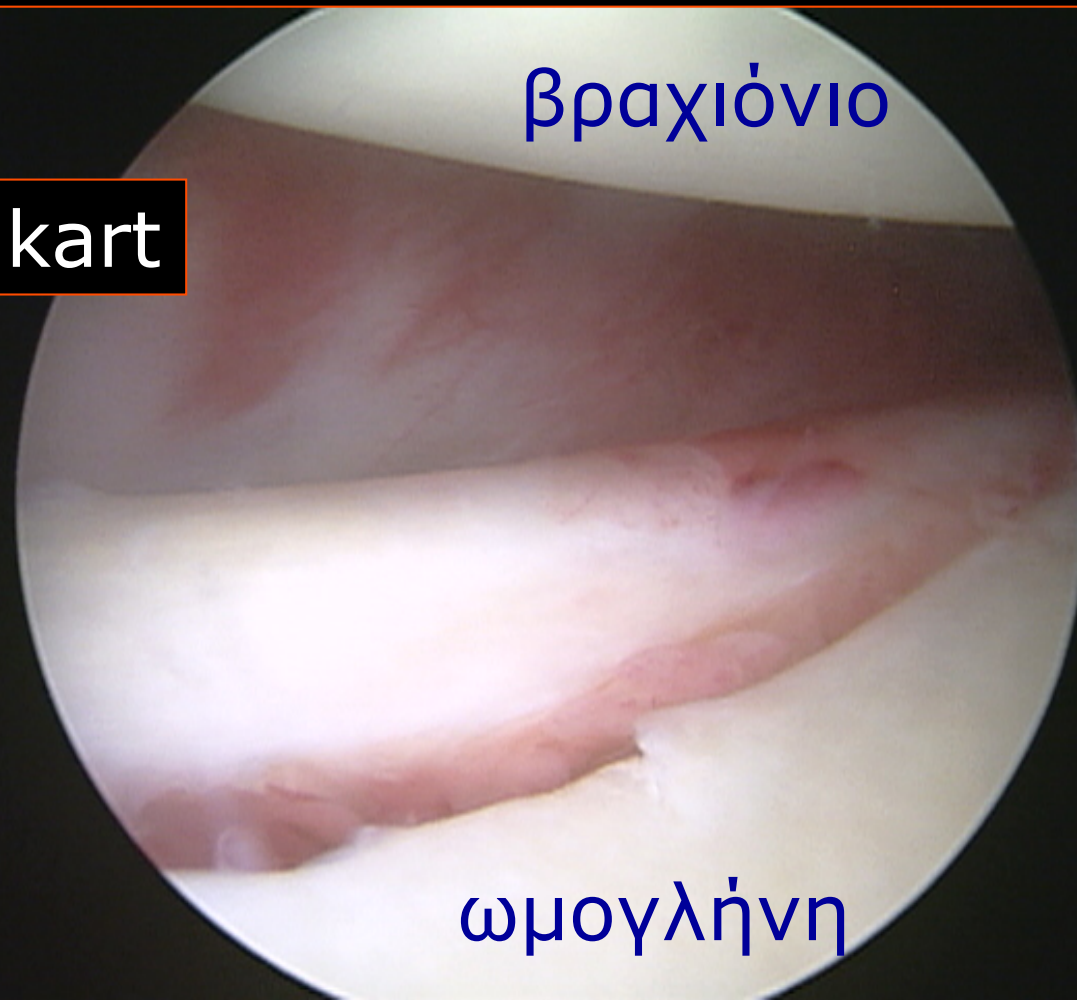
ωμογλήνη



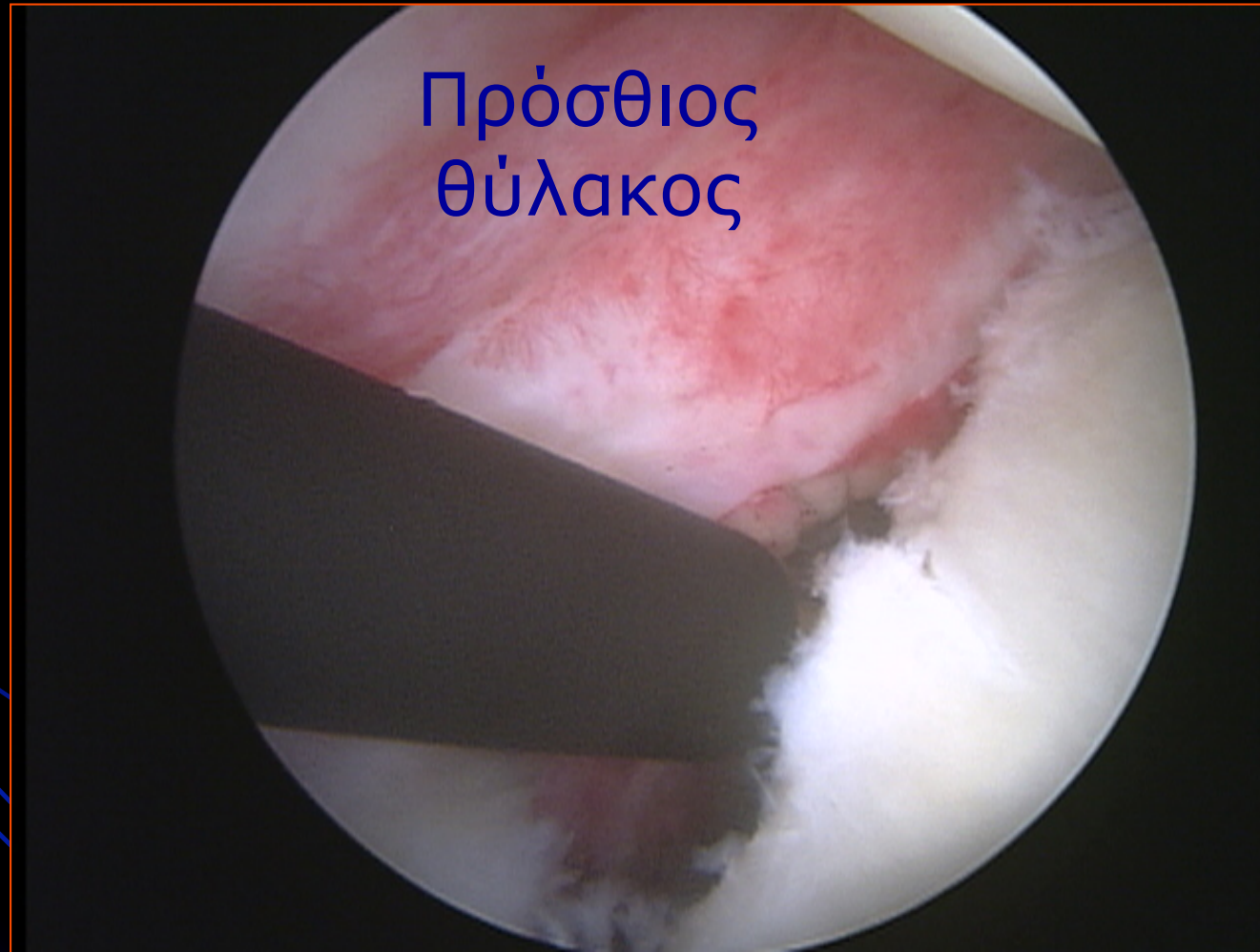# Βλάβη Bankart

βραχιόνιο

ωμογλήνη



## 2. Κινητοποίηση βλάβης Bankart και νεαροποίηση αυχένα ωμογλήνης

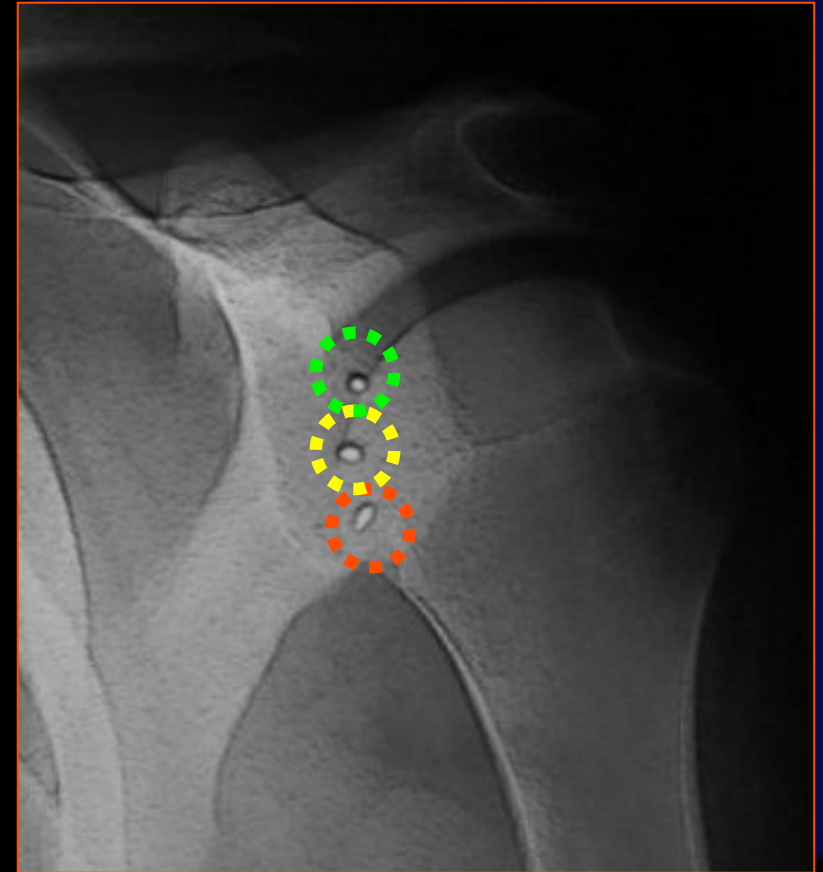


### 3. Τοποθέτηση Αγκυρών

1<sup>η</sup> άγκυρα 5 ο'clock

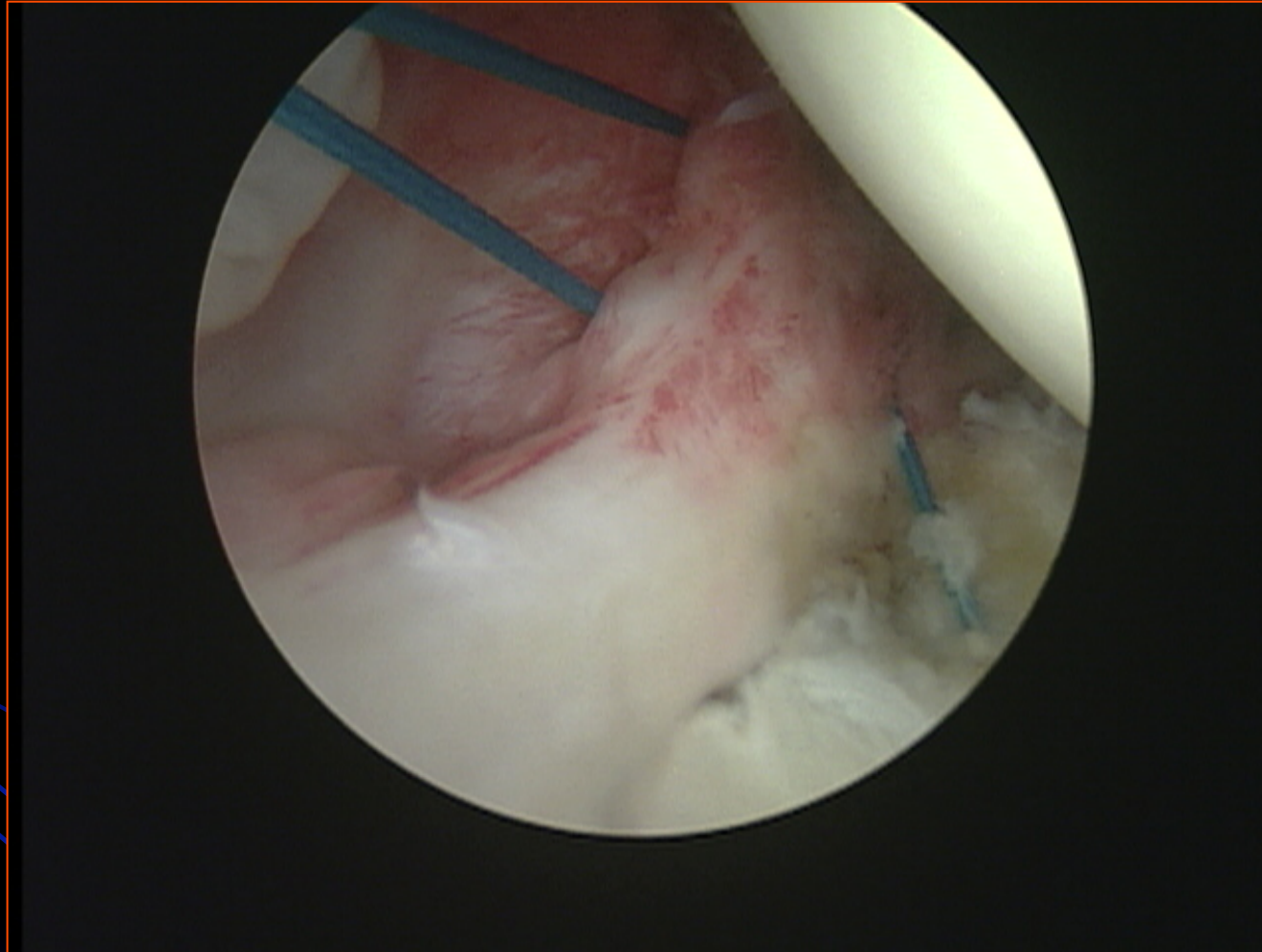
2<sup>η</sup> 3 ο'clock

3<sup>η</sup> 2 ο'clock

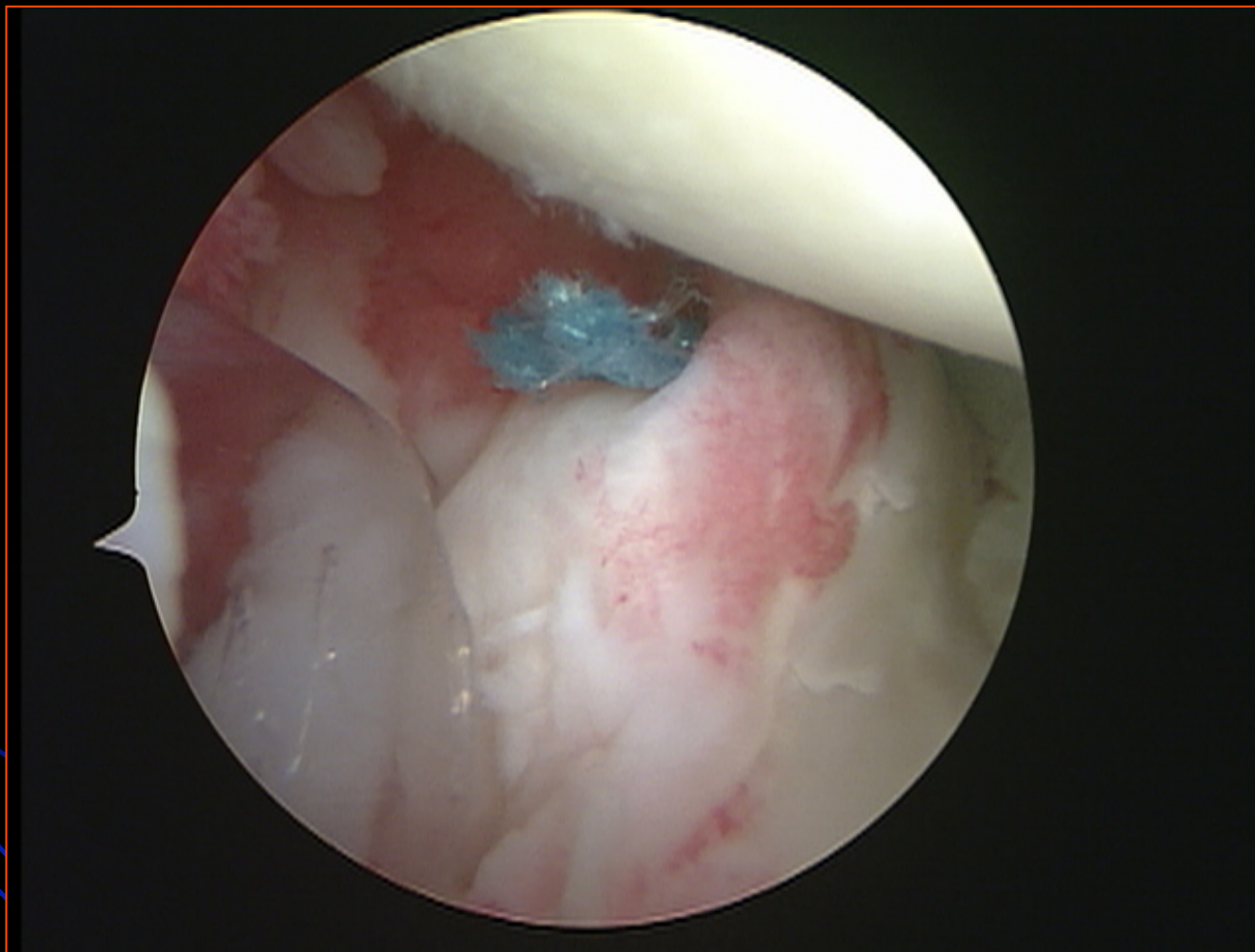


3-4 mm στην αρθρική επιφάνεια

## 4. Διεκβολή Ραμμάτων

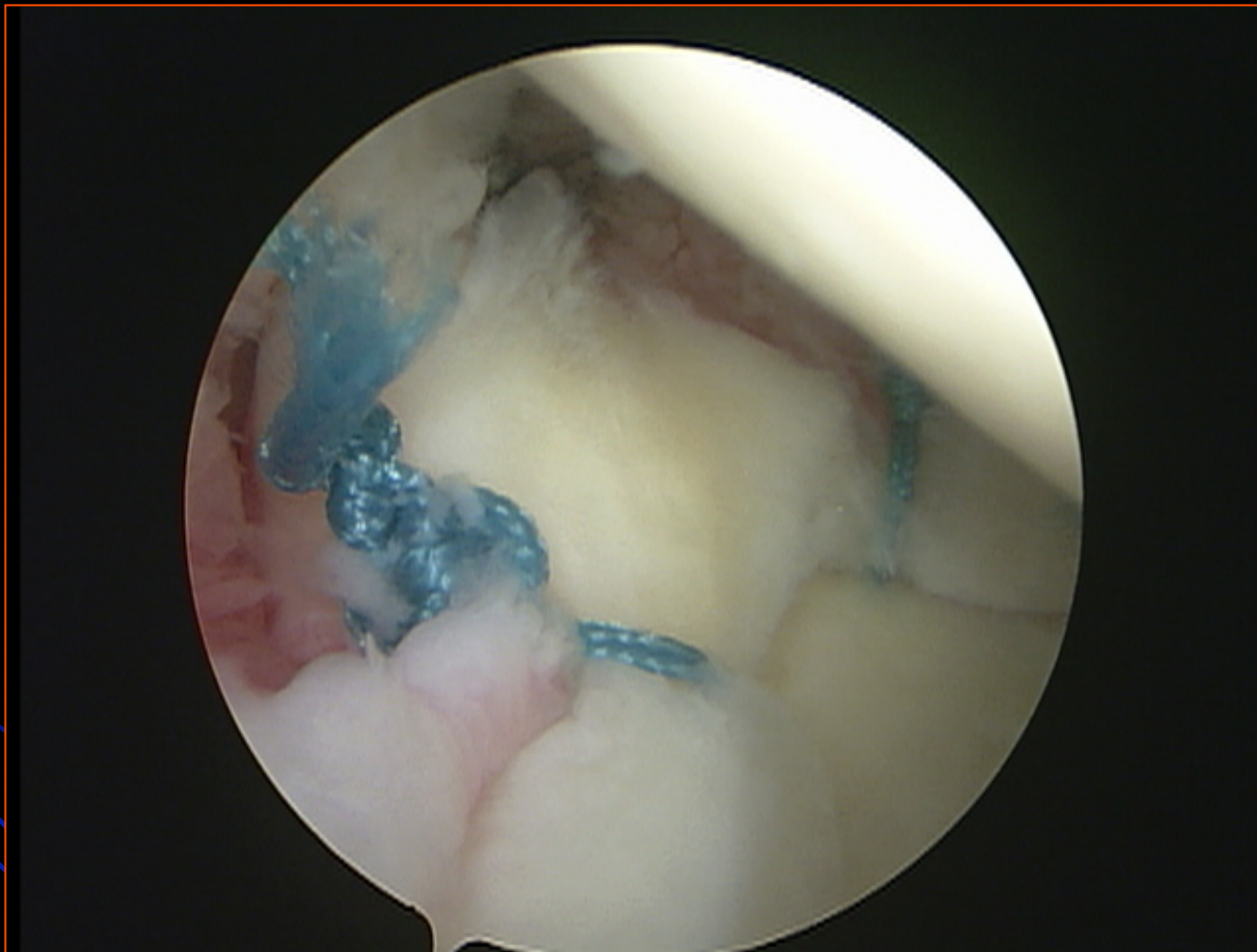

## 5. Κόμποι

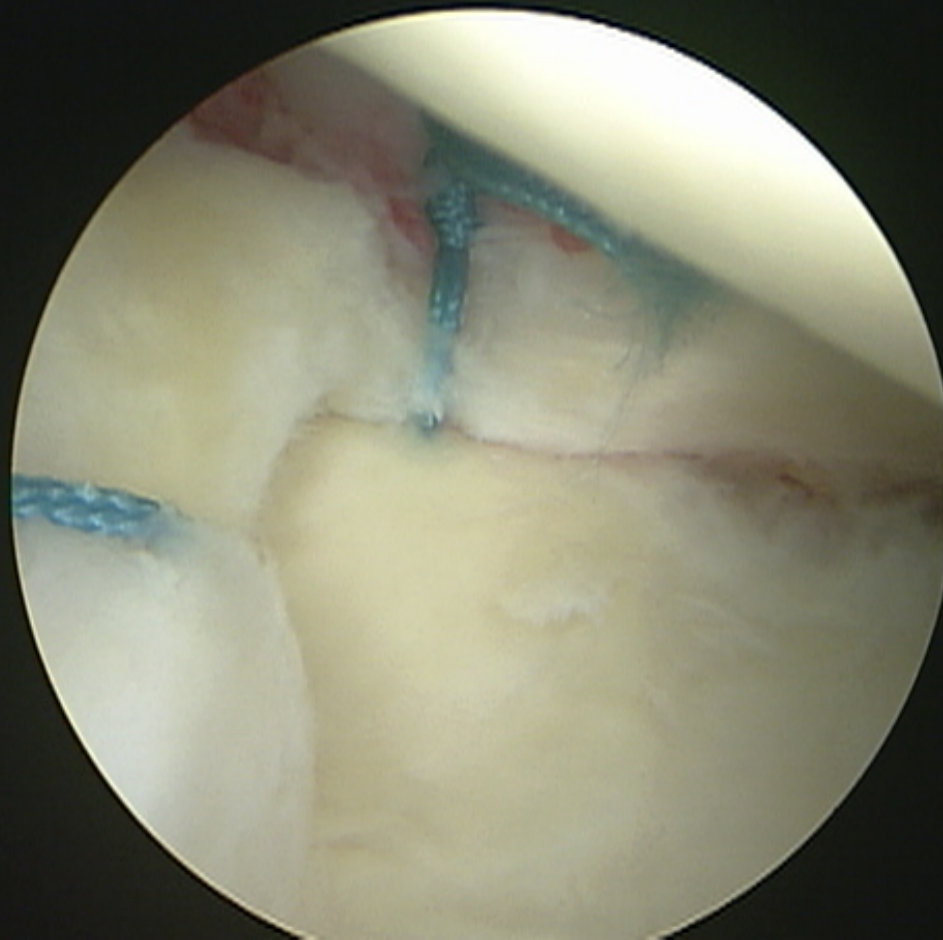




## 6. Τελικό Αποτέλεσμα

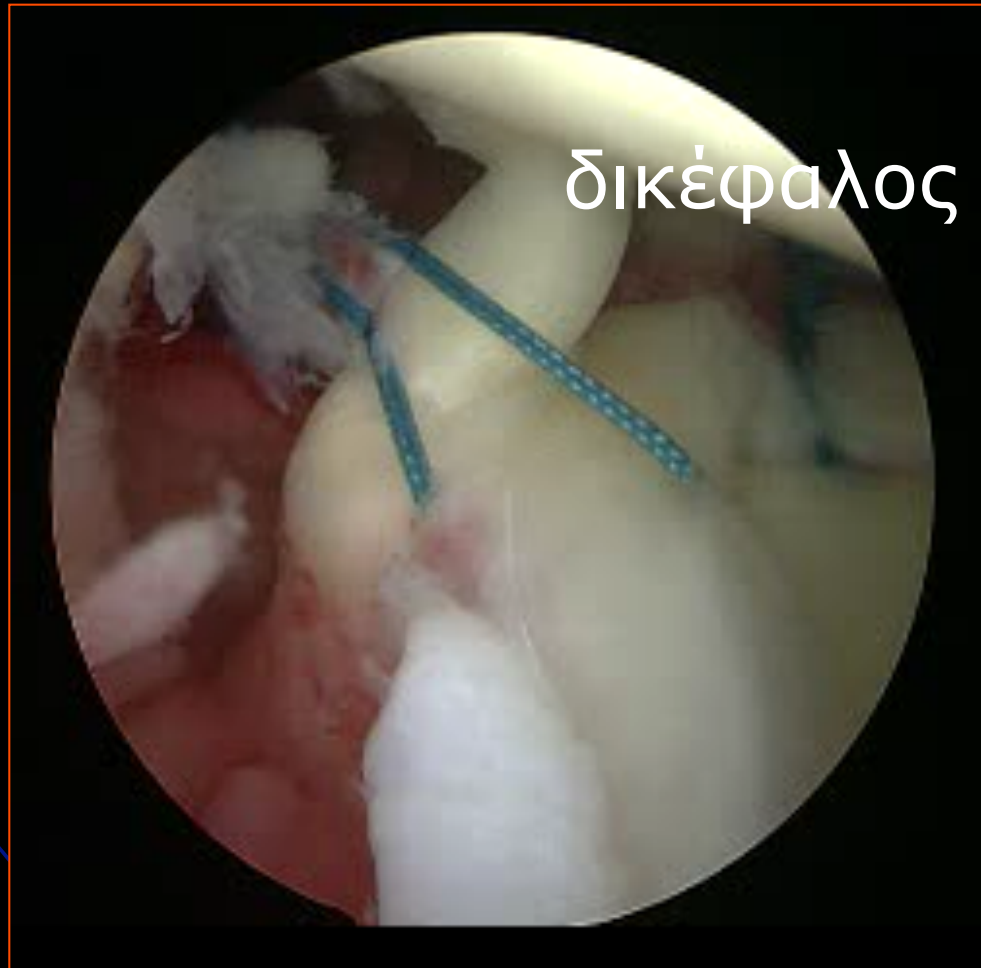

## 6. Τελικό Αποτέλεσμα



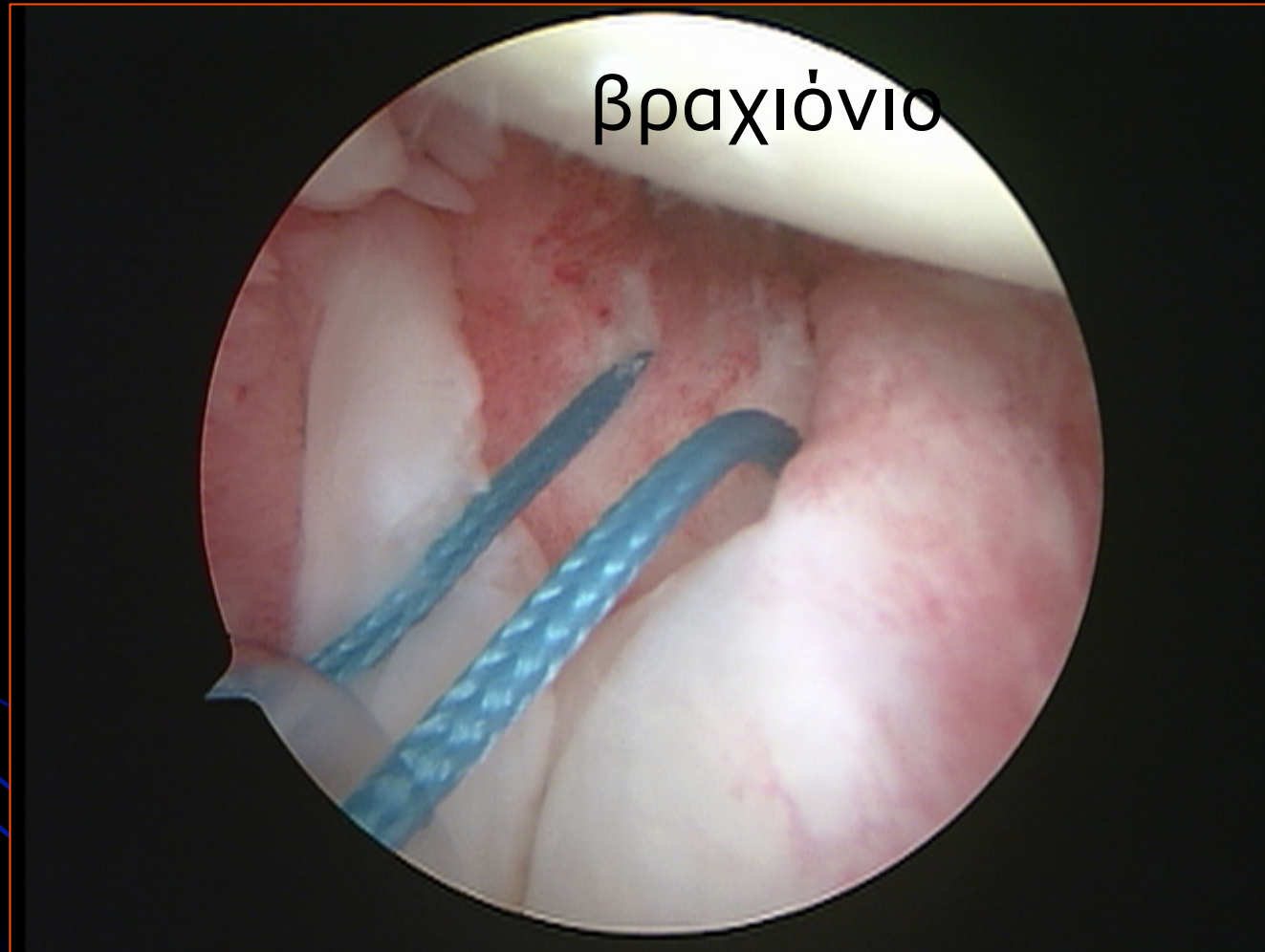Ανακατασκευή του  
Προφυλακτήρα (labral bumper)

# Αποκατάσταση βλάβης SLAP



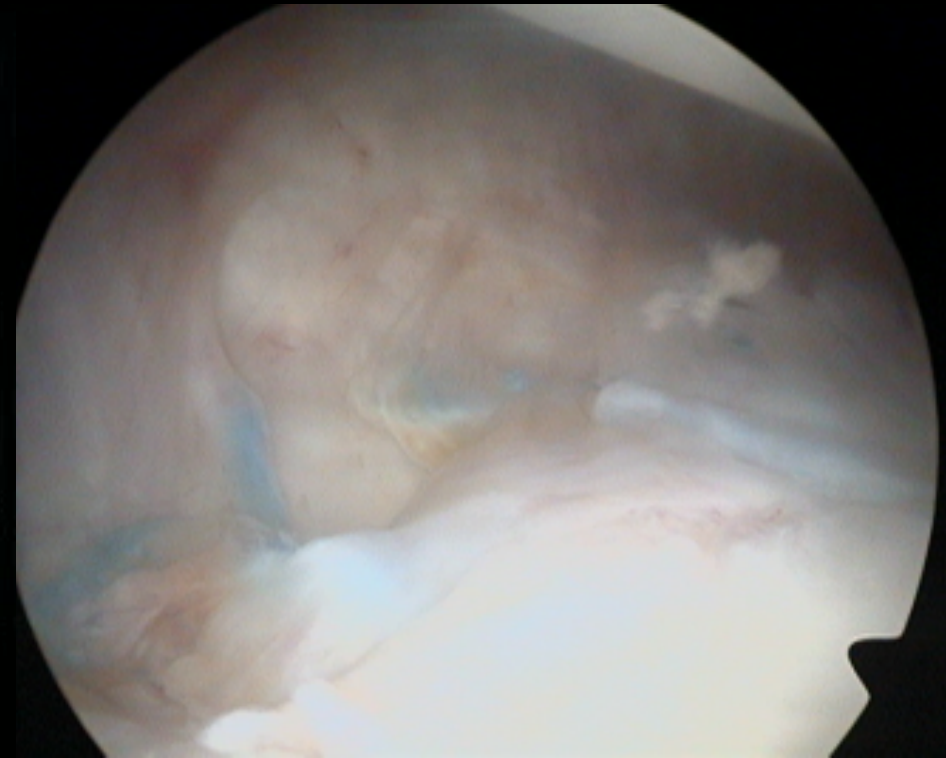
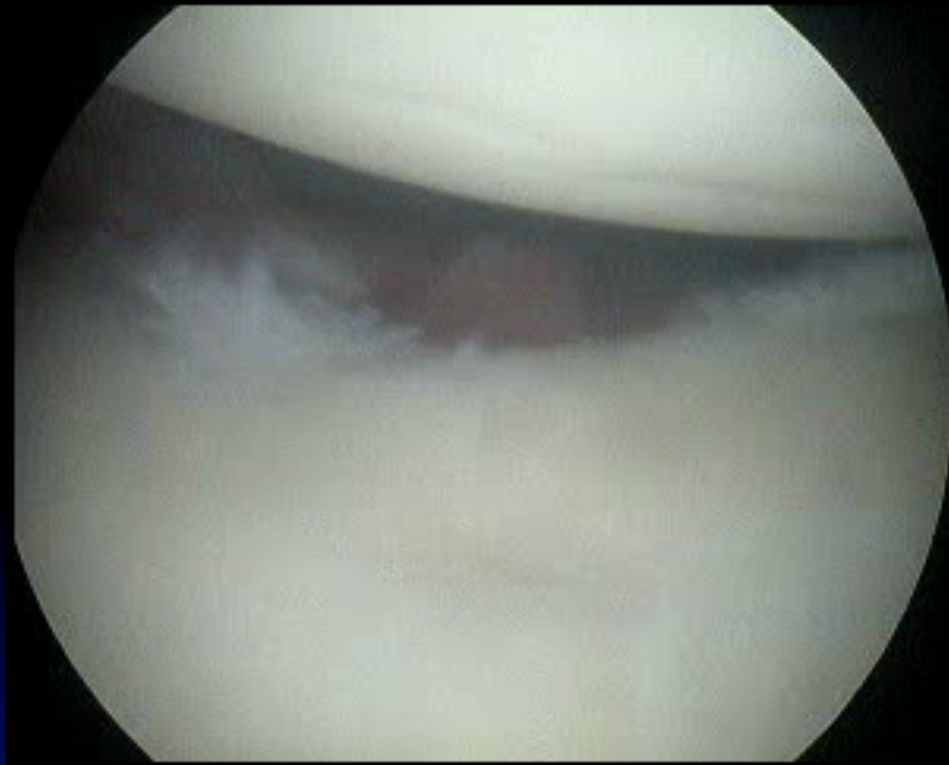Επιχείλιος χόνδρος

# Σύγκλειση Διαστήματος Στροφένων

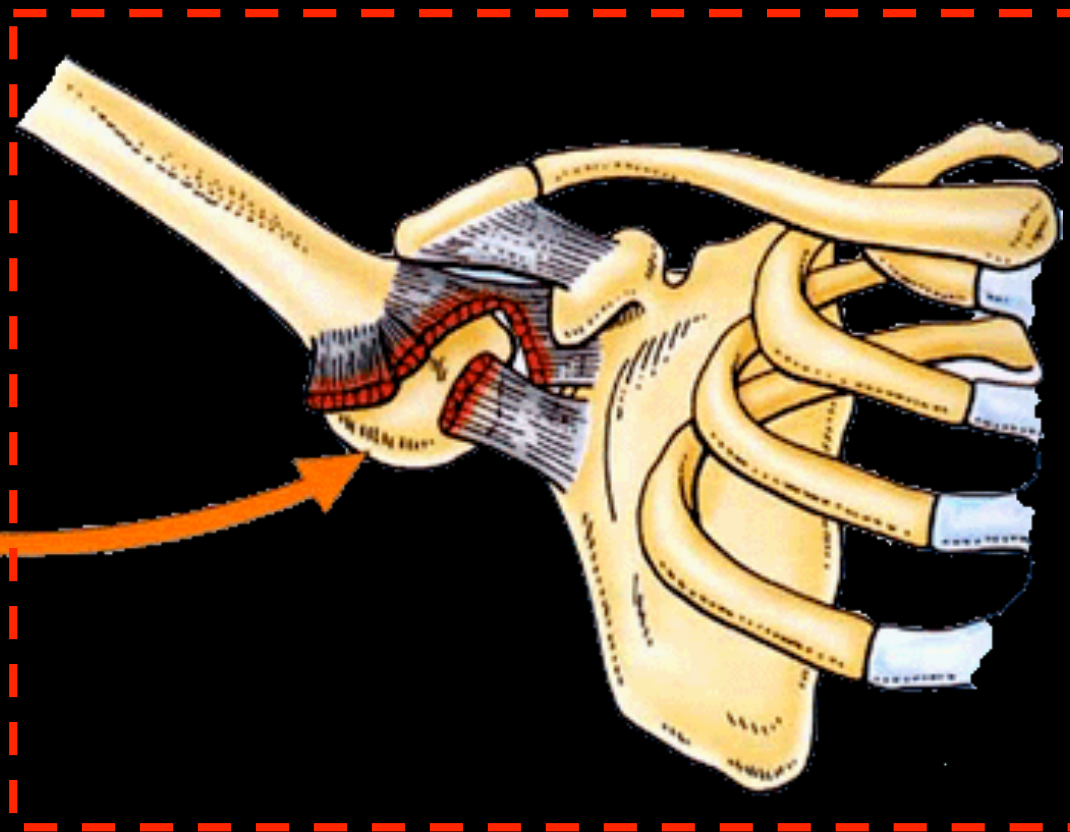


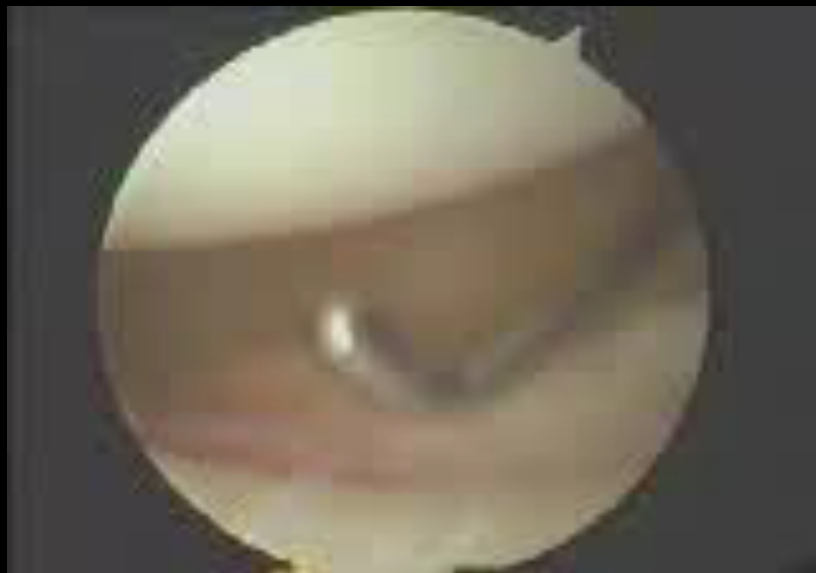
Σε έξω στροφή

10 Μήνες Αργότερα

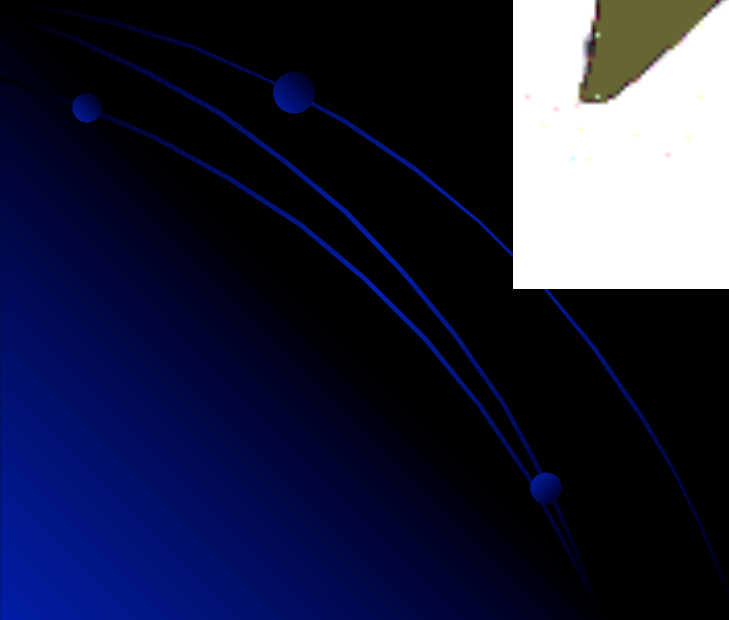


# Ο Ώμος σε Αθλήματα Ρίψεων



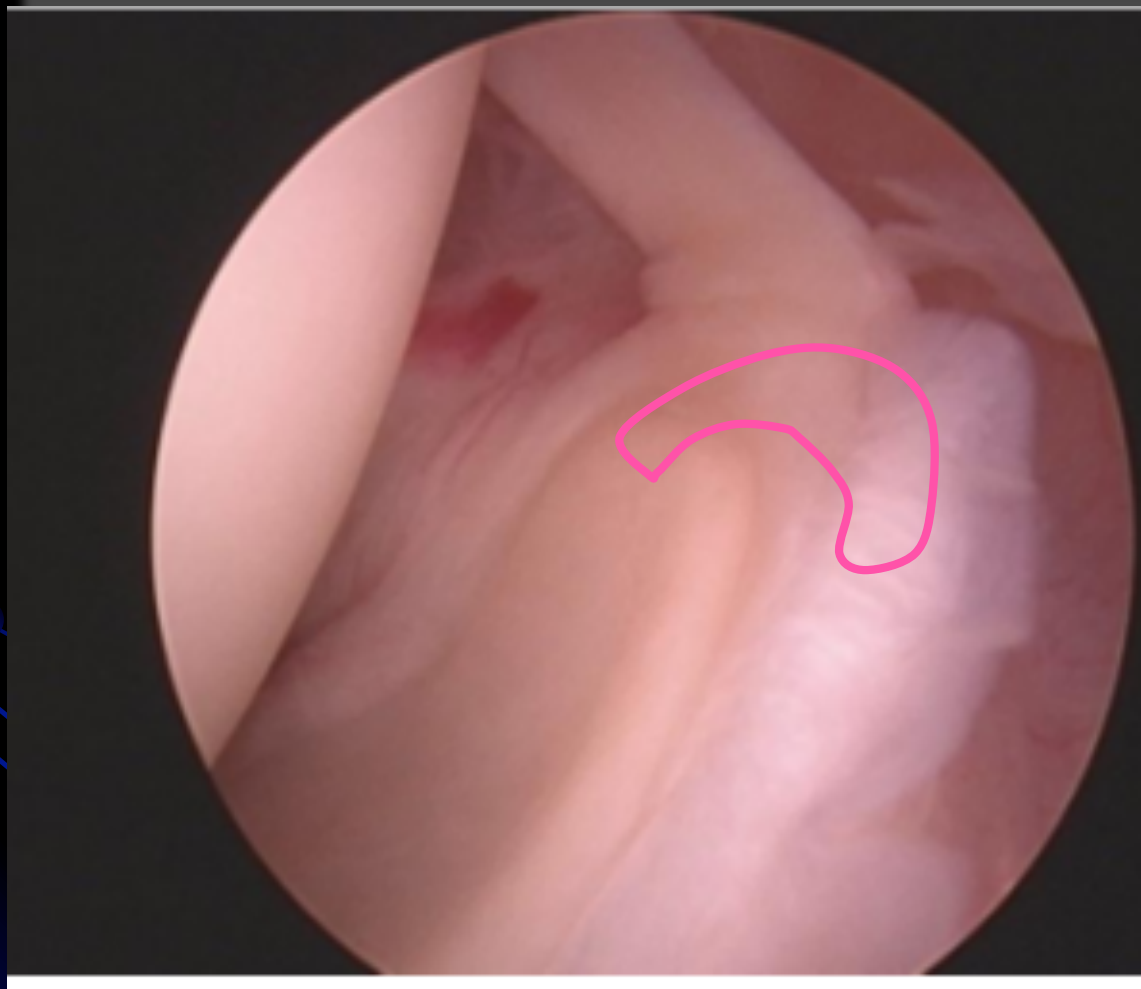


# Βλάβες SLAP

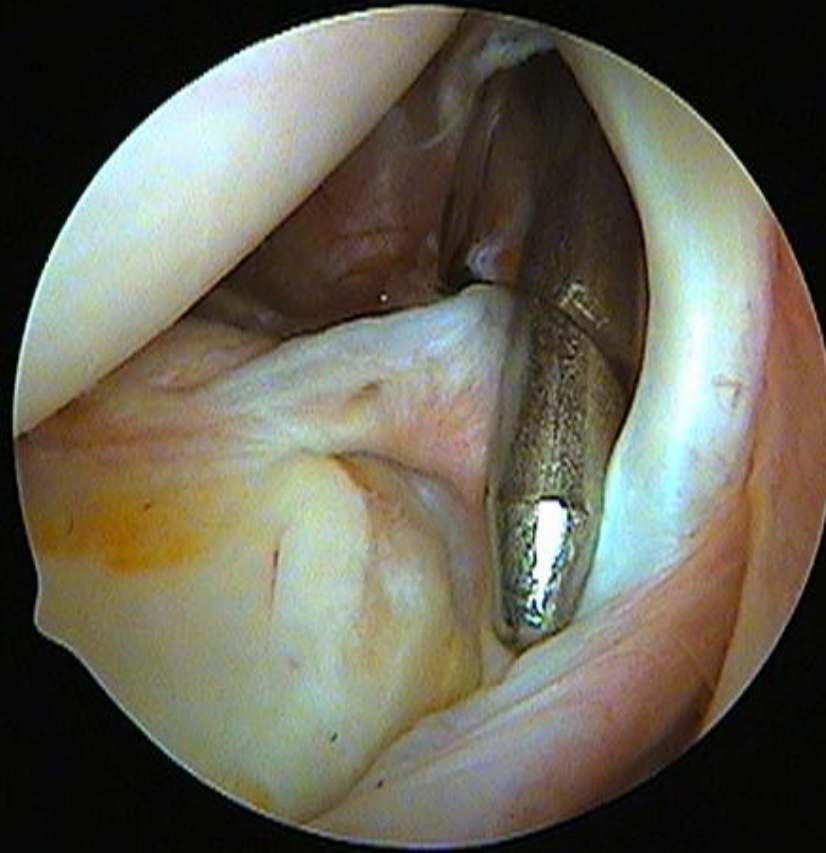





# SLAP Lesions - Definition



# SLAP Lesions - Definition

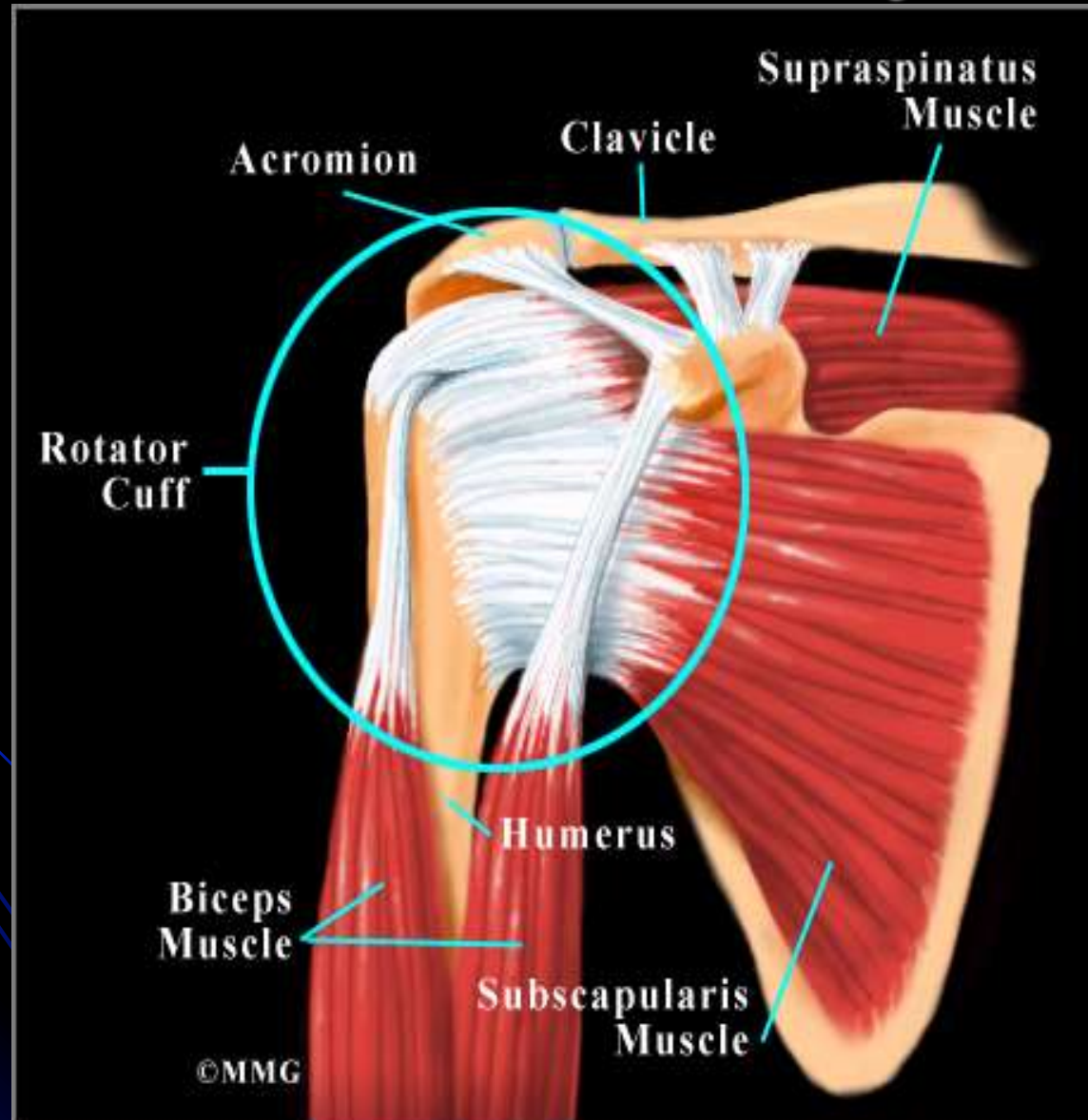


# Επιδιόρθωση Βλάβης SLAP



# Rotator Cuff Tendinitis

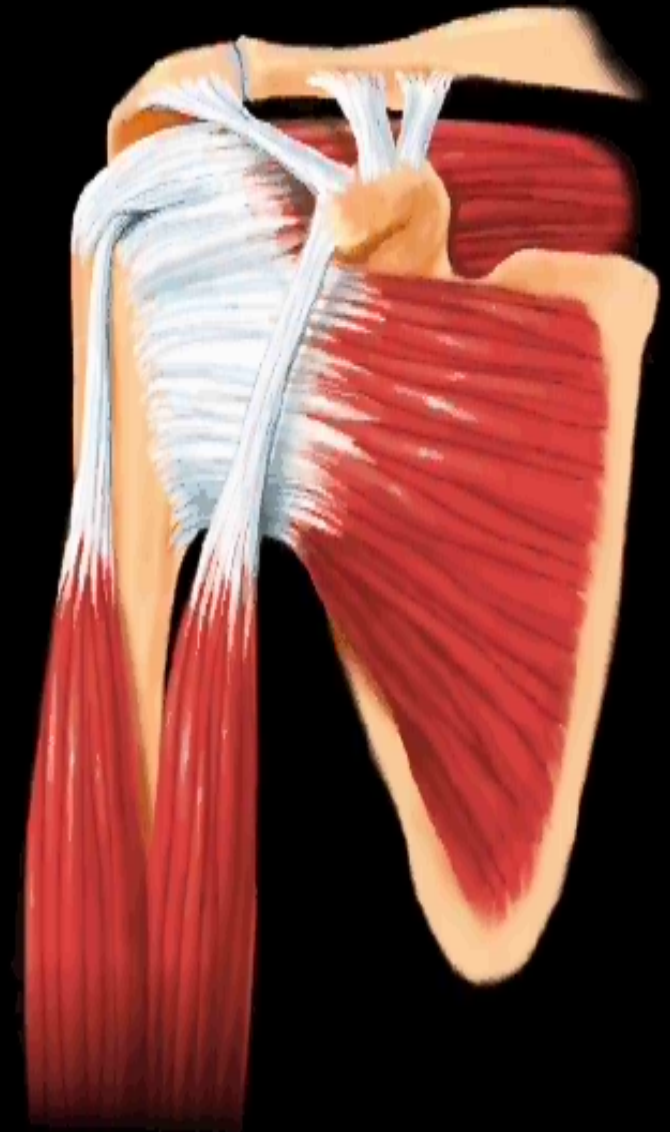## Muscle anatomy



# Rotator Cuff Tendinitis

## Purpose of tendon

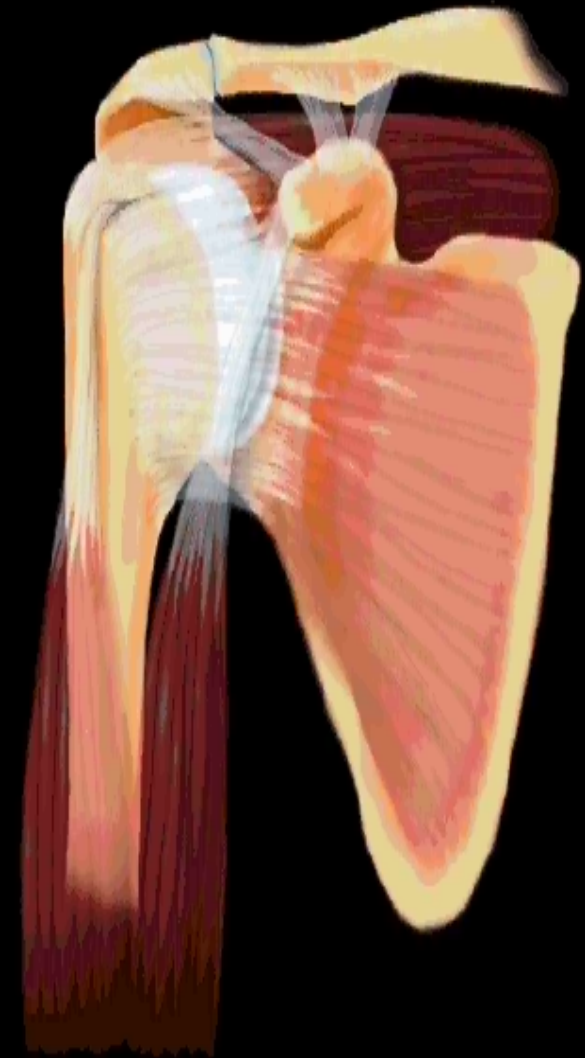- Rotator Cuff  
Tendon connects the Humerus w/ Scapula (shoulder blade)
- Rotator Cuff  
Tendon helps raise/rotate the arm



# Rotator Cuff Tendinitis

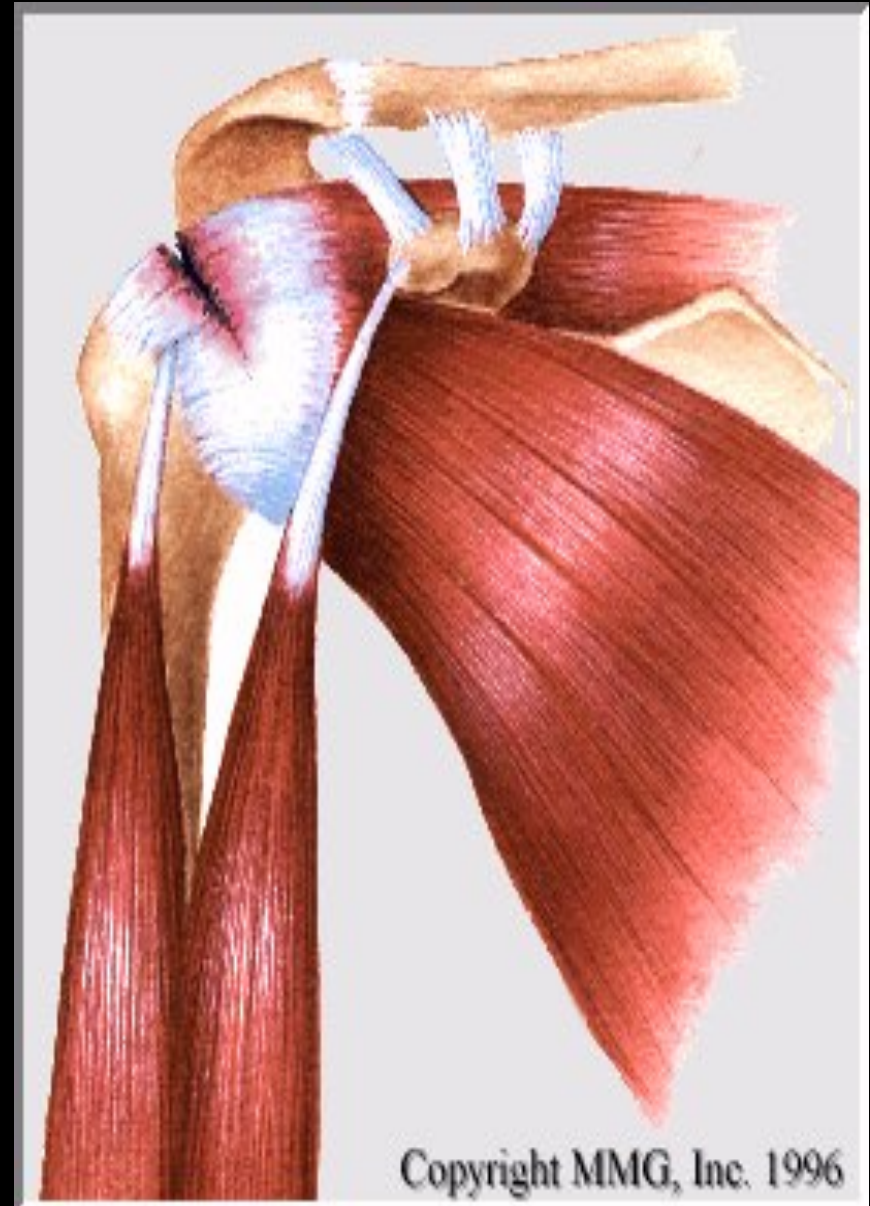## Purpose of tendon

- Rotator Cuff Tendon helps keep the Humerus tightly in the socket of the Scapula



# Rotator Cuff Tendinitis Causes:

- Rotator Cuff Tendon has areas where there is very poor blood supply (hence weakened shoulder)
- Weak shoulders + Excessive force = Torn Rotator Cuff
- Could occur at any age
- Caused by lifting heavy objects



Copyright MMG, Inc. 1996

# Rotator Cuff Tendinitis

## Symptoms:

- Pain
- Weakness
- Results in “Catching” Sensation
- Partial Tear:
  - may cause pain only
  - Still allows arm to be raised
- Complete Tear:
  - Causes pain
  - Causes inability to raise arm
  - Inability to sleep on affected side

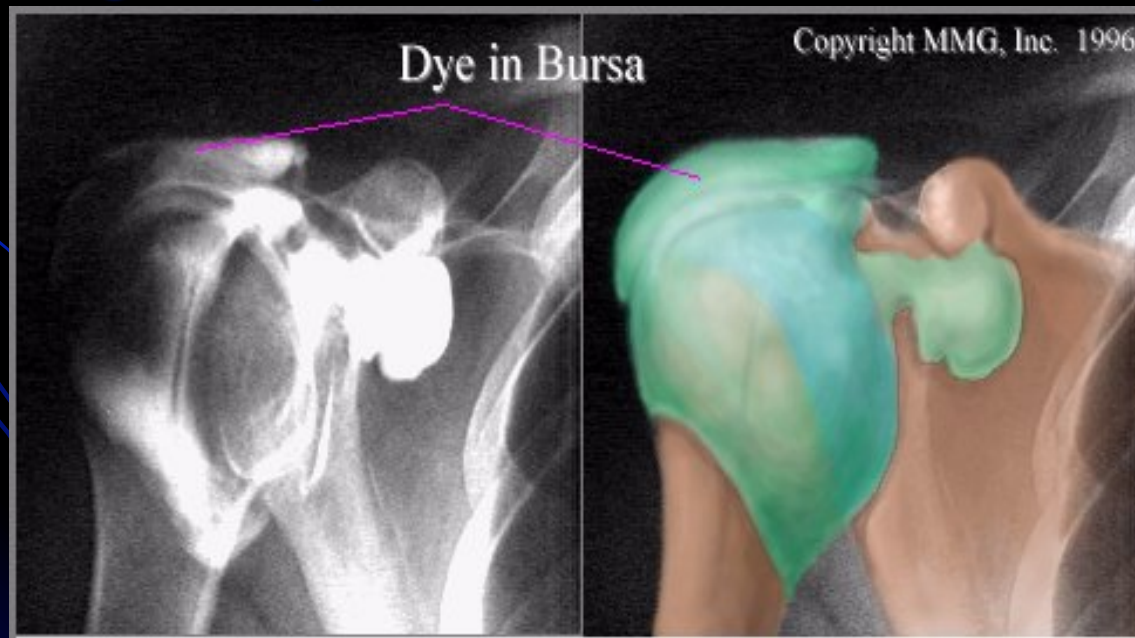




# Rotator Cuff Tendinitis

## Diagnosis:

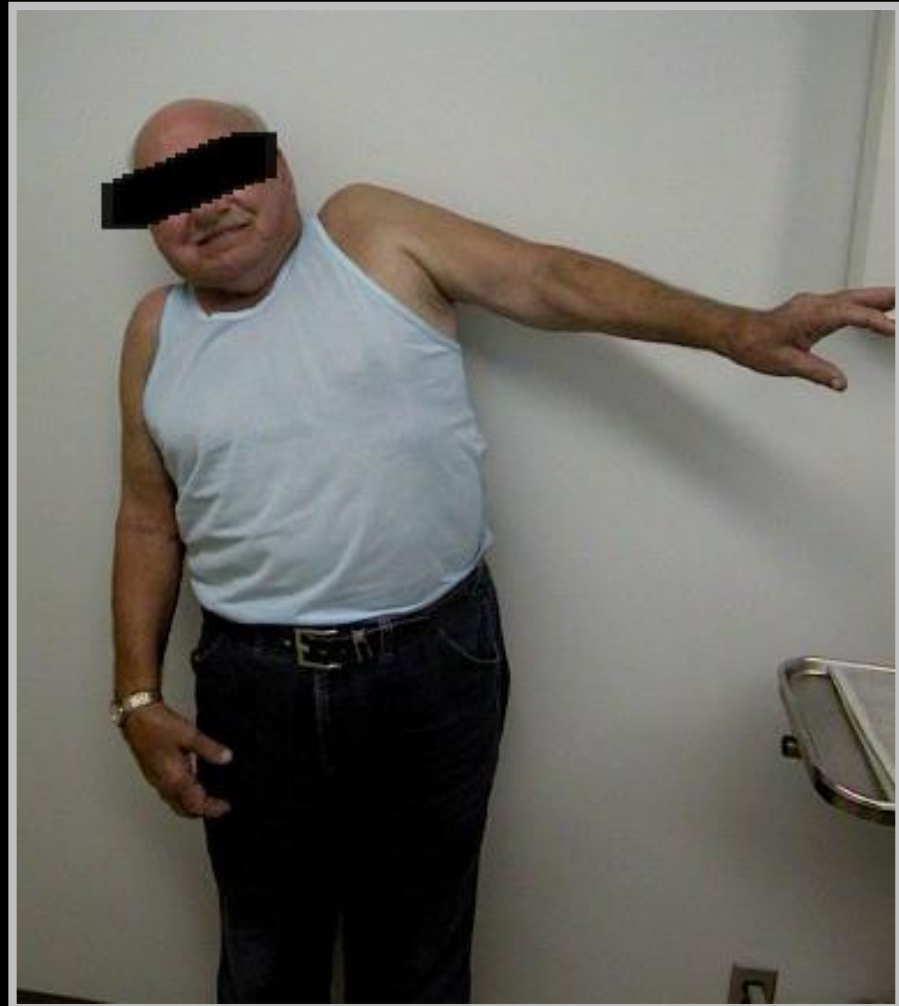- If Dr. can move your arm in normal positions, but you can't, there is tear in the RC tendon
- Arthrogram (an older test)
  - Leakage of dye indicates a tear



## Supraspinatus rupture

### Drop arm sign

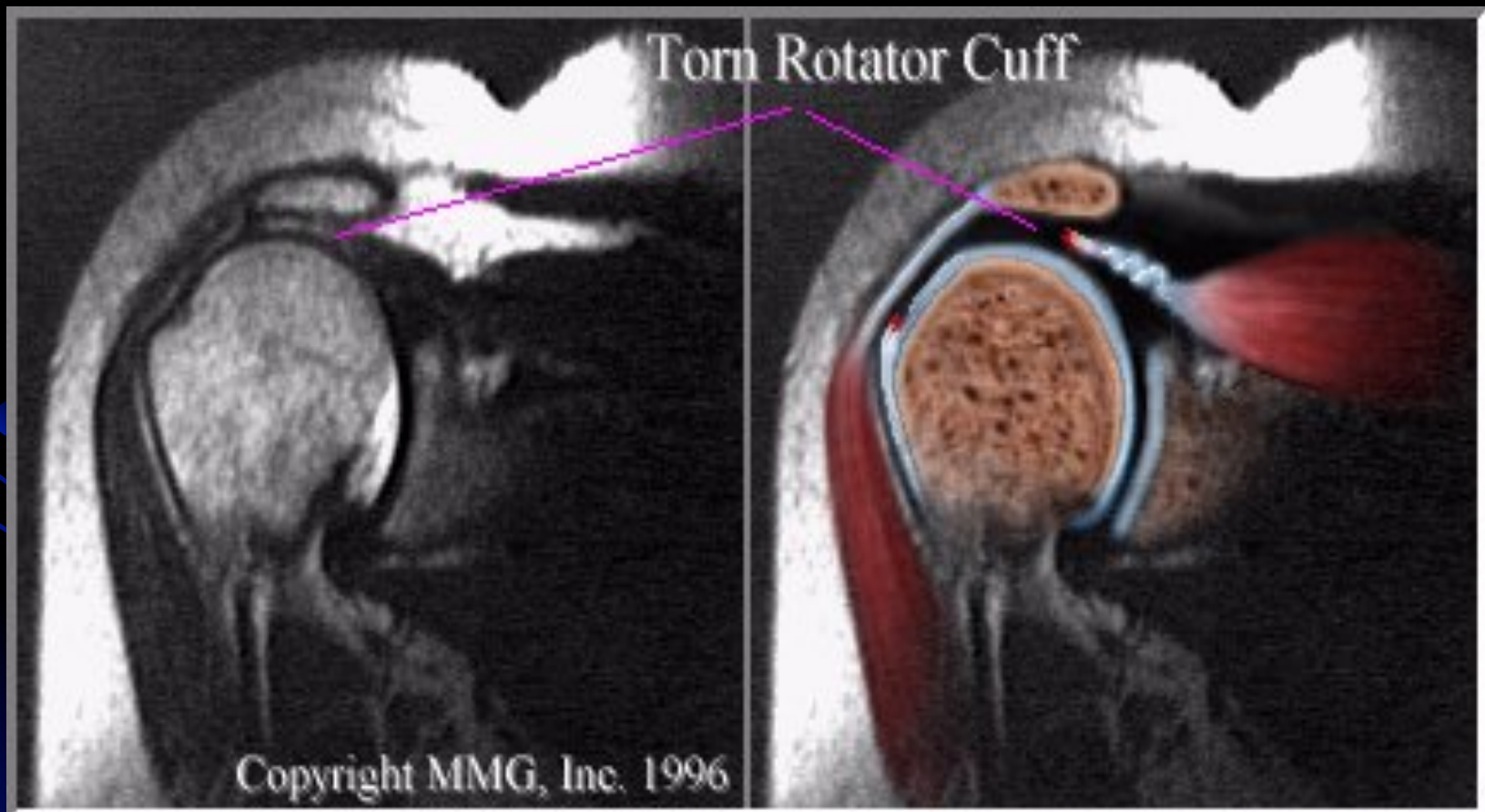
- Weak abduction
- Can't lift arm above head
- Can't maintain arm in abduction



# Rotator Cuff Tendinitis

## Diagnosis:

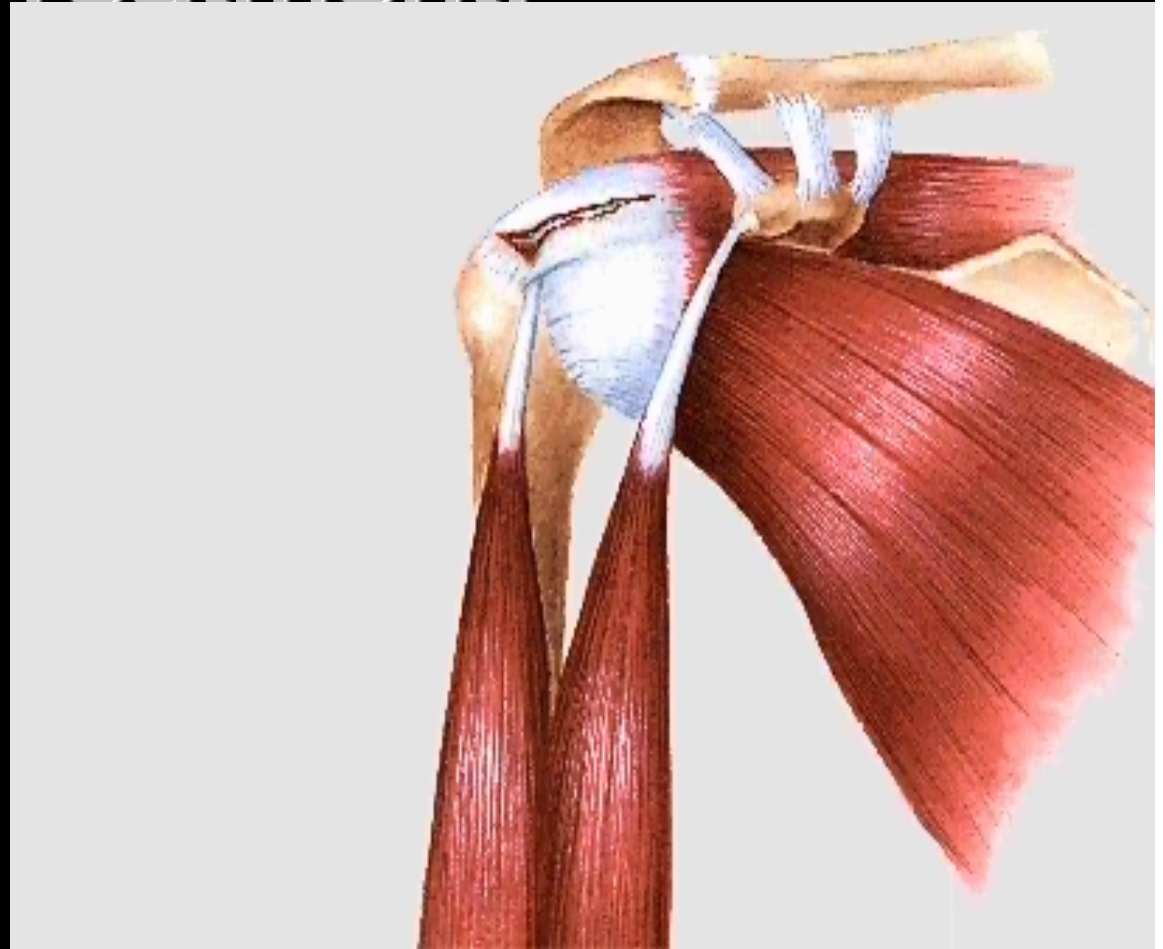- MRI (Painless, requires no injection)



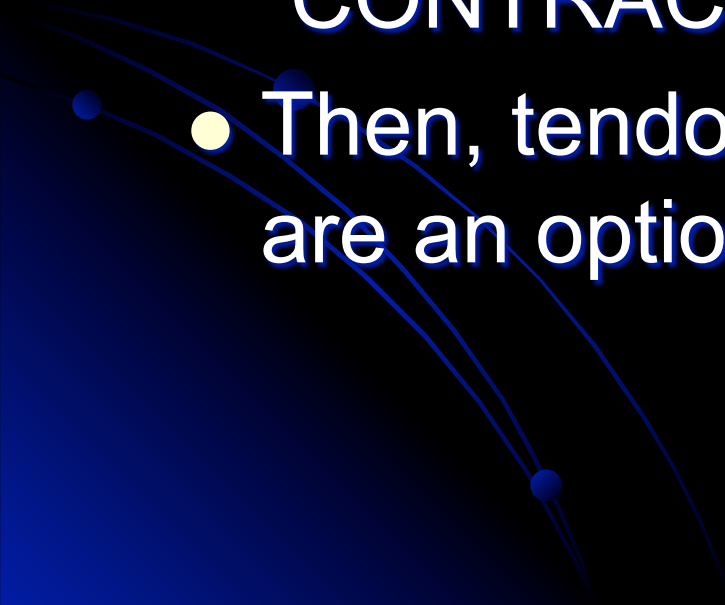
# Rotator Cuff Tendinitis

## Treatment:

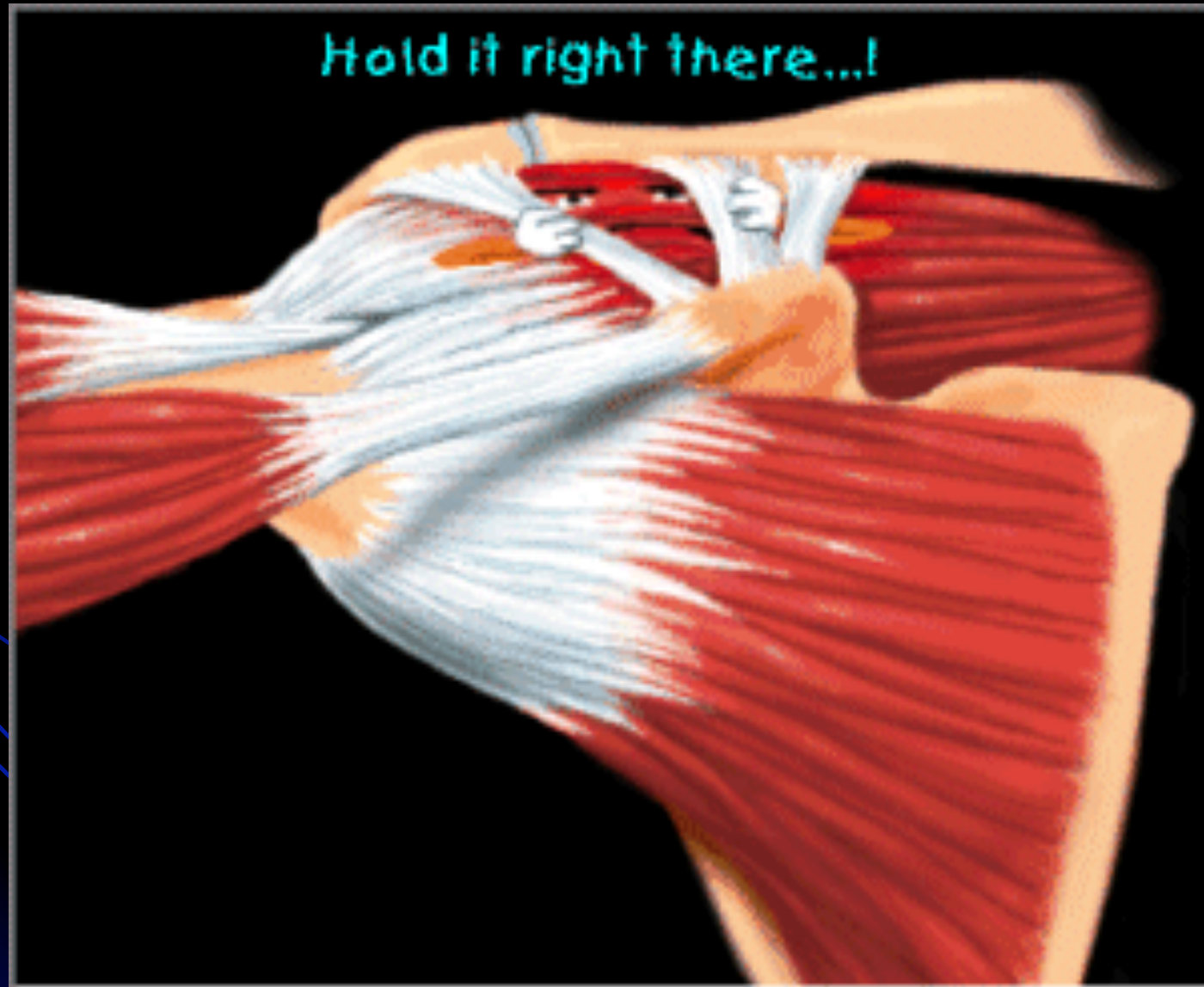- Early repair is advisable
  - 4-5" incision on side of shoulder
  - Humerus cleared
  - Holes drilled in Humerus
  - Tendon re-attached to Humerus
  - Tendons heals over time
- PT



# Rotator Cuff Tendinitis Worse Case Scenario


- Usually Torn RC is accompanied by other shoulder problems as well
  - Torn tendons have been left for while, causing muscled/tendons to “CONTRACT”, or worn away
  - Then, tendon grafts and muscle transfers, are an option
- 

# Shoulder Bursitis



# Shoulder Bursitis

- Bursitis = Inflammation of Bursa
- Bursa is a lubricated sac of tissue
- Bursa reduces friction



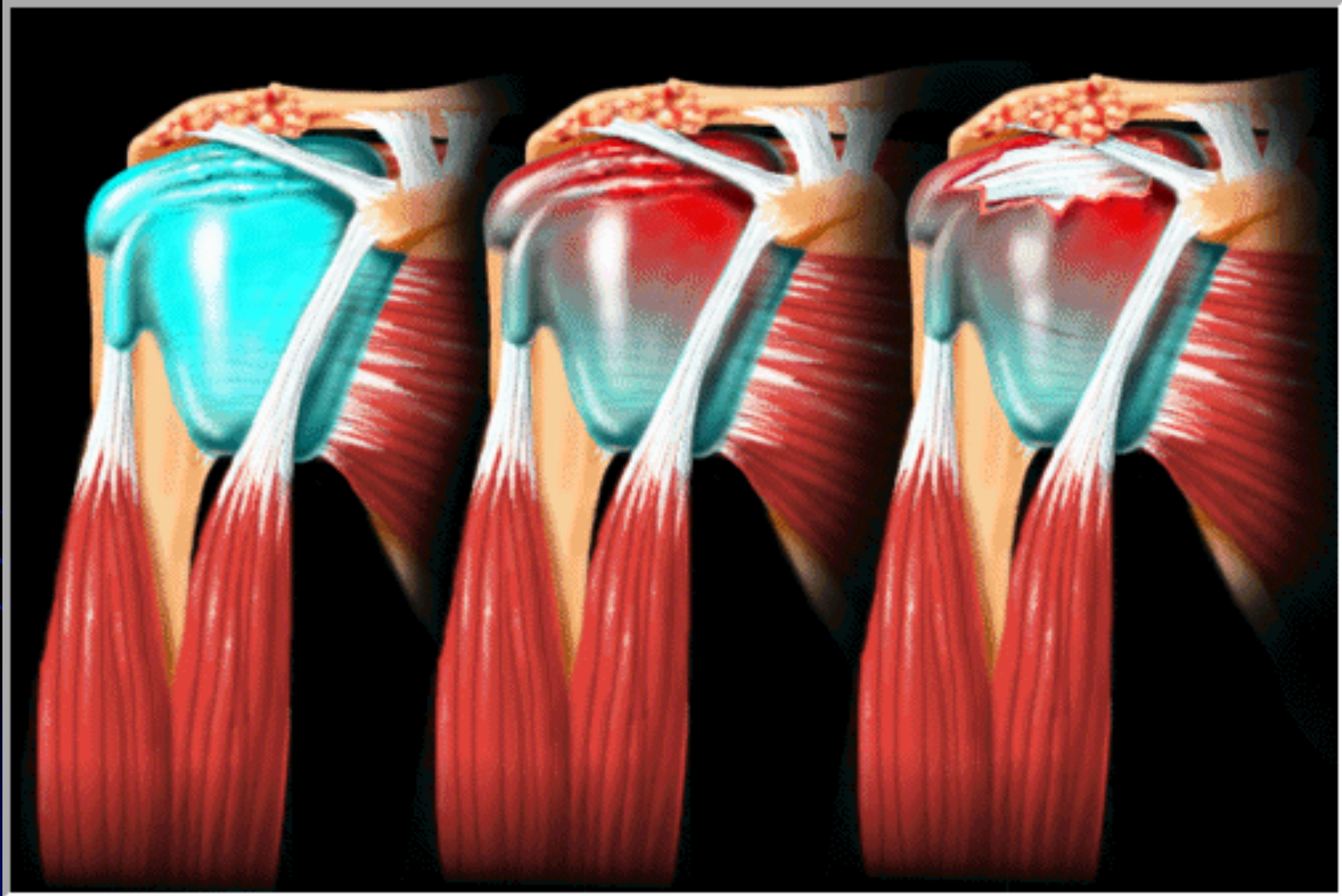
# Shoulder Bursitis -- Causes

- Each time the arm is raised, there is a bit of rubbing on the tendons and the bursa between the tendons and the Acromion.
- This rubbing, or pinching action, is called *Impingement*
- Caused by:
  - Repeated Raising of shoulders
  - A lot of overhead work
  - Repeated throwing activities
  - Repeated overuse of shoulders





# Progress of Shoulder Bursitis



# Shoulder Bursitis -- Symptoms

- Sharp pain when raising arm beside/in front of body
- Difficulty sleeping due to pain
- Reliable sign: SHARP PAIN when trying to reach into back pocket
- Stiffer joint
- Catching sensation when arm is lowered

# Shoulder Bursitis -- Diagnosis

- Physical Examination
- Arthrogram (X-Ray)
- MRI
- In some cases, pain may be coming from the neck
  - Therefore, inject a local anesthetic (like Novacaine) into bursa
  - If the pain goes away immediately after the bursa is injected with Novacaine, then most likely the pain is coming from there.

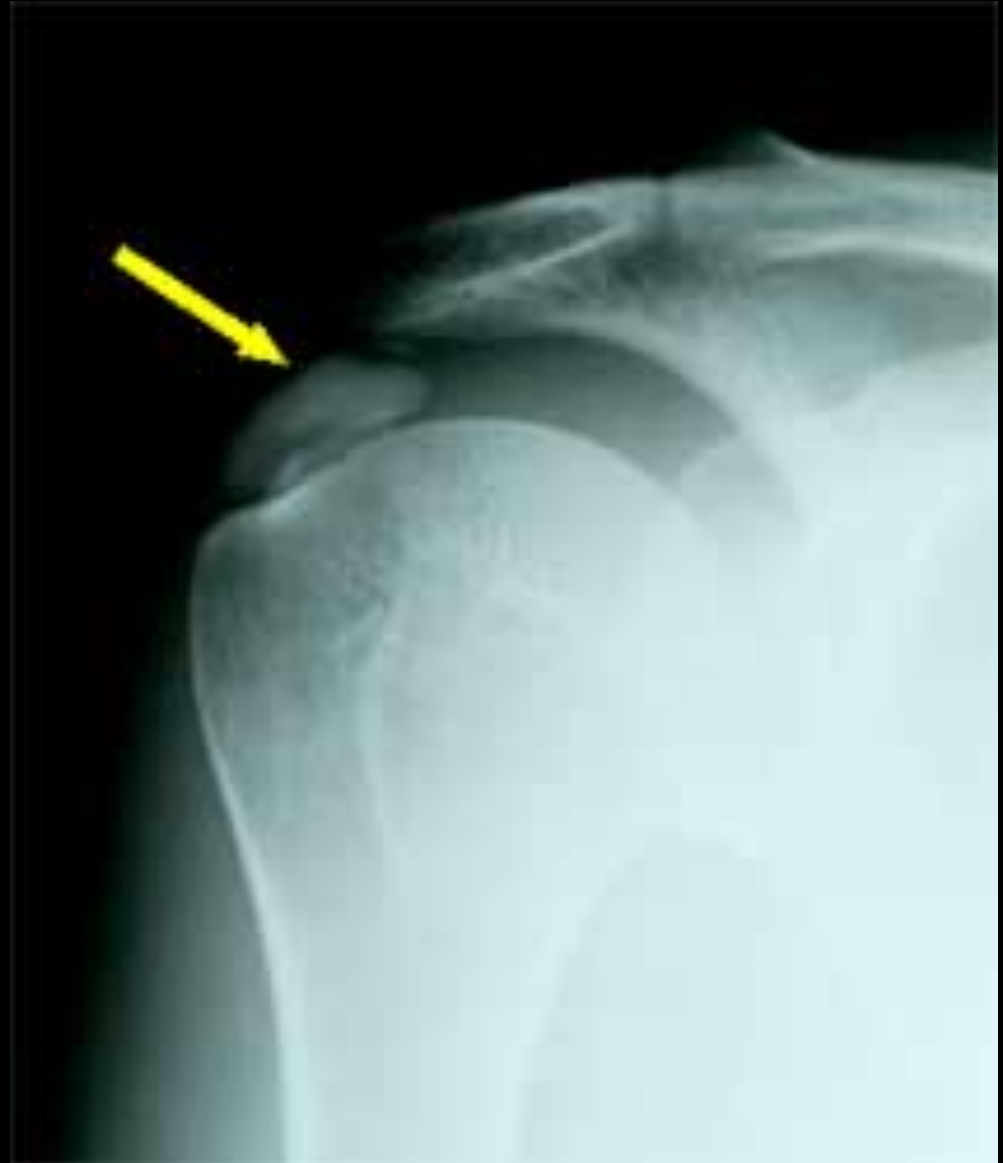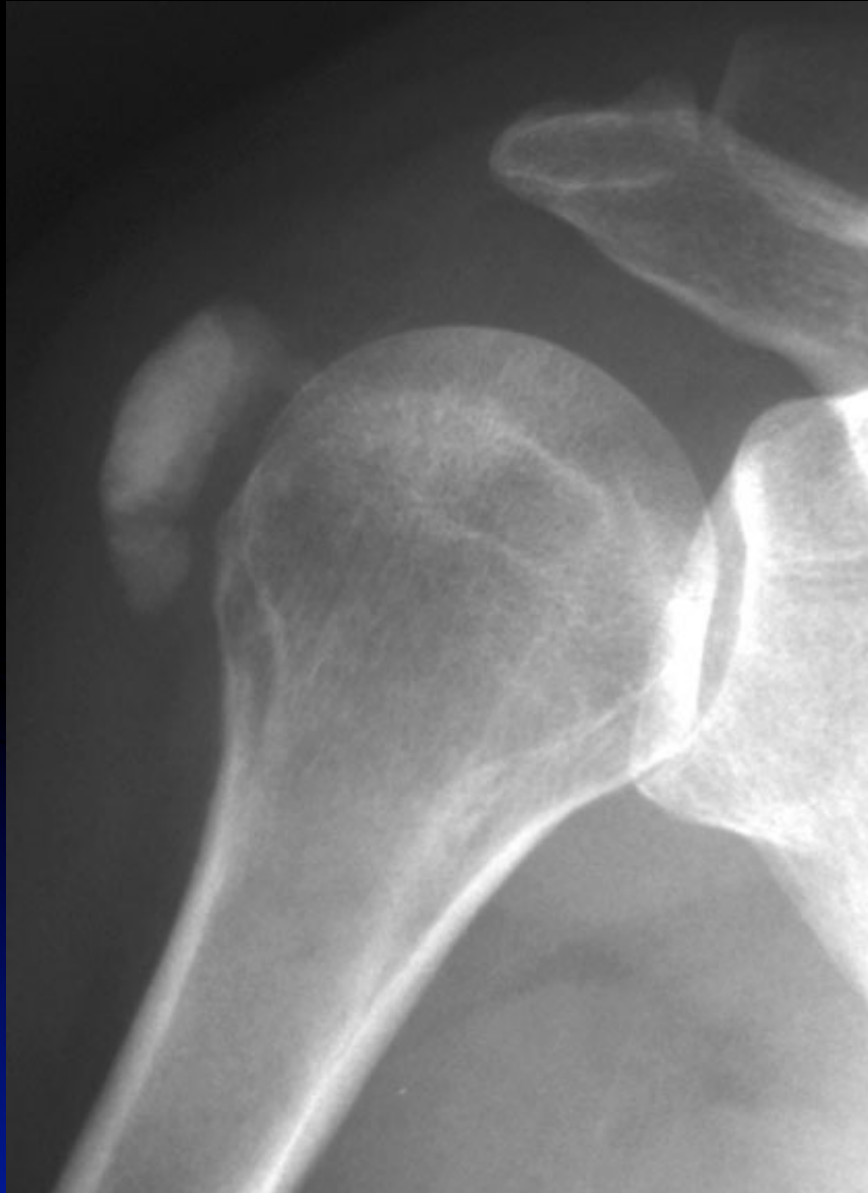
# Shoulder Bursitis – Treatment/ Prevention

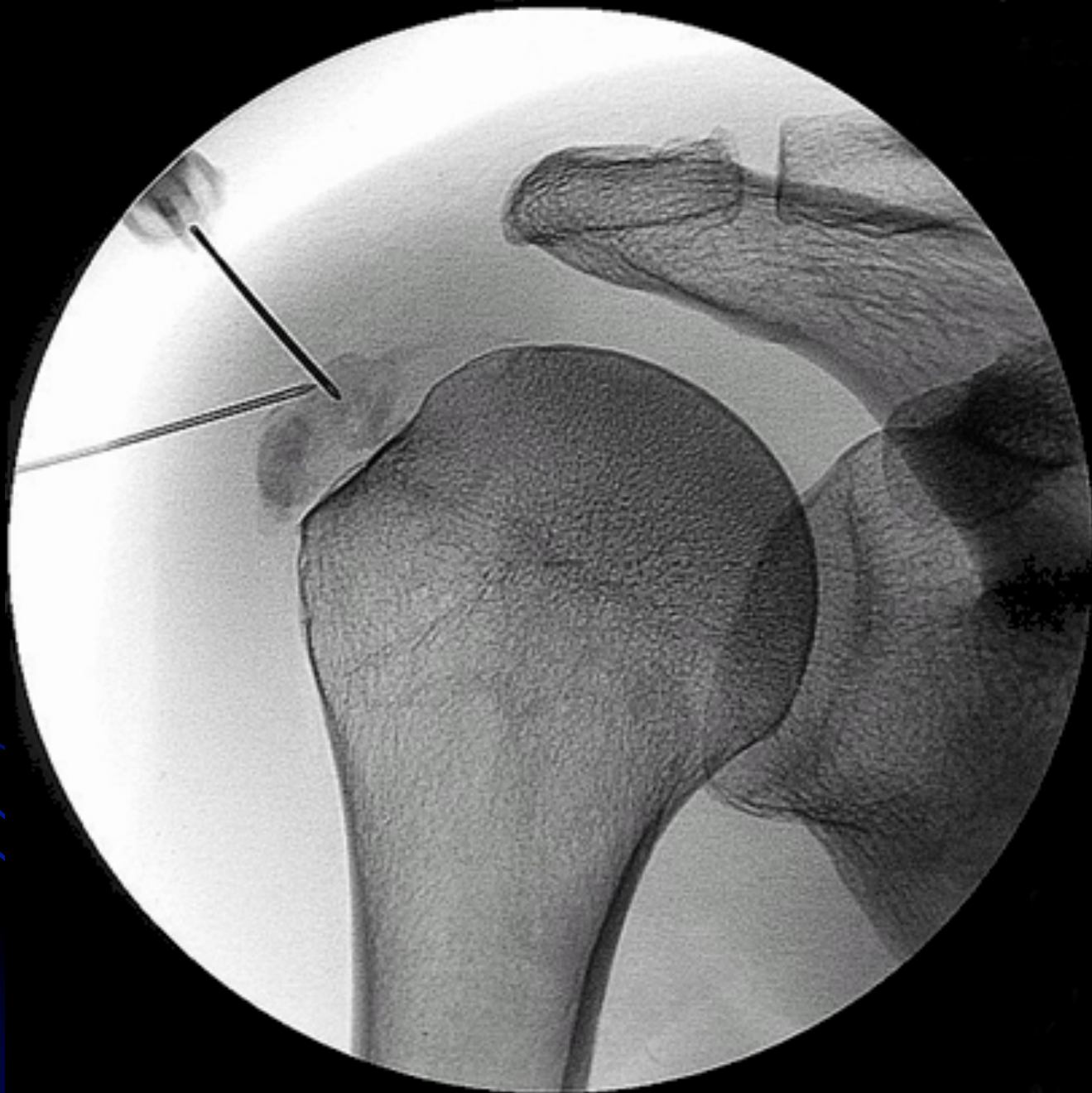- **Rest:** ie, a sling to provide adequate rest
- **Ice:**
  - Ice decreases the size of blood vessels in the sore area, halting inflammation and relieving pain.
- **Medications:**
  - Anti-inflammatory medications (These include Aspirin, Ibuprofen, an injection of cortisone, etc.)
- **Physical Therapy:**
  - Strengthening the muscles of the Rotator Cuff can actually decrease the impingement of the Acromion on the rotator cuff tendons and bursa.
- **Worksite alterations:**
  - Reduce the need for overhead activity.
  - Stretching

# Shoulder Bursitis -- Surgery

- A small part of the Acromion is removed to give the tendons more space and allow them to move without rubbing on the underside of the Acromion
- Usually an incision about 3-4" is made over the top of the shoulder
- Recovery from shoulder surgery can be a slow process.
- Physical therapy will probably be needed for several weeks after surgery.
- Expect the process of recovery to take several months.

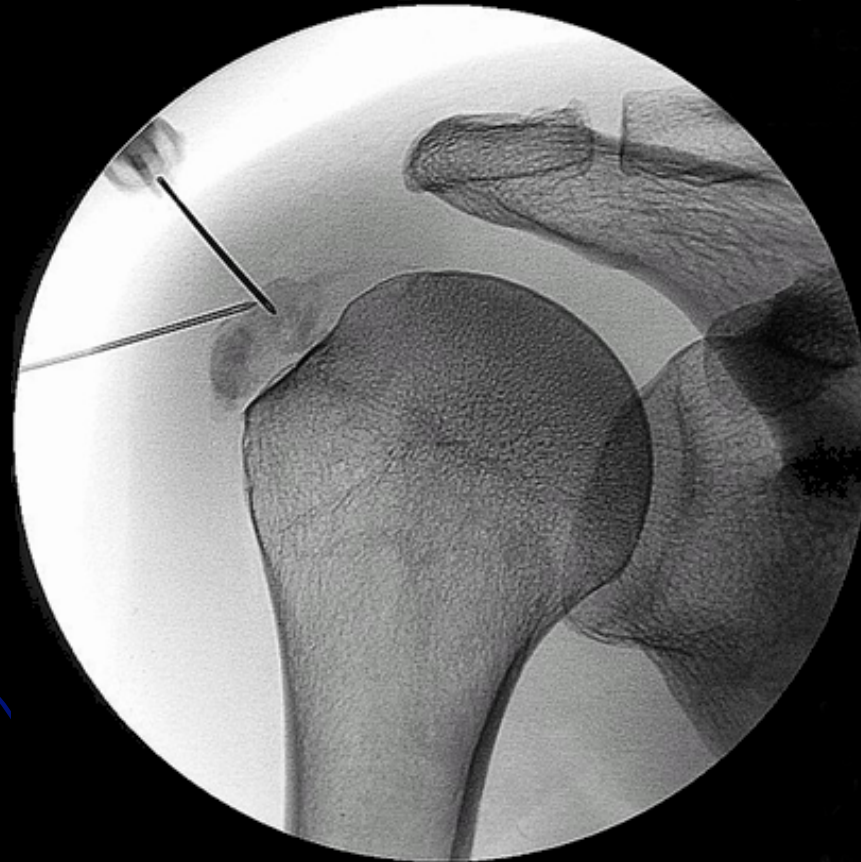# Ασβεστοποιός Τενοντίτιδα





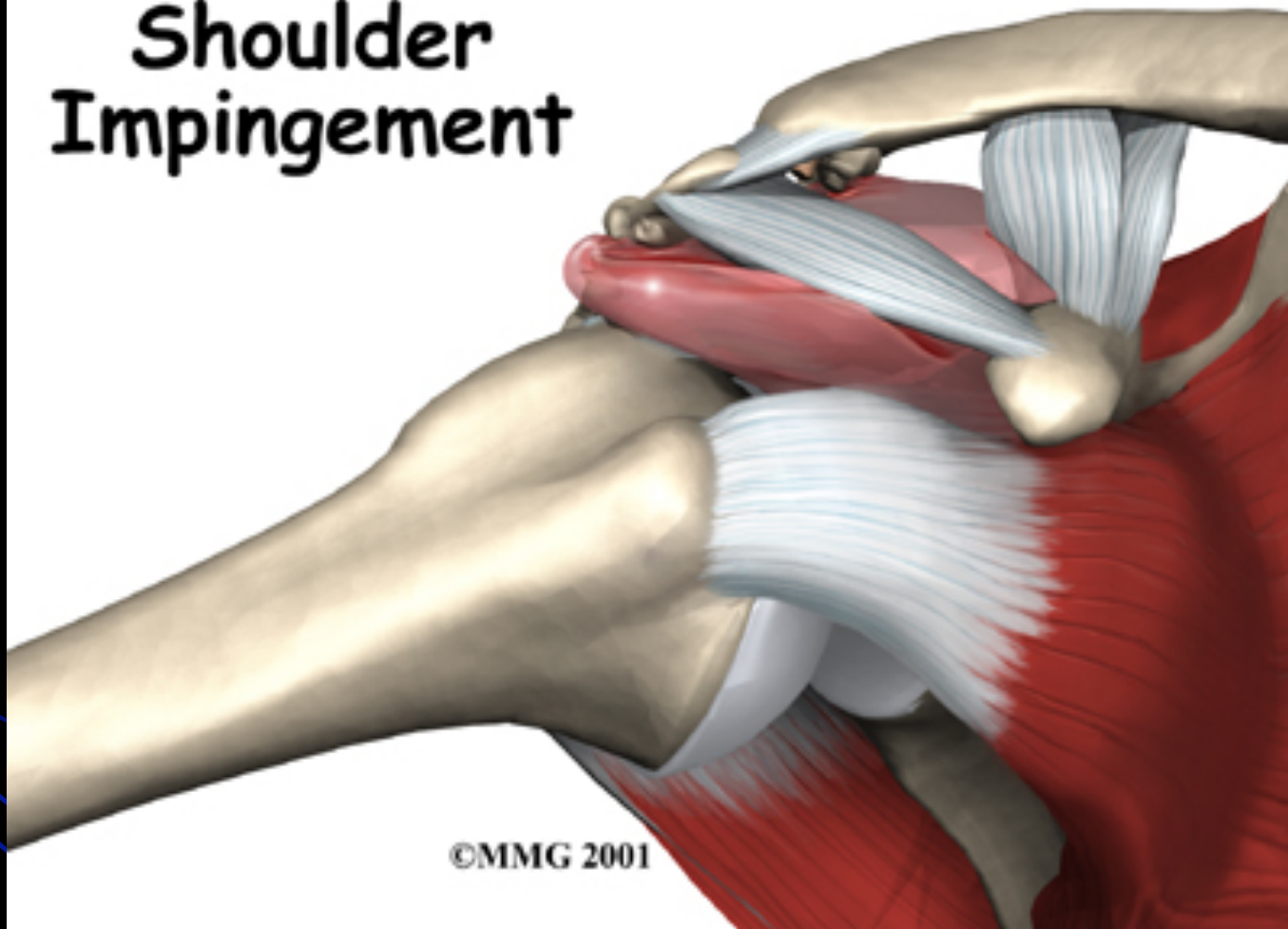
# Intratendinous tears calcifying tendinosis

- Debride and repair






# Shoulder Impingement



©MMG 2001


# Σύνδρομο Πρόσκρουσης



- Πρωτογενής πρόσκρουση
  - Δευτερογενής πρόσκρουση
  - Δευτερογενής πρόσκρουση  
επιγενείς αλλοιώσεις υπακρωμιακού χώρου
  - Οπίσθια εσωτερική πρόσκρουση
  - Πρόσθια εσωτερική πρόσκρουση
  - Πρόσκρουση κορακοειδους
- 

## Πρωτογενές Σύνδρομο Πρόσκρουσης

- Μορφολογία ακρωμίου
- Αρθρίτιδα ΑΚΑ
- Υπερτροφία ΑΚ συνδέσμου
- Πρόσκρουση κορακοειδούς απόφυσης
- Πάχυνση υπακρωμιακού θυλάκου



- Προβολή MBO
- Τραύμα (μείζον ή επαναλαμβανόμενοι μικροτραυματισμοί)
- Δραστηριότητα των άκρων πάνω από το κεφάλι  
(αθλητική και μη αθλητική)

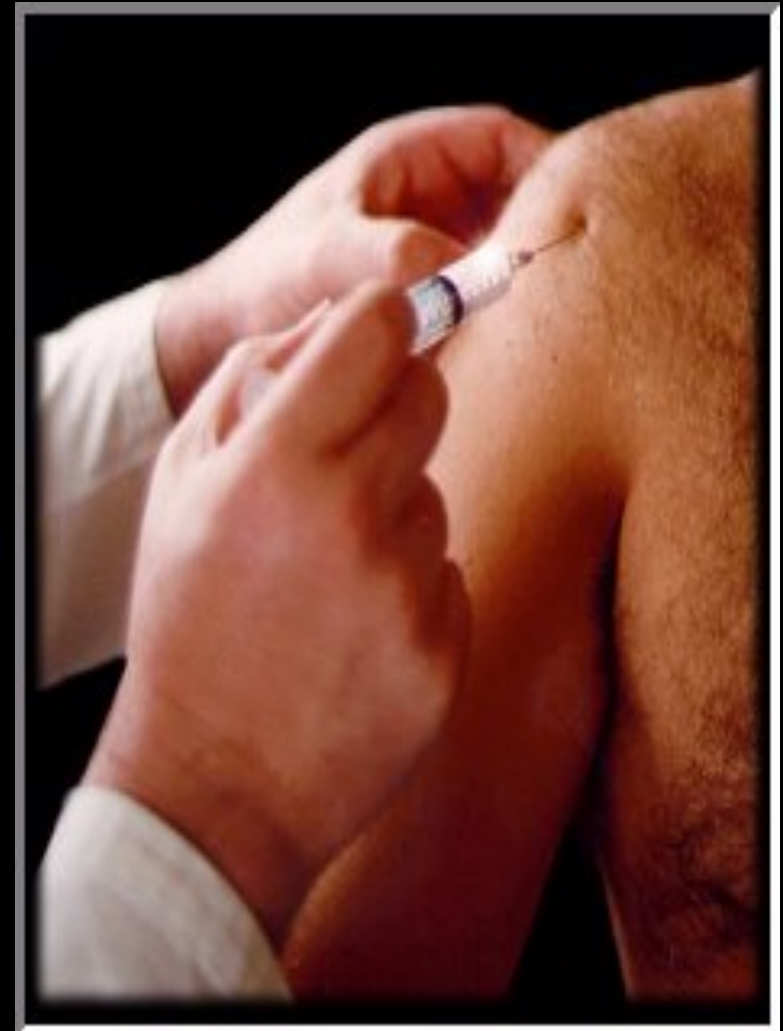## Δευτερογενές Σύνδρομο Πρόσκρουσης

- Υπερφόρτιση στροφών- ανισορροπία μαλακών μορίων
- Έκκεντρη καταπόνηση μυών και κόπωση
- Χαλάρωση-αστάθεια γληνοβραχιόνιας άρθρωσης
- Αδυναμία μακράς κεφαλής δικεφάλου
- Βλάβες επιχείλιου χόνδρου
- Δυσκινησία Ωμοπλάτης
- Ρίκνωση οπίσθιου θυλάκου  
(παρεκτόπιση της κεφαλής προς τα πάνω)
- Παράλυση τραπεζοειδούς μυός

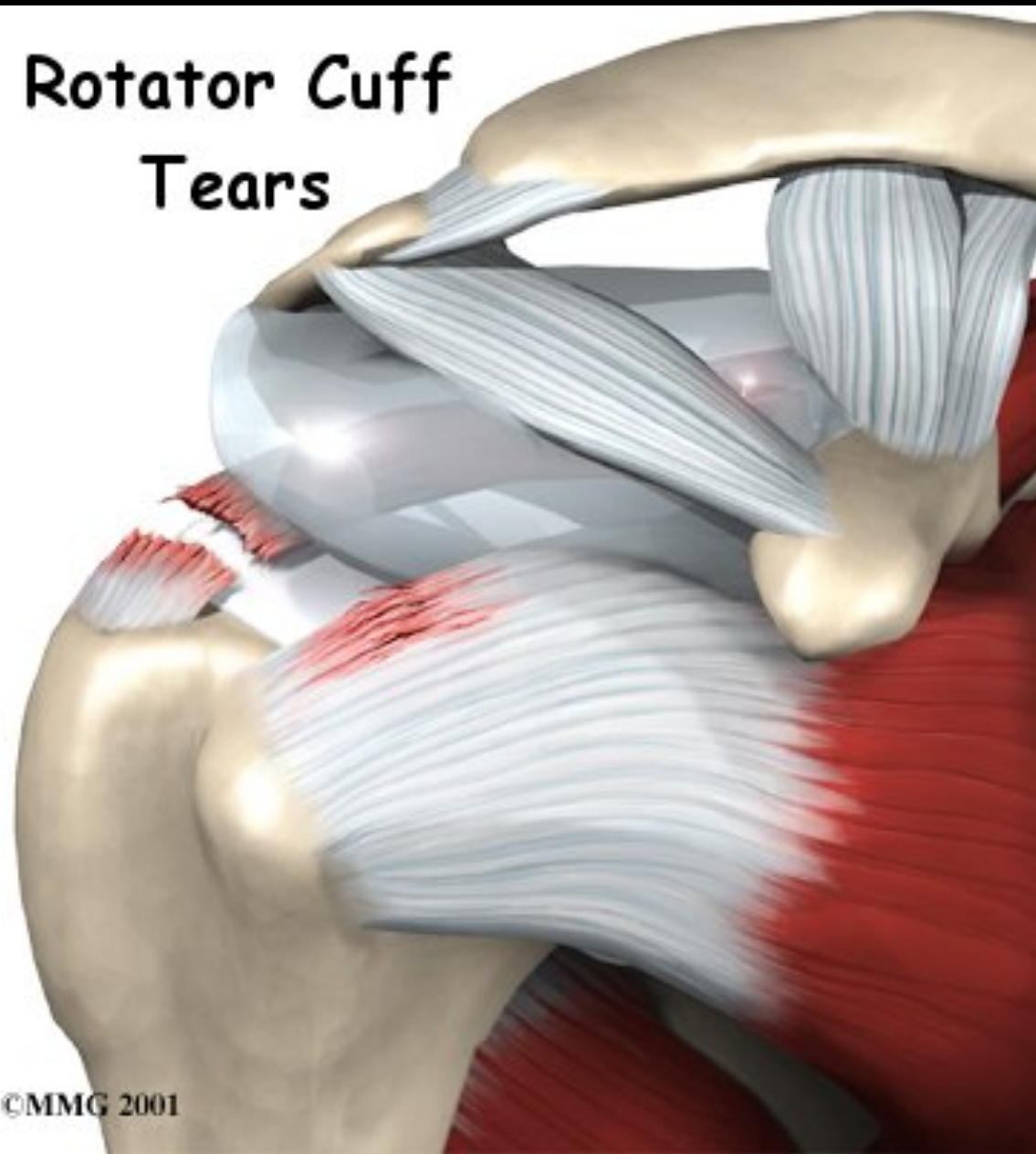


# Τενοντίτιδα του Τενοντίου Πετάλου

- Ανάπαυση
  - Αντιφλεγμονώδη
  - Φυσικοθεραπεία
  - Κορτιζόνη
- 
- Μερικές ρήξεις μπορεί να είναι ασυμπτωματικές
  - Οι πλήρεις ρήξεις δεν επουλώνονται



# Rotator Cuff Tears



©MMG 2001

Οι ρήξεις του τενοντίου πετάλου διαγιγνώσκονται:

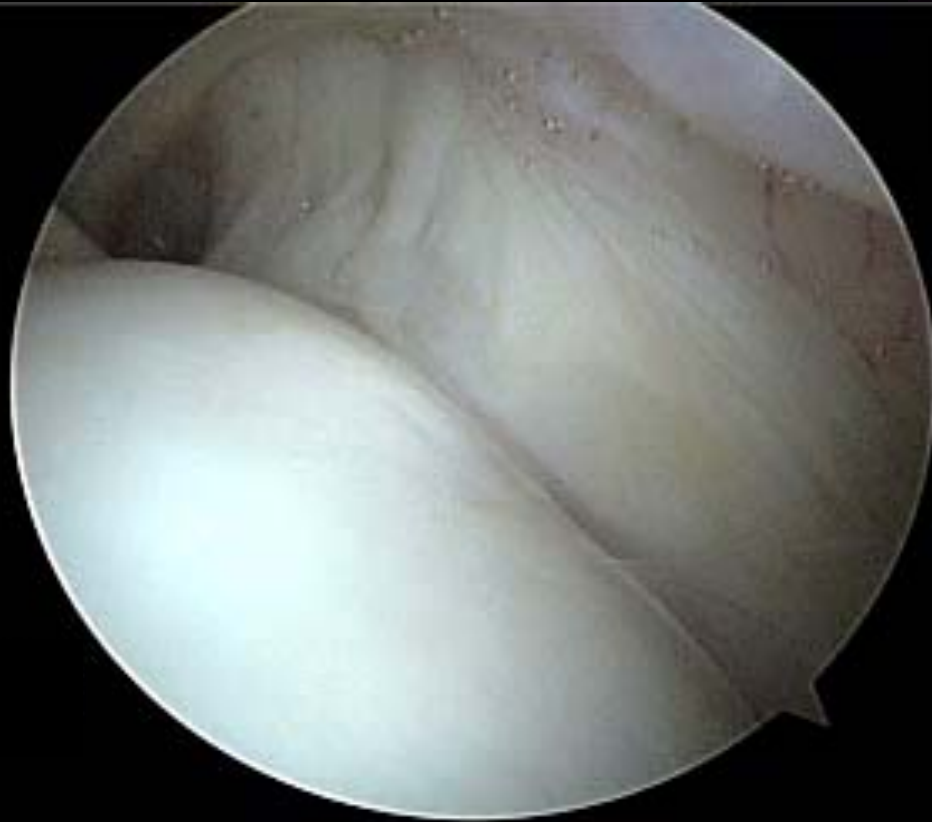1. Κλινικά
2. Με απεικονιστικό έλεγχο

Υπερηχογράφημα - Μαγνητική Τομογραφία

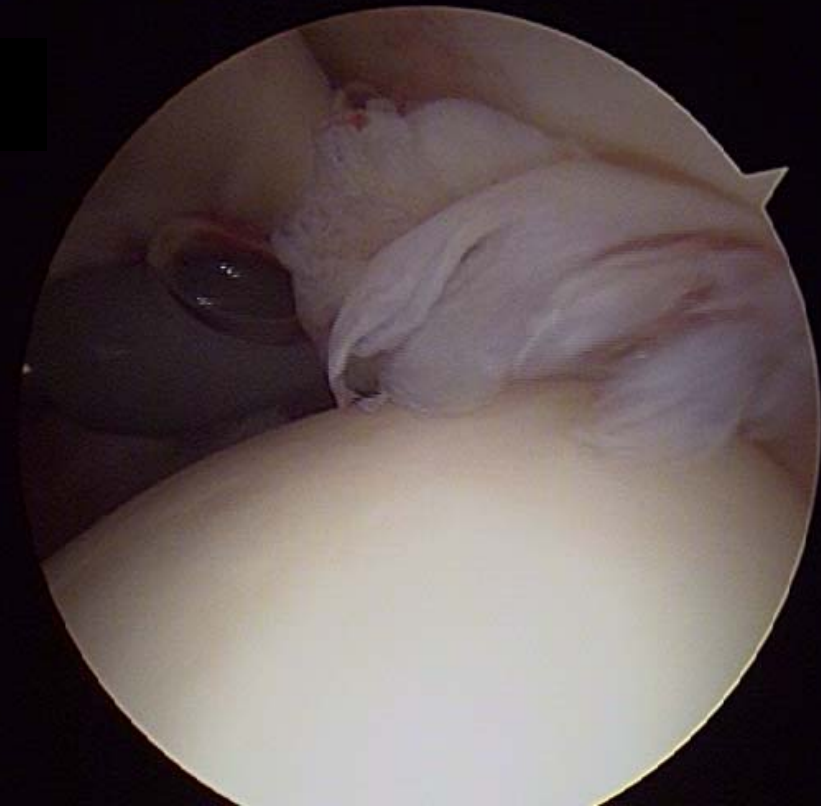



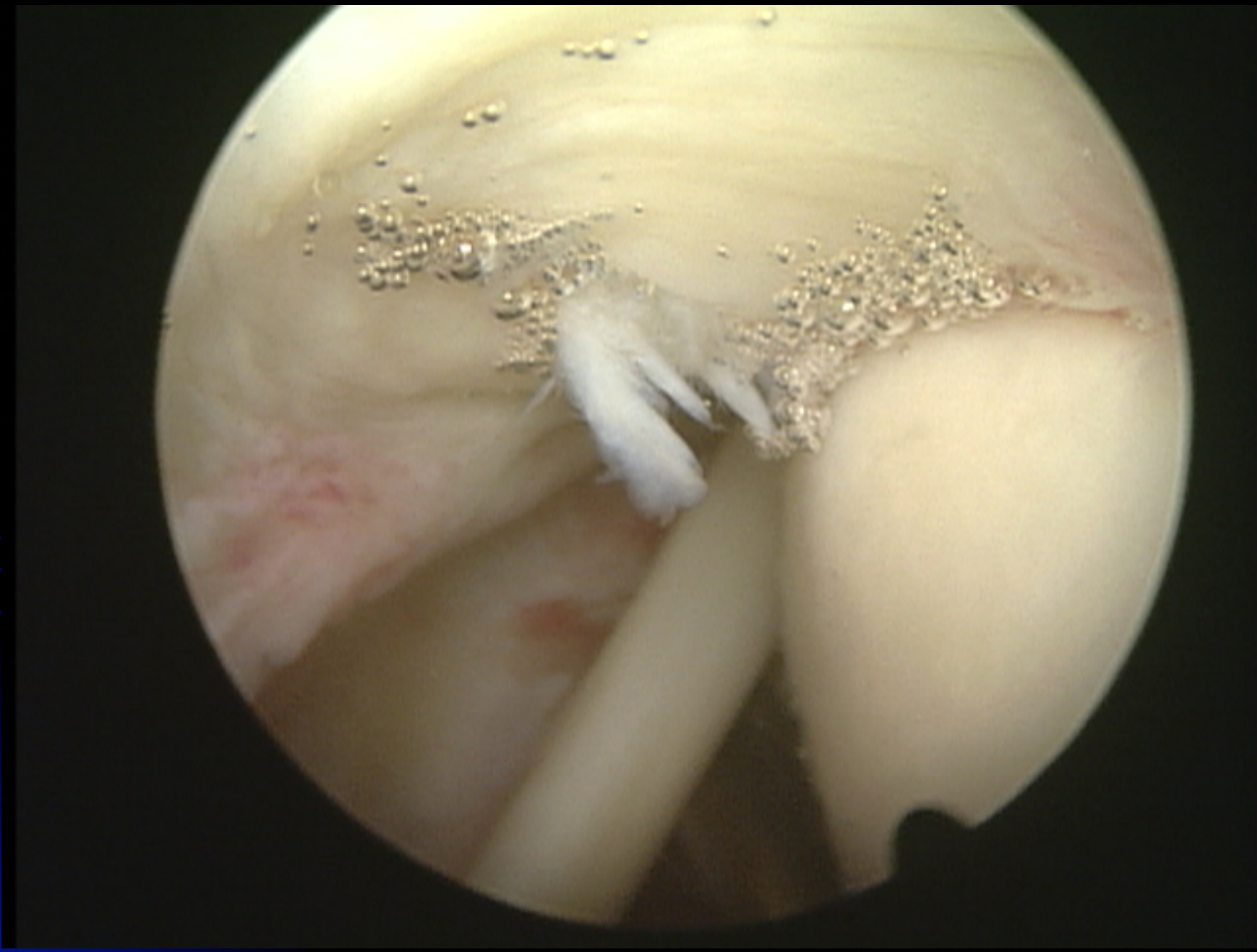**Normal  
Supraspinatus  
Attachment**

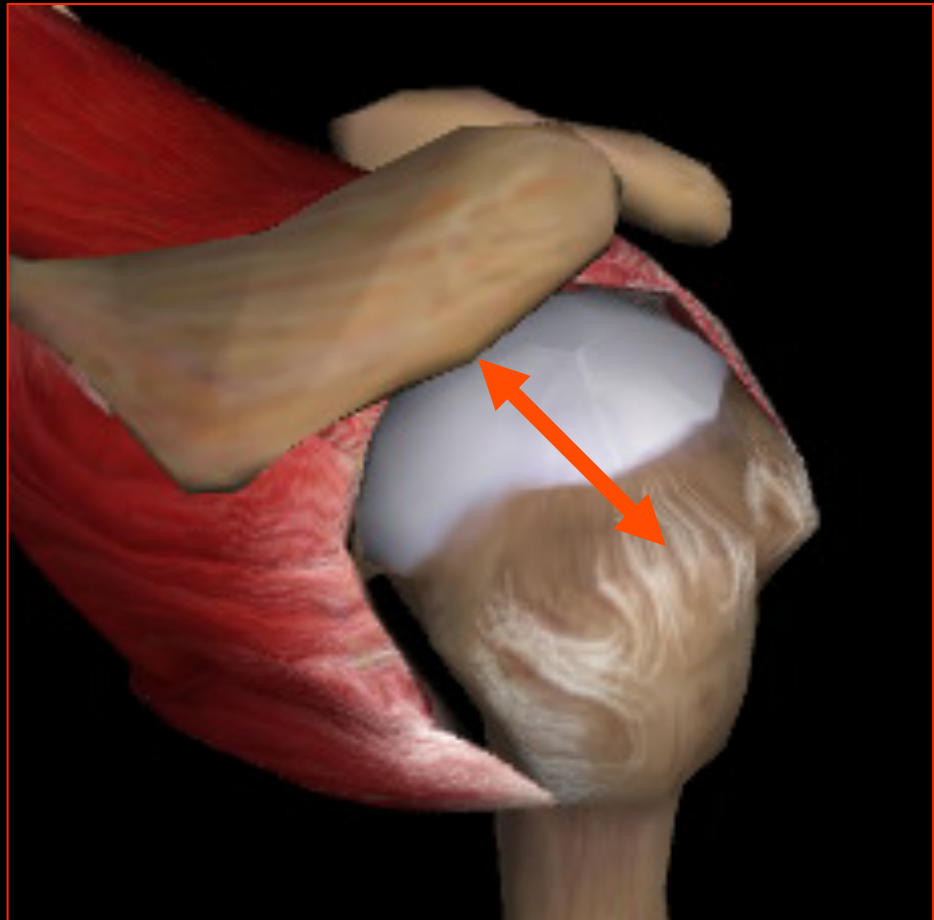
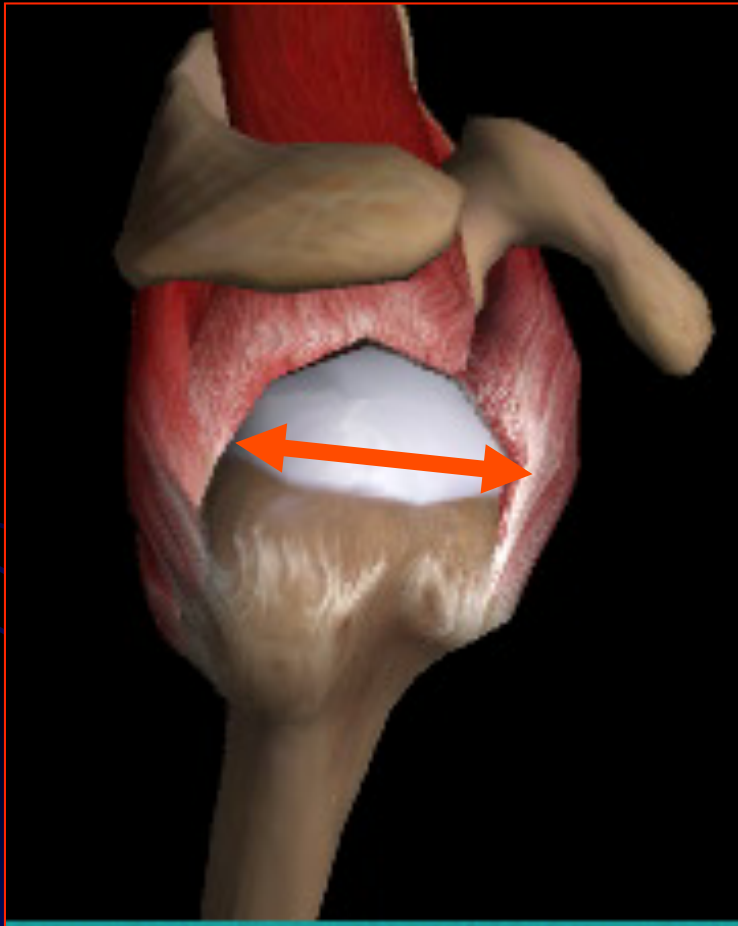


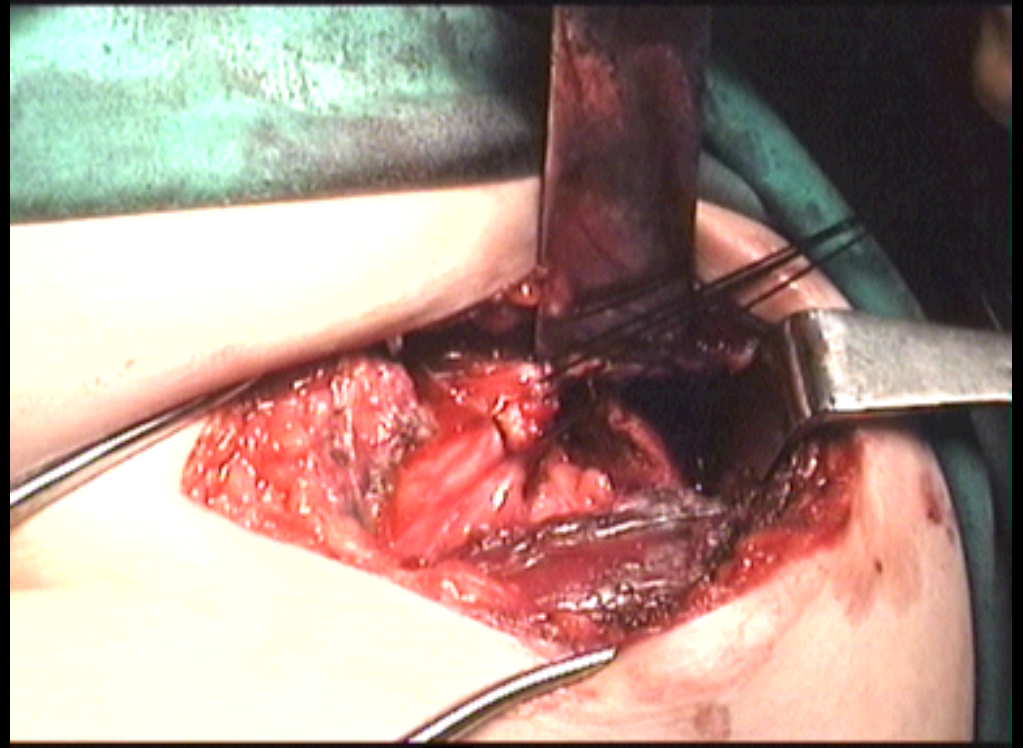
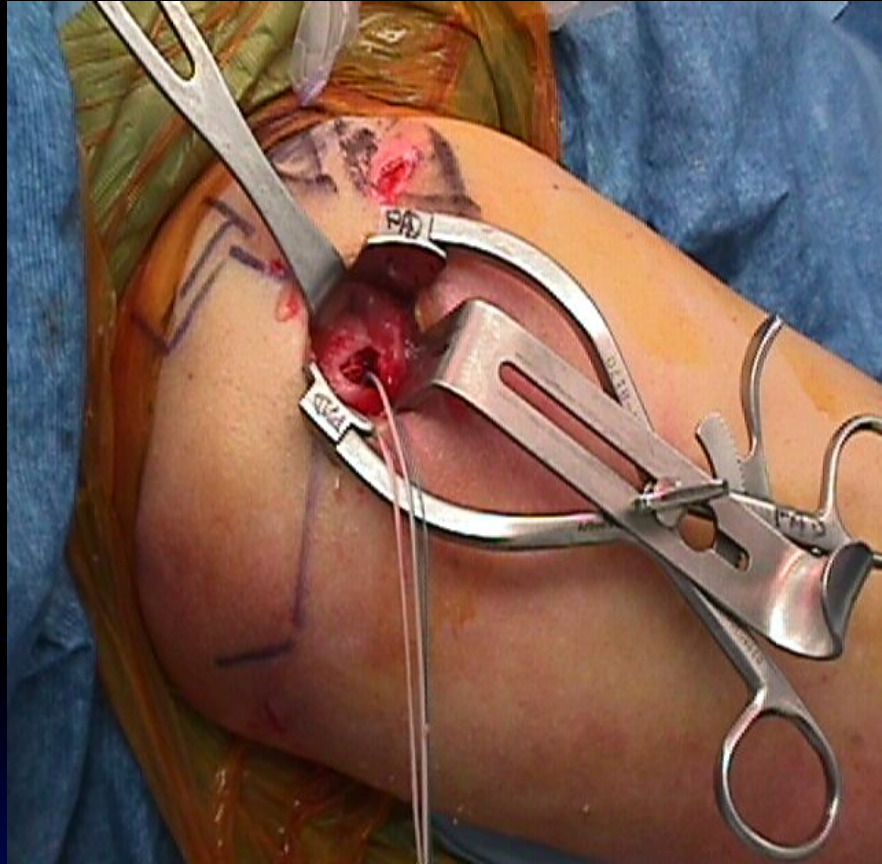
**Partial Articular  
Surface Tear**

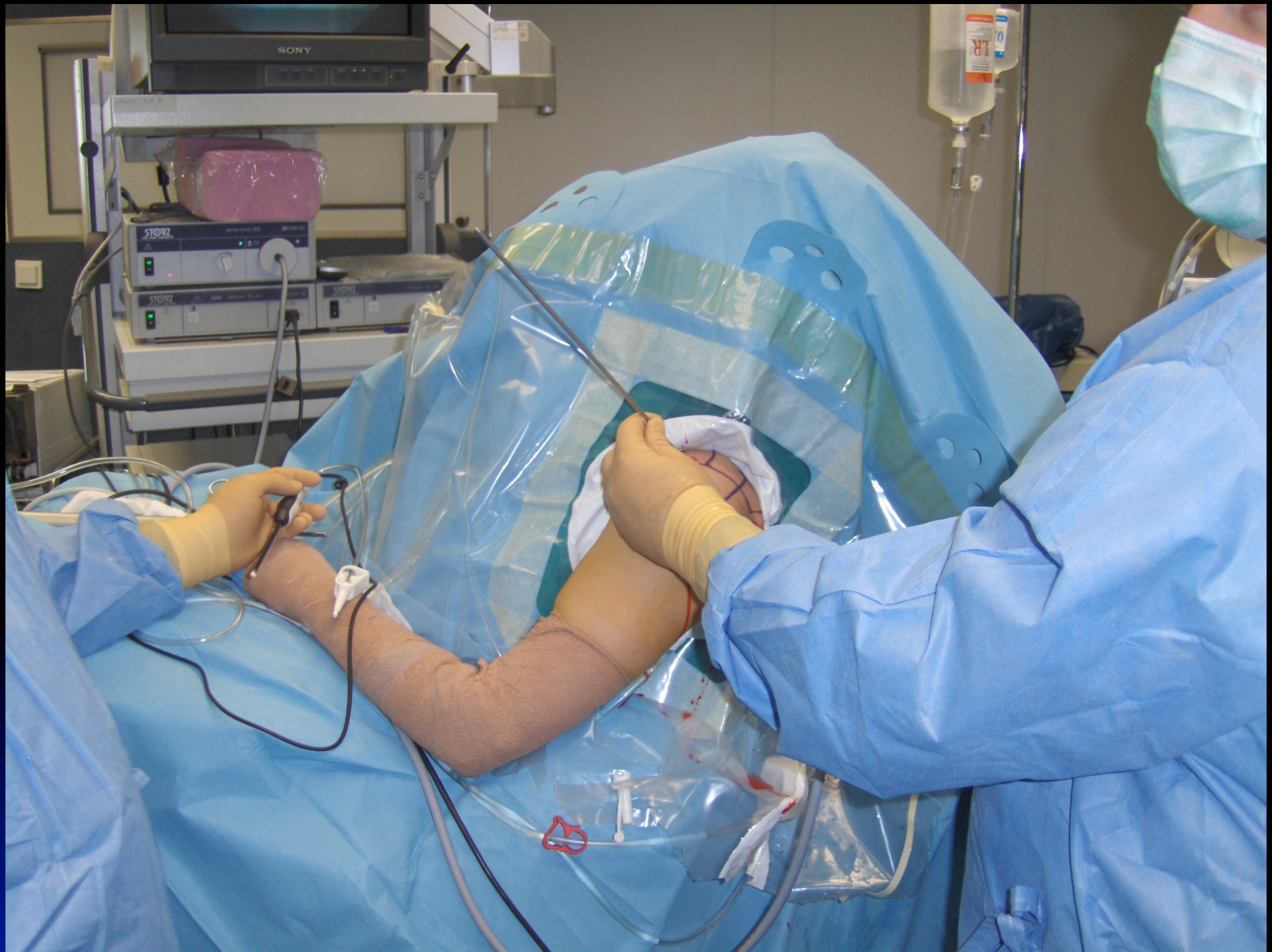

## Partial Articular Surface Tear

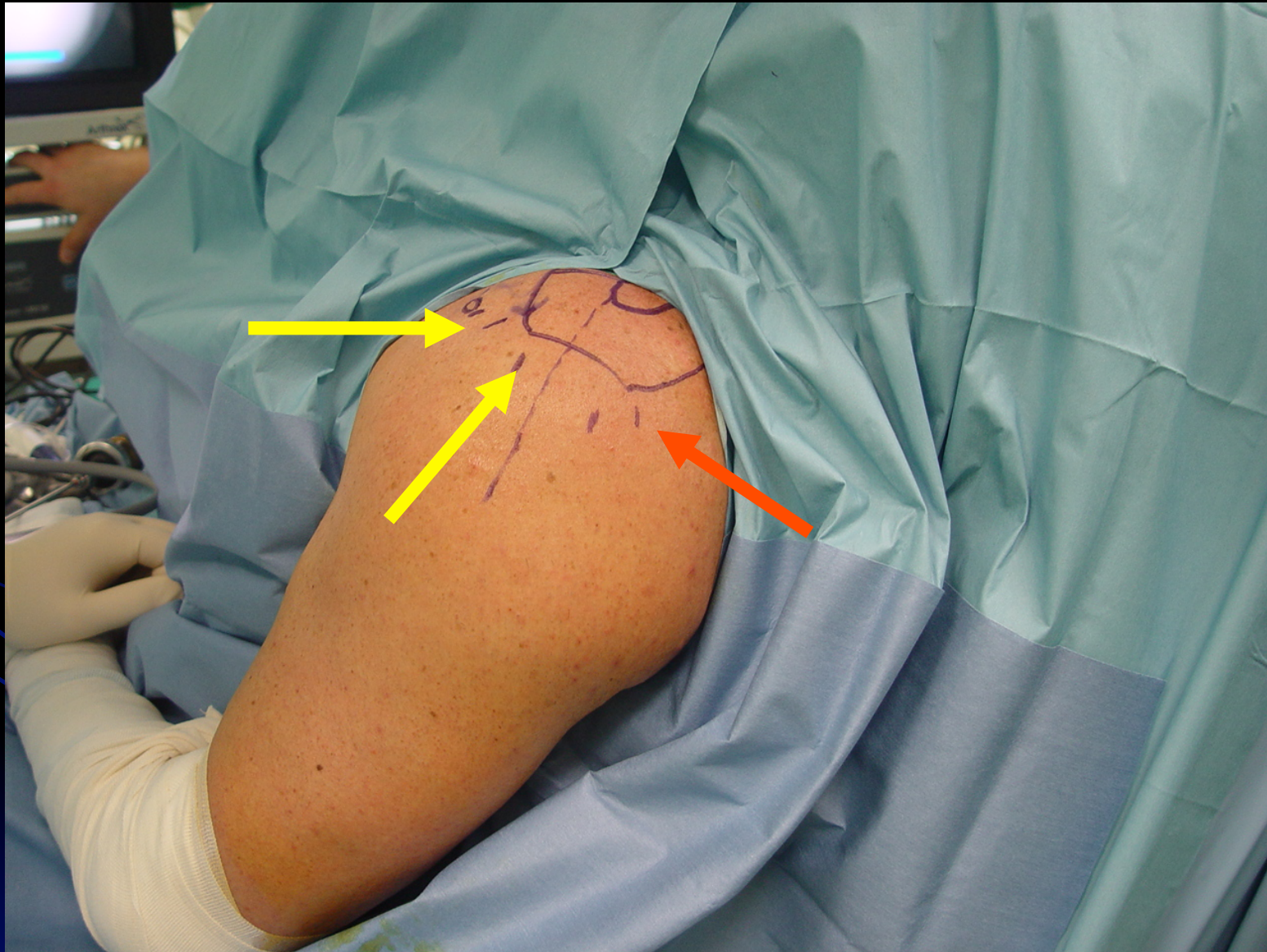


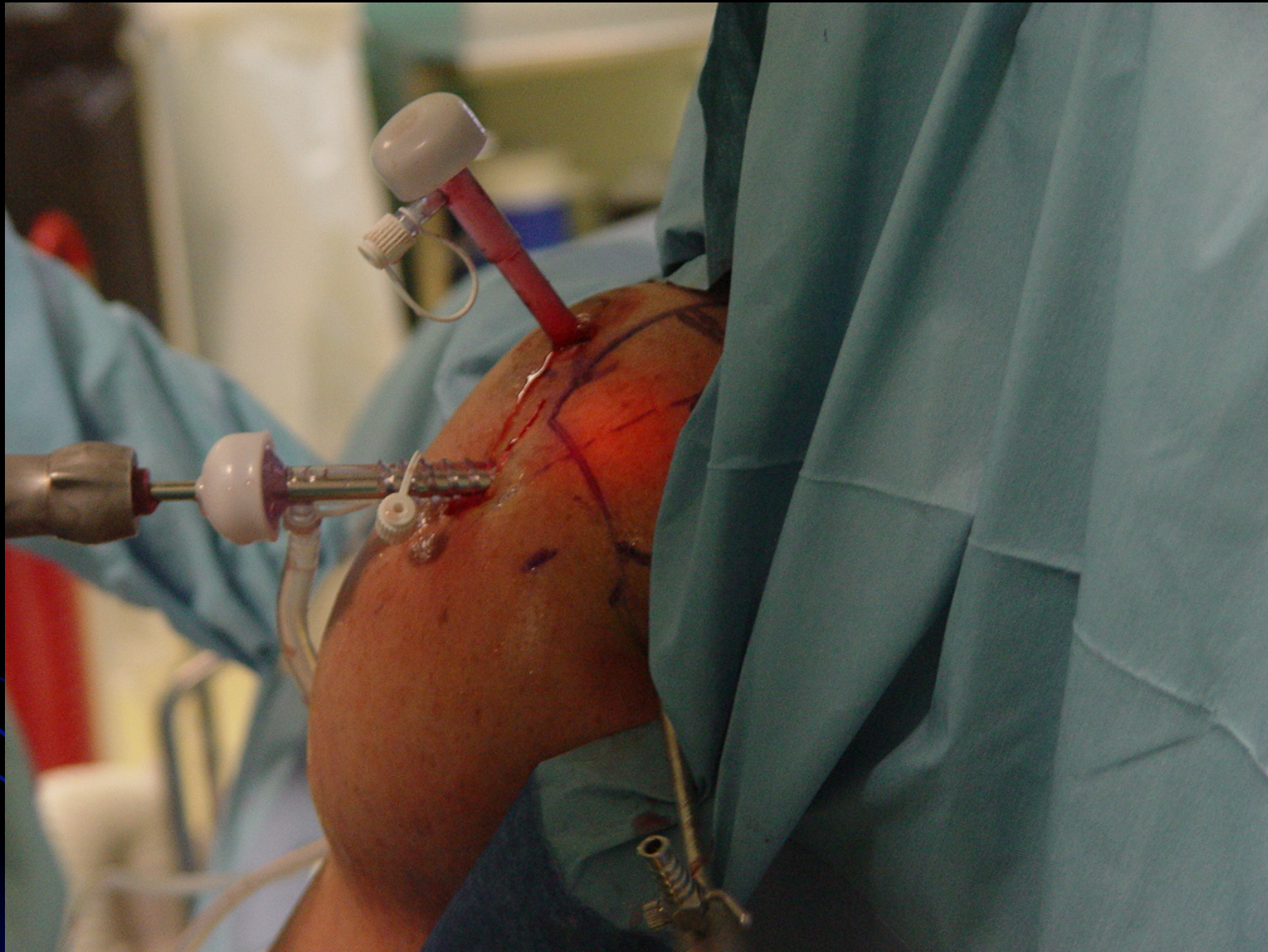




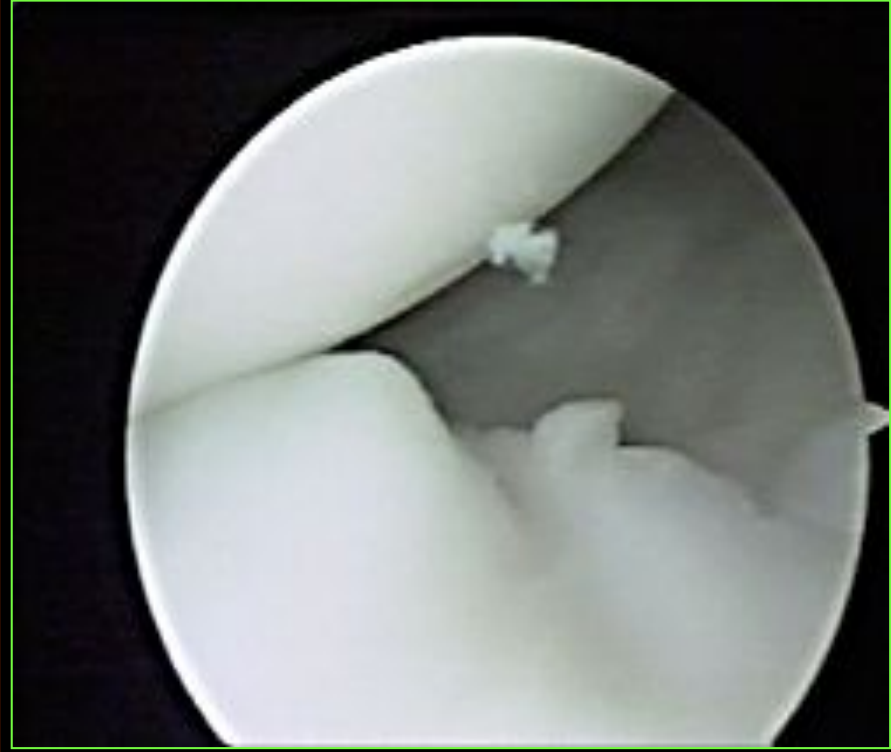


# Portals



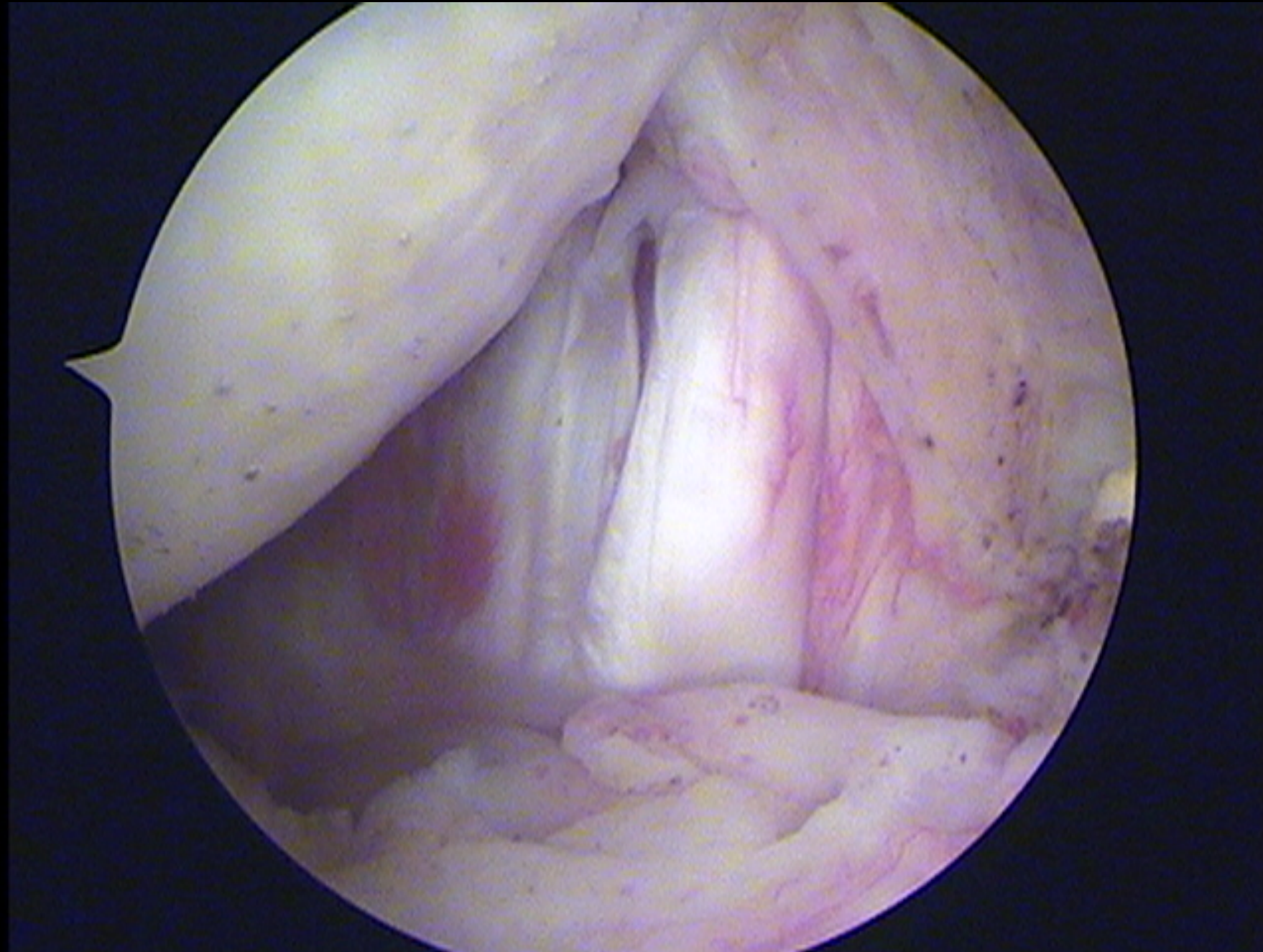


# Bleeding Control

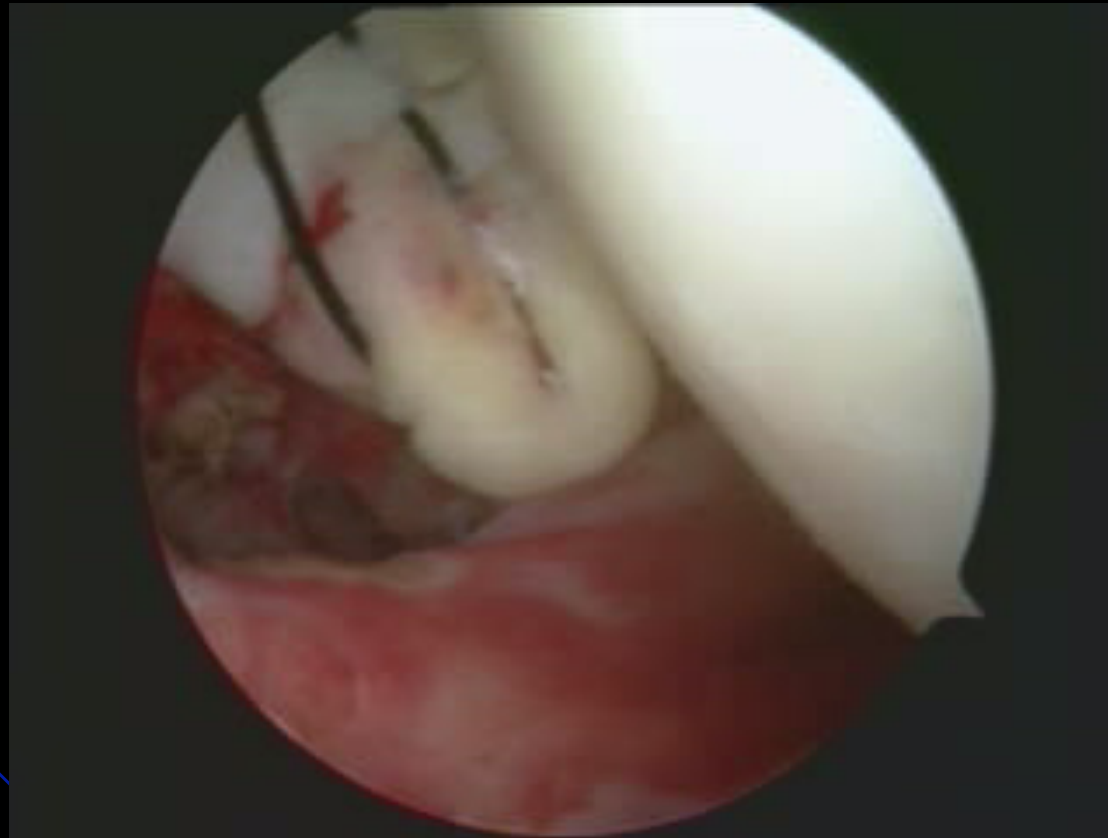


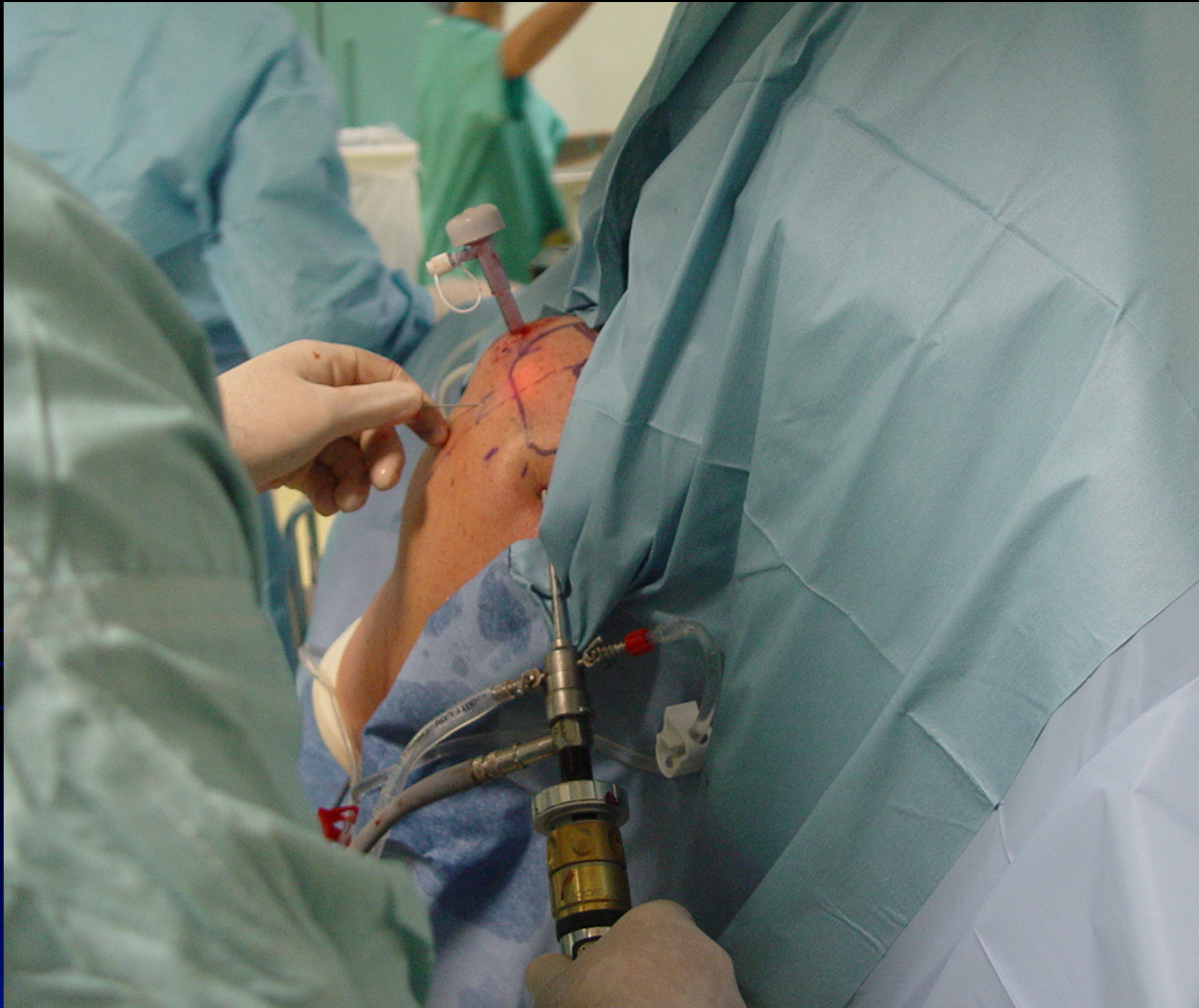
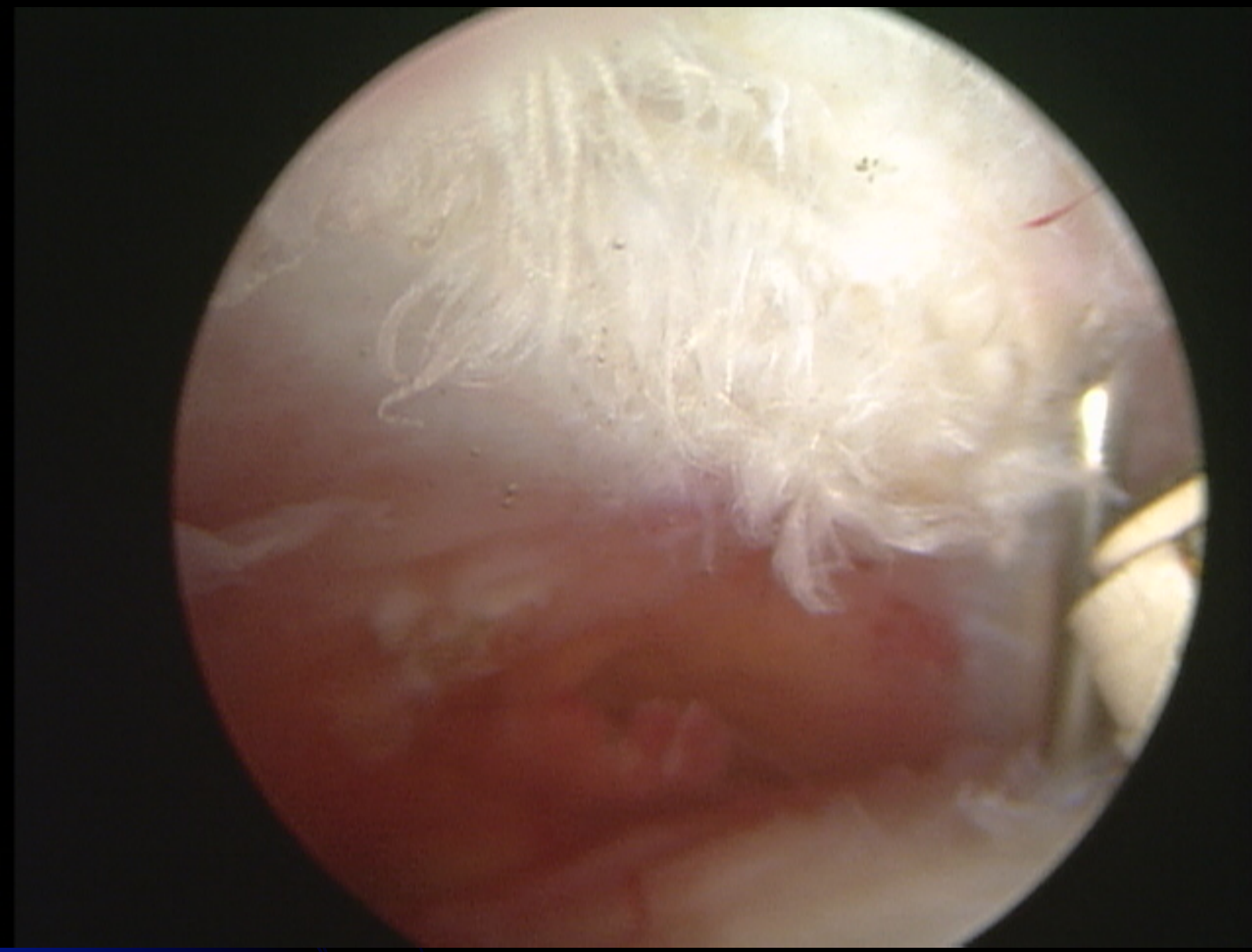
# Subscapularis Tear



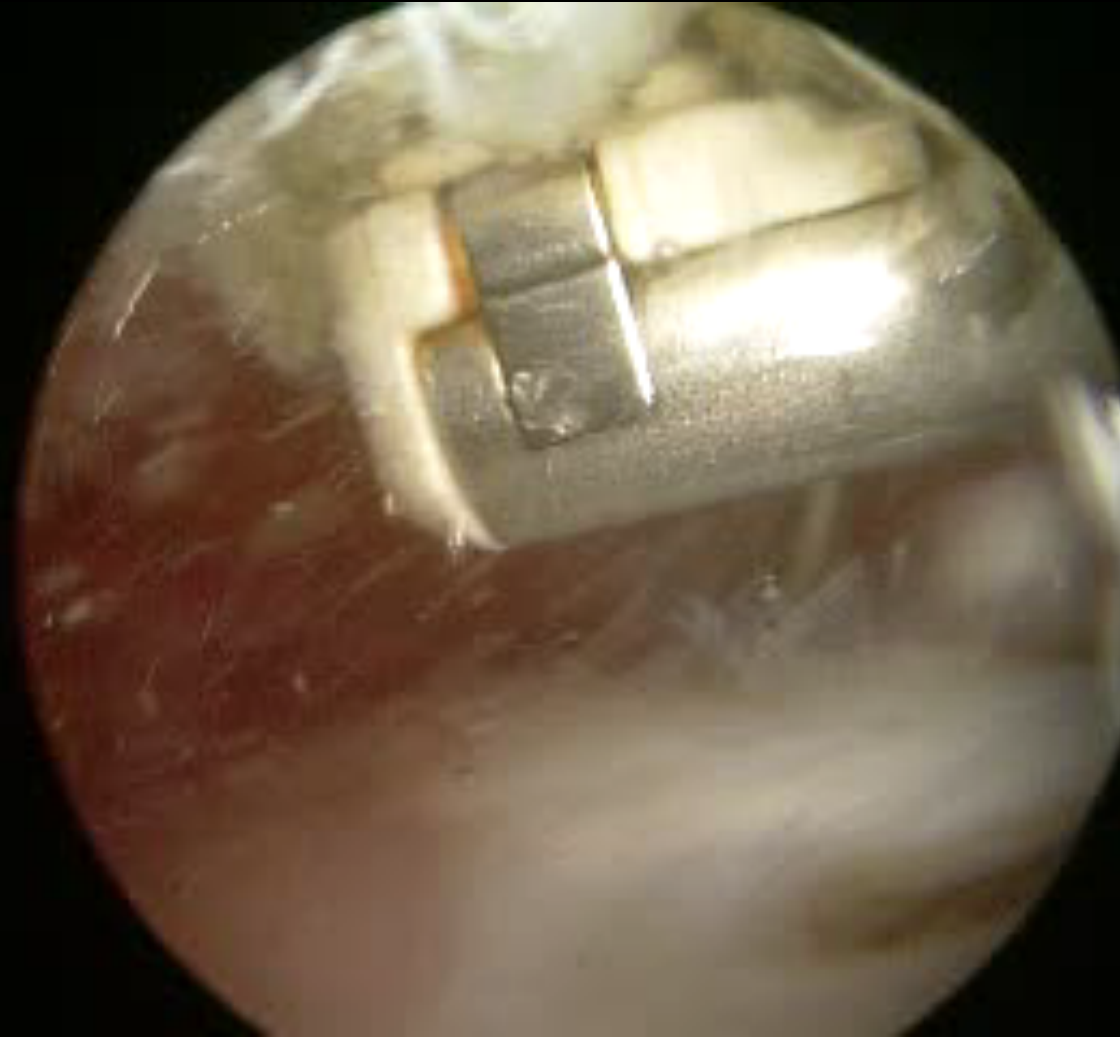## Subscapularis Tear



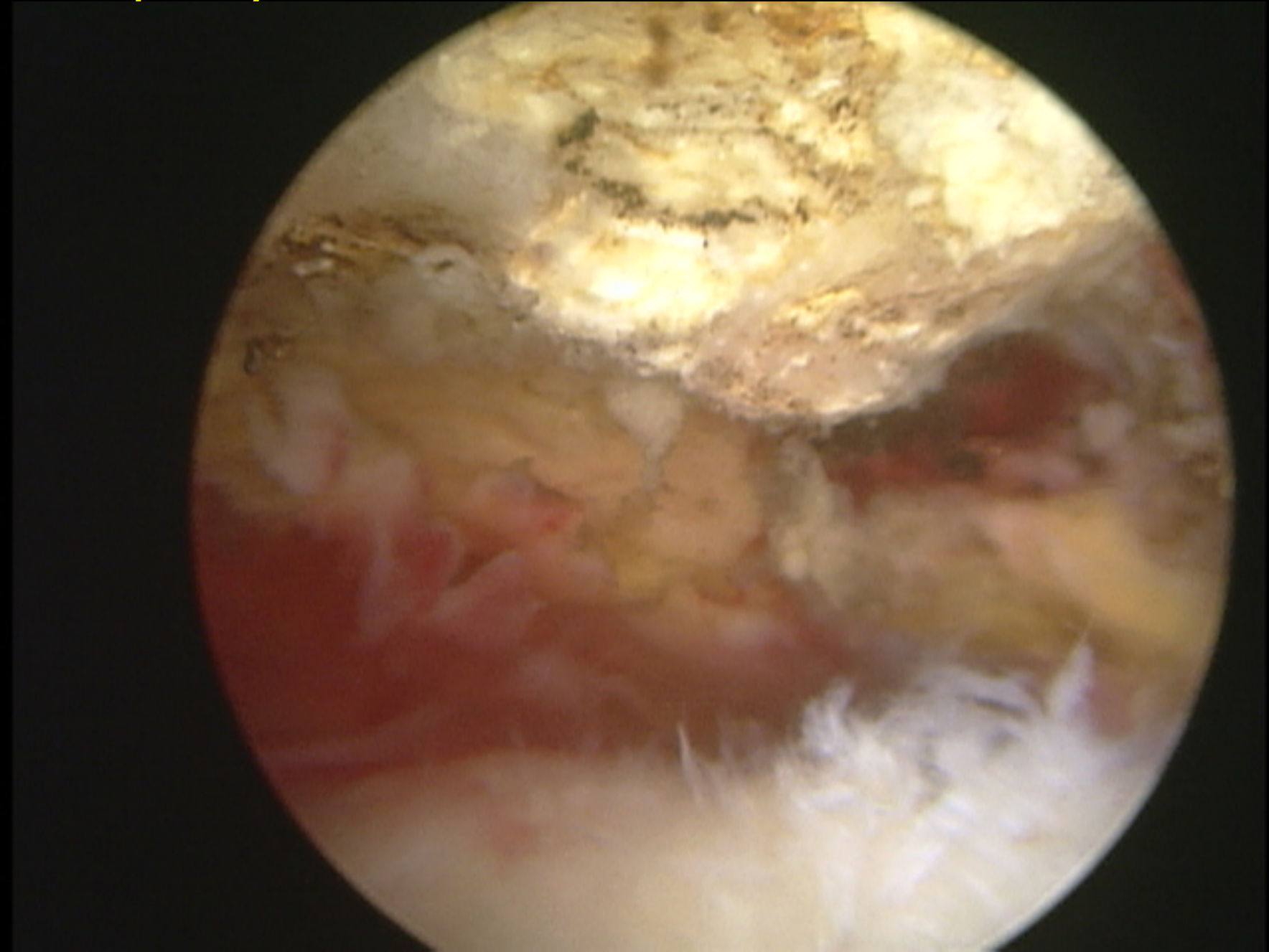




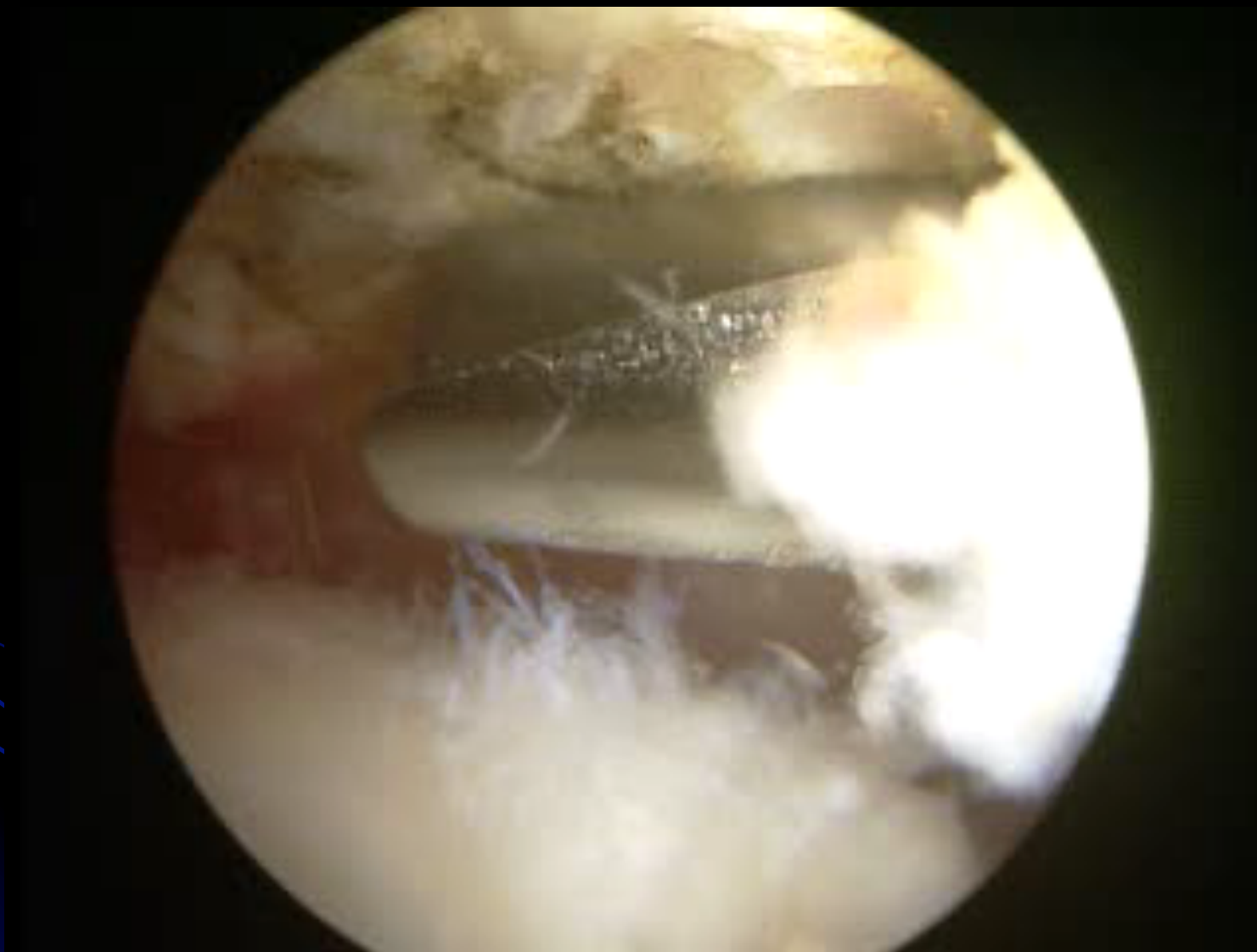
# Acromioplasty


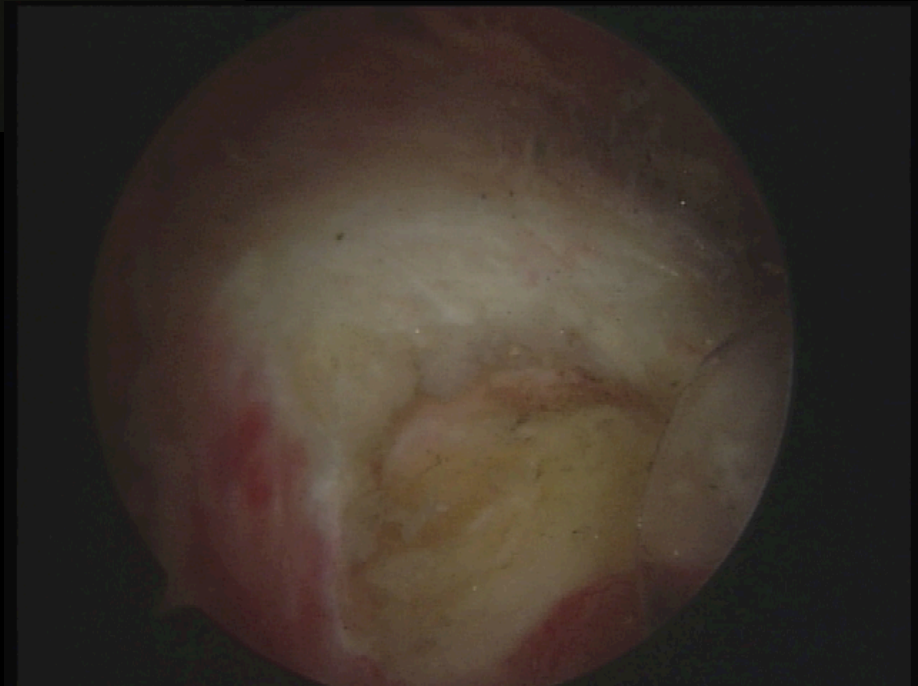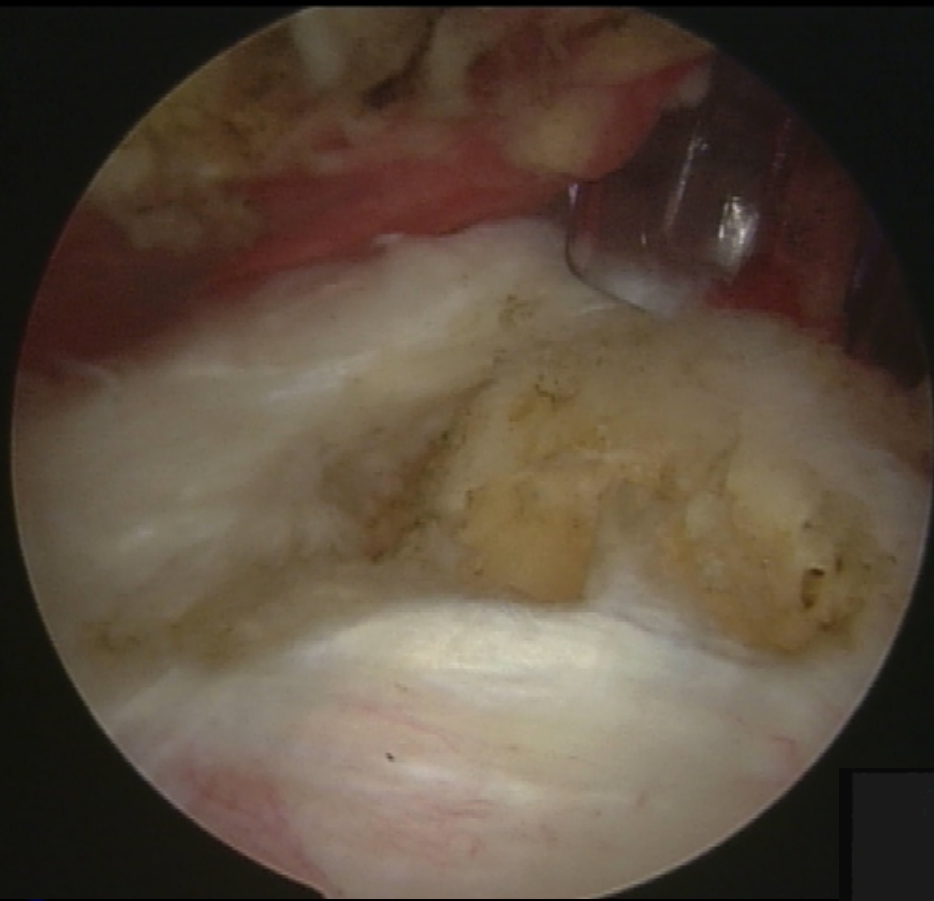


# Acromioplasty



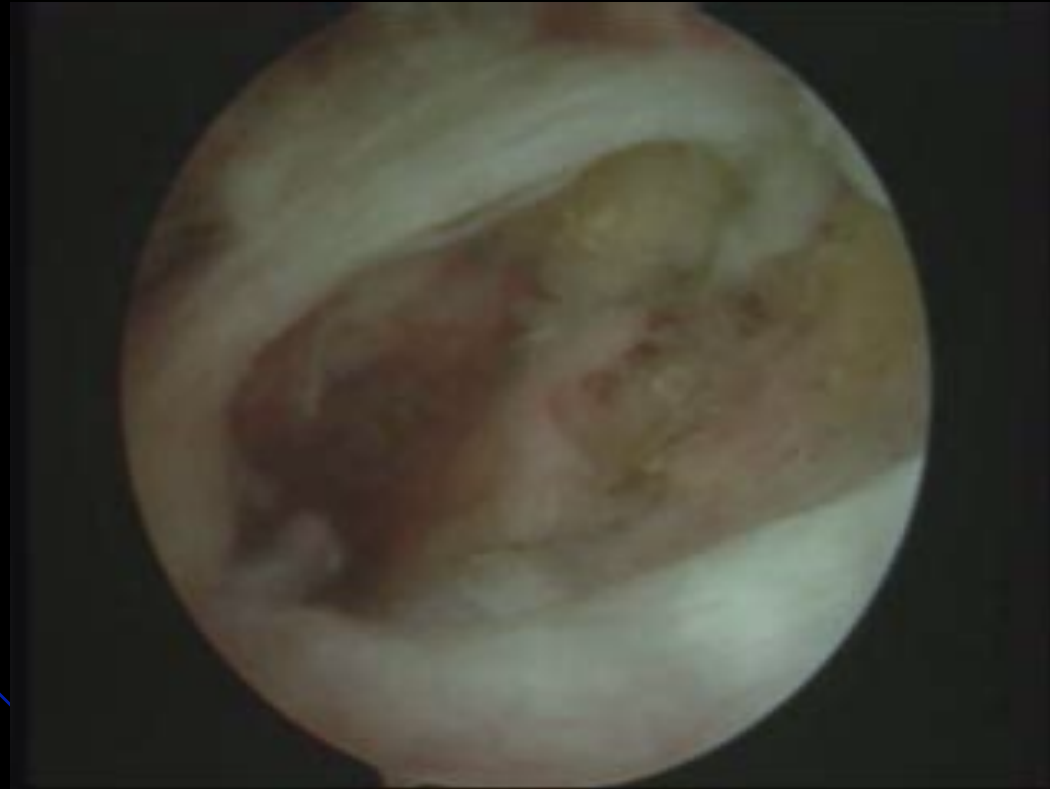
# Acromioplasty





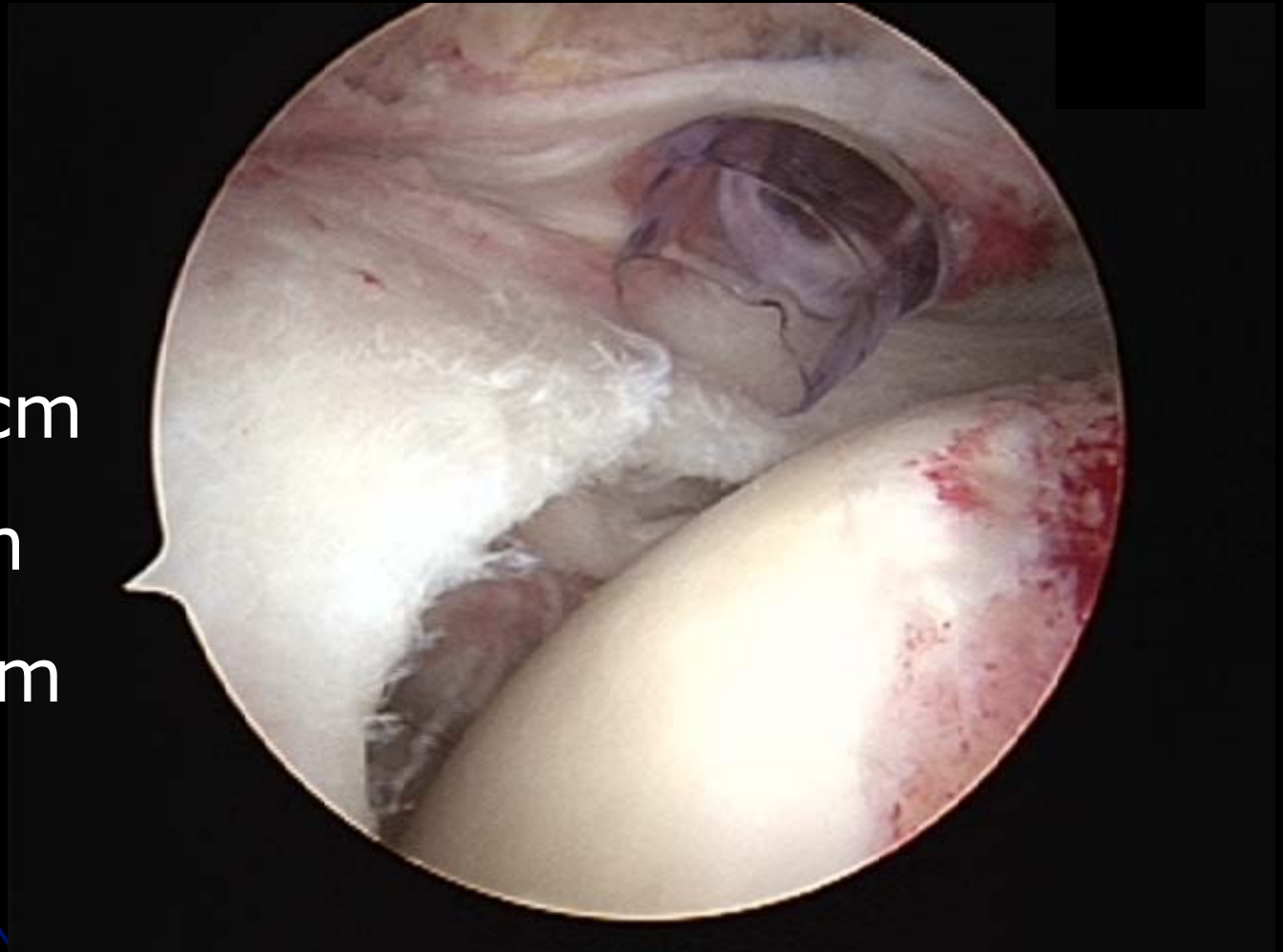


## Complete SS Tear

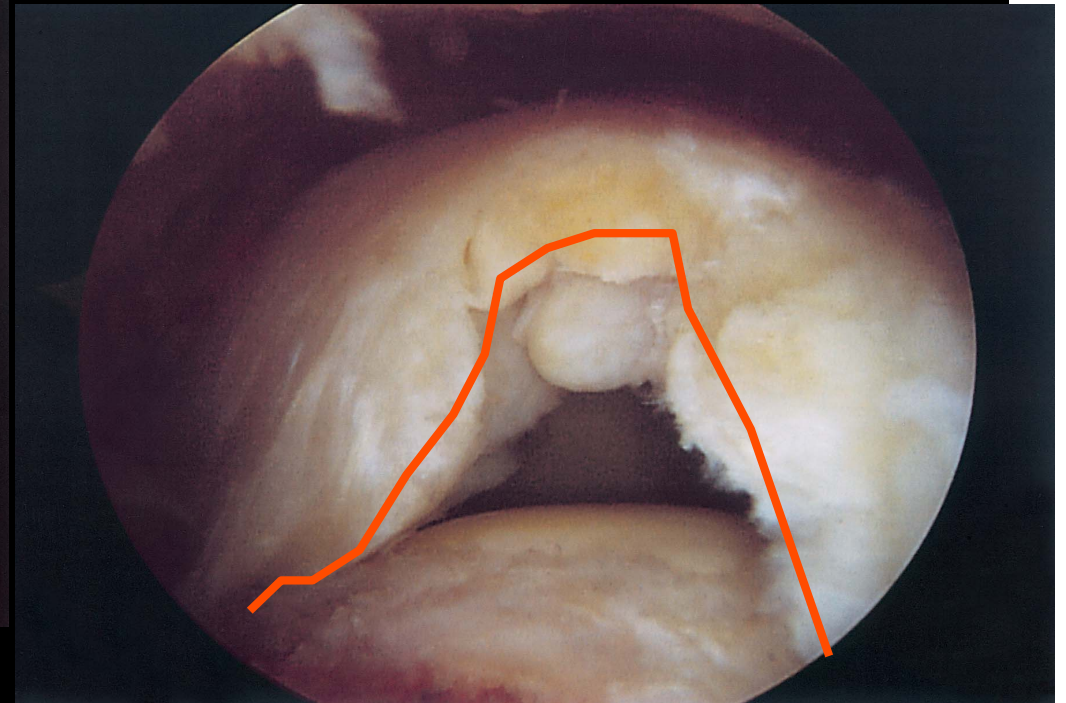
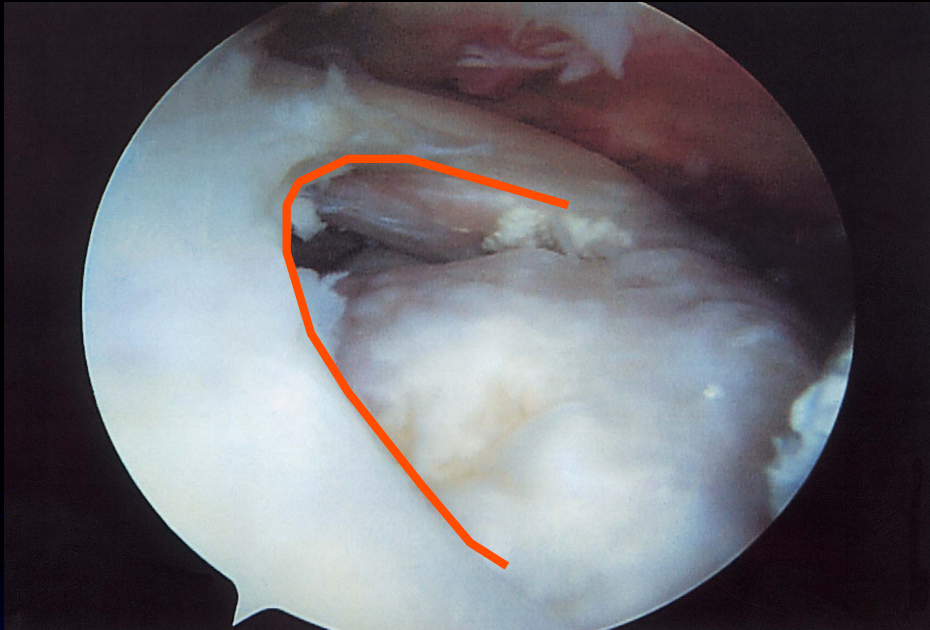


## Full Thickness RC Tears

- Small 1 cm
- Medium 2-3 cm
- Large 3-5 cm
- Massive >5 cm



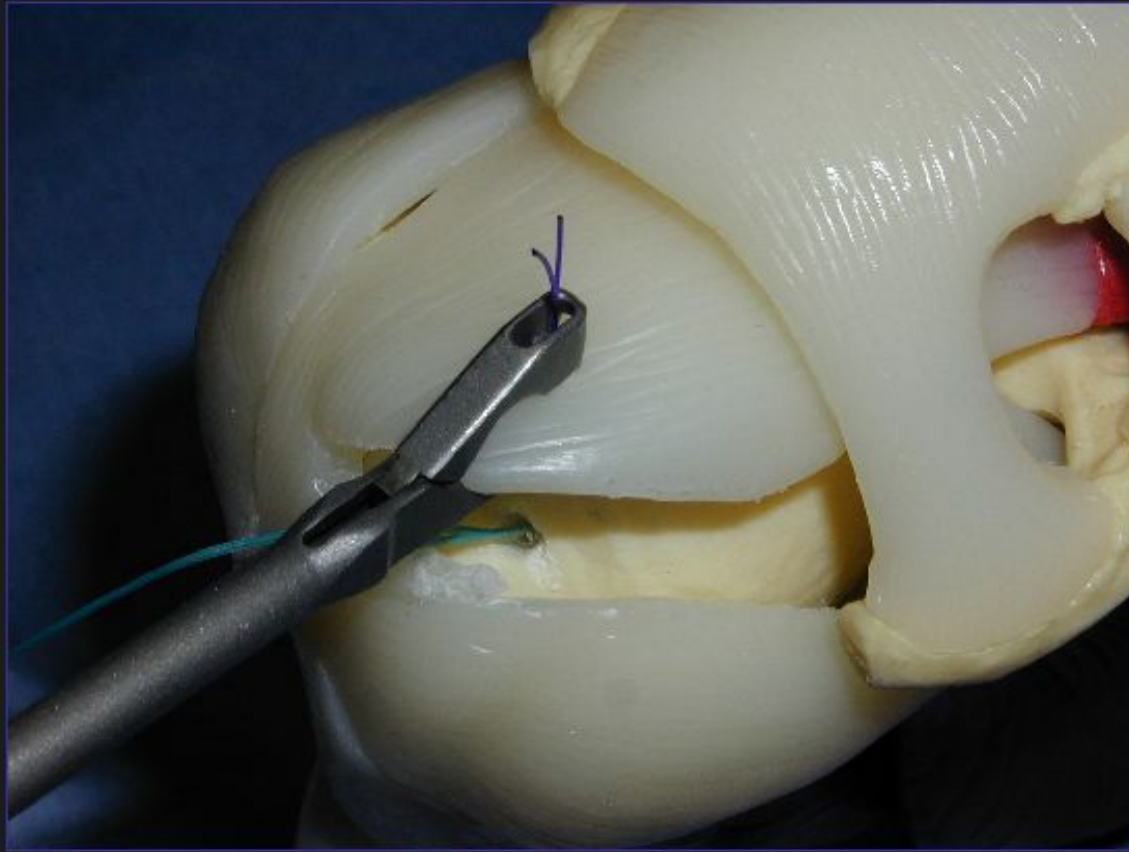
## Complete RC Tears

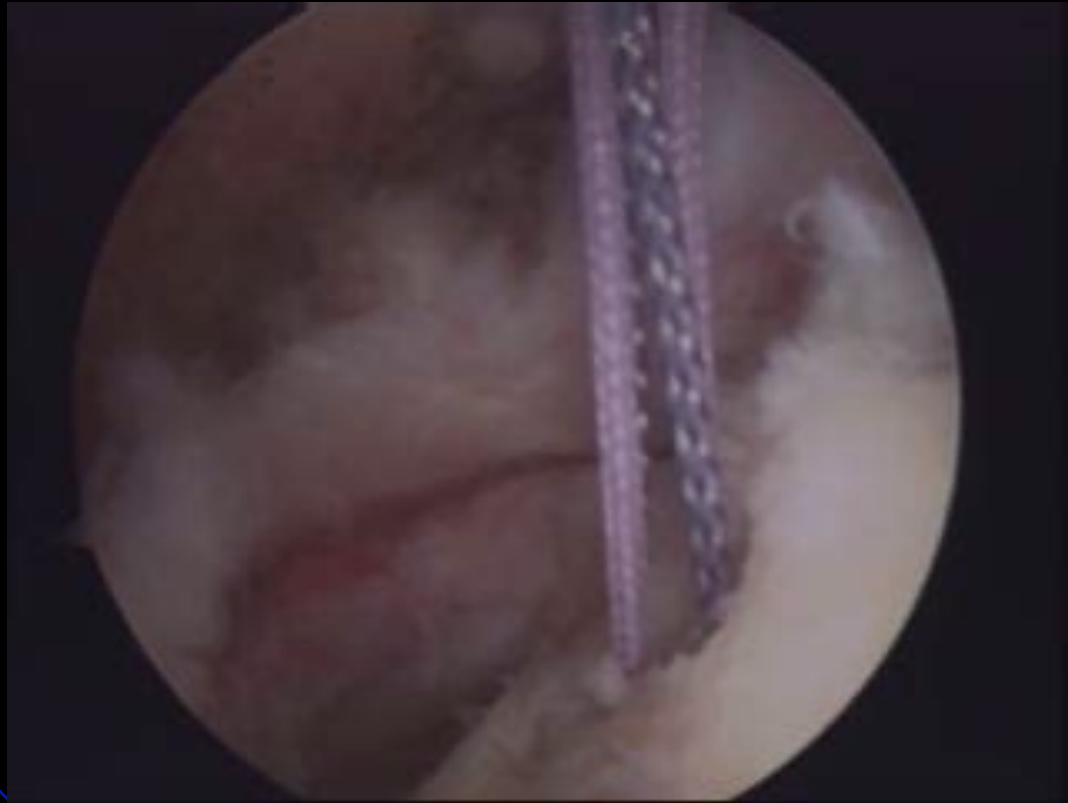


**Crescent type:** semilunar tear


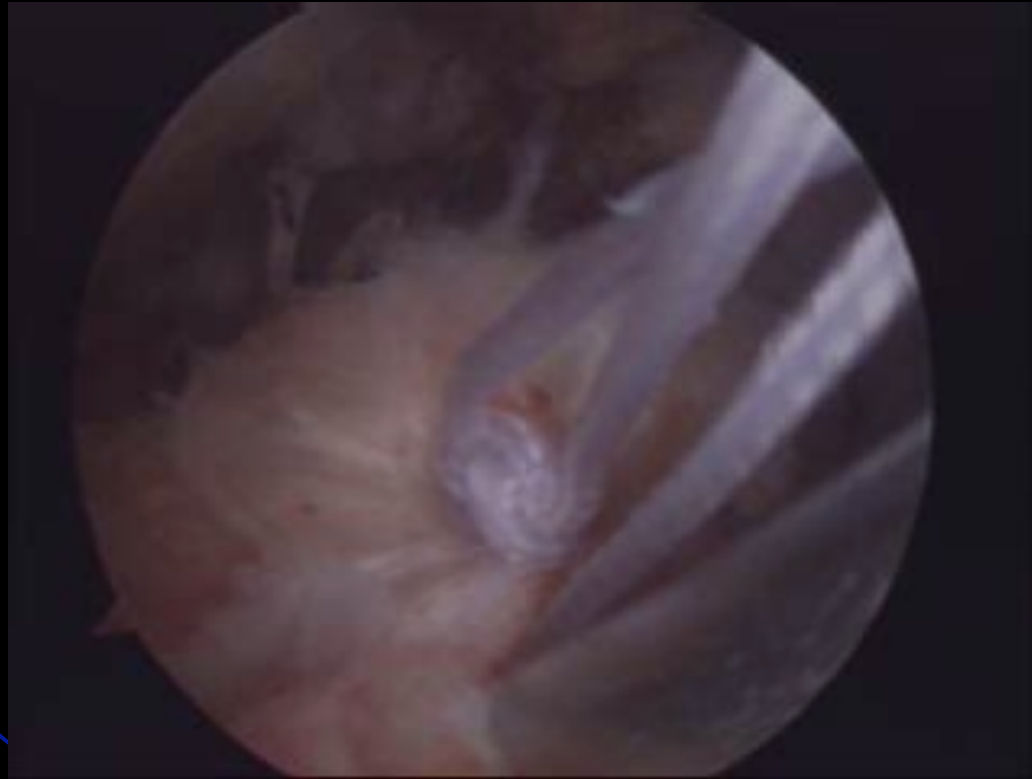
**"V or L-shaped:** there is a medial extension

# Suture Passage


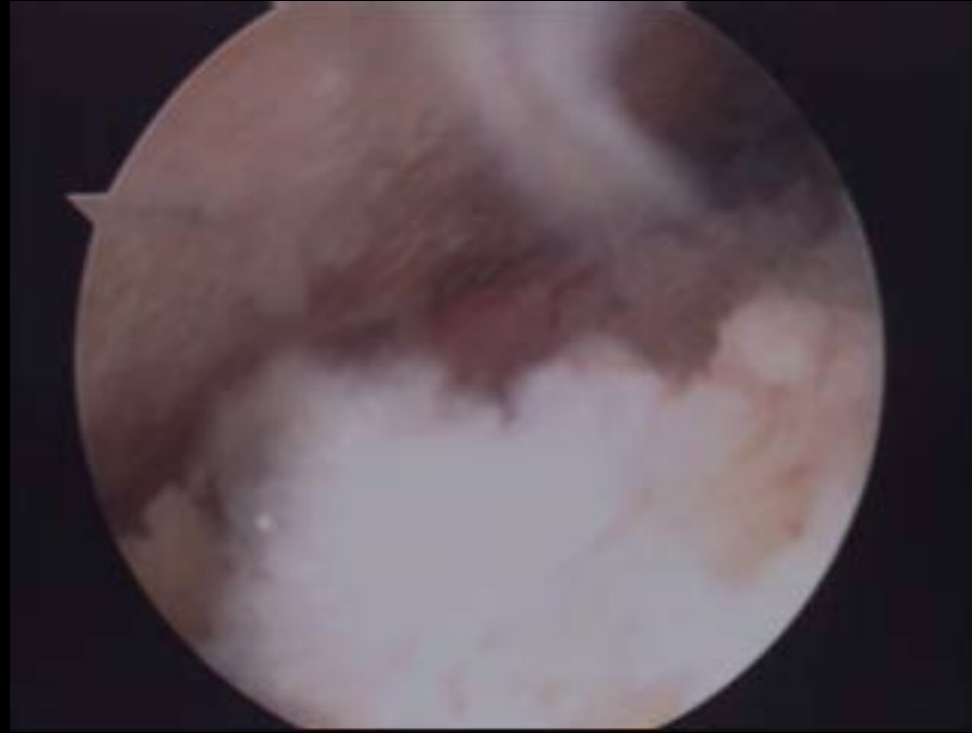


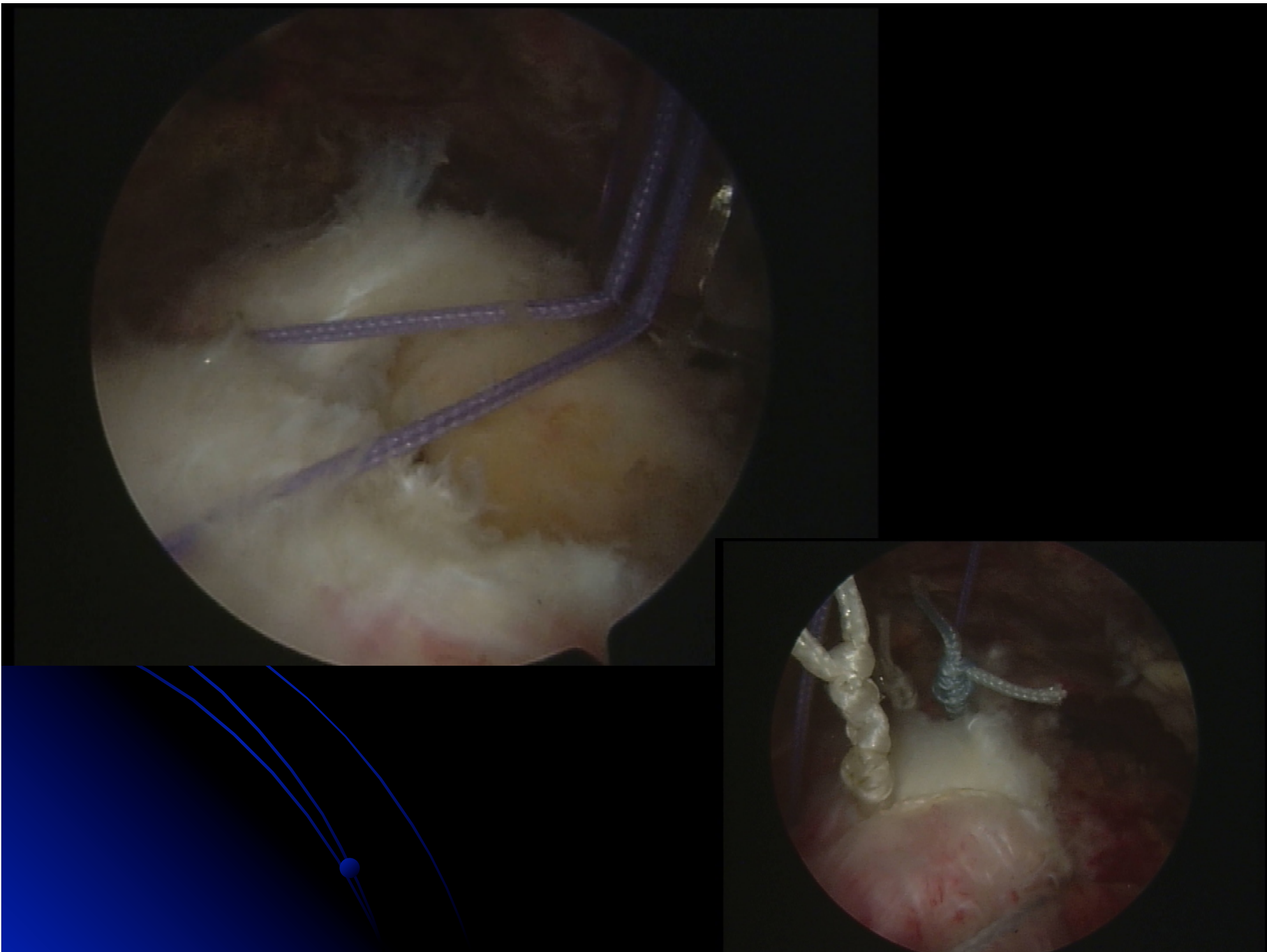


# Knot Tying



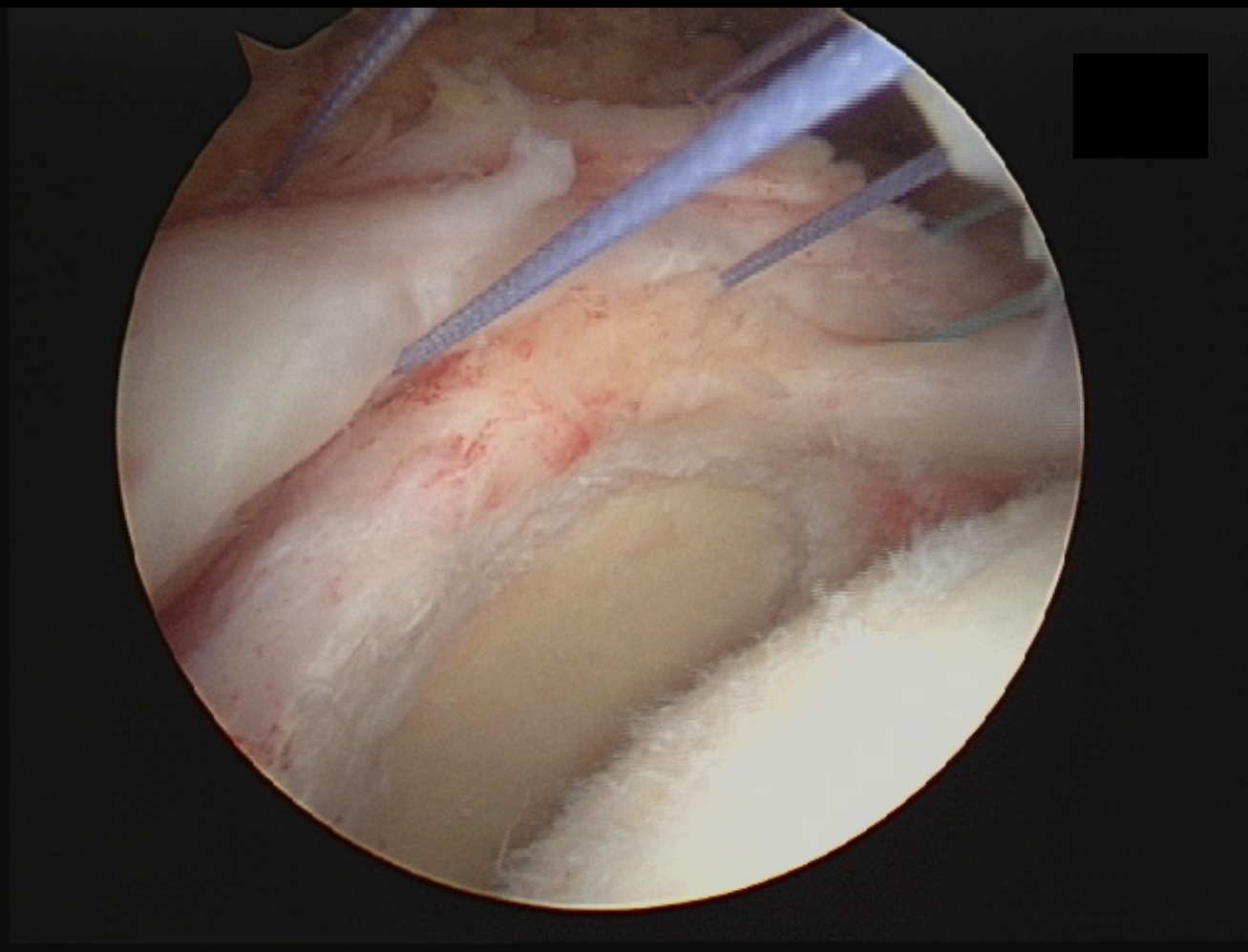
# Final Check of the Repair



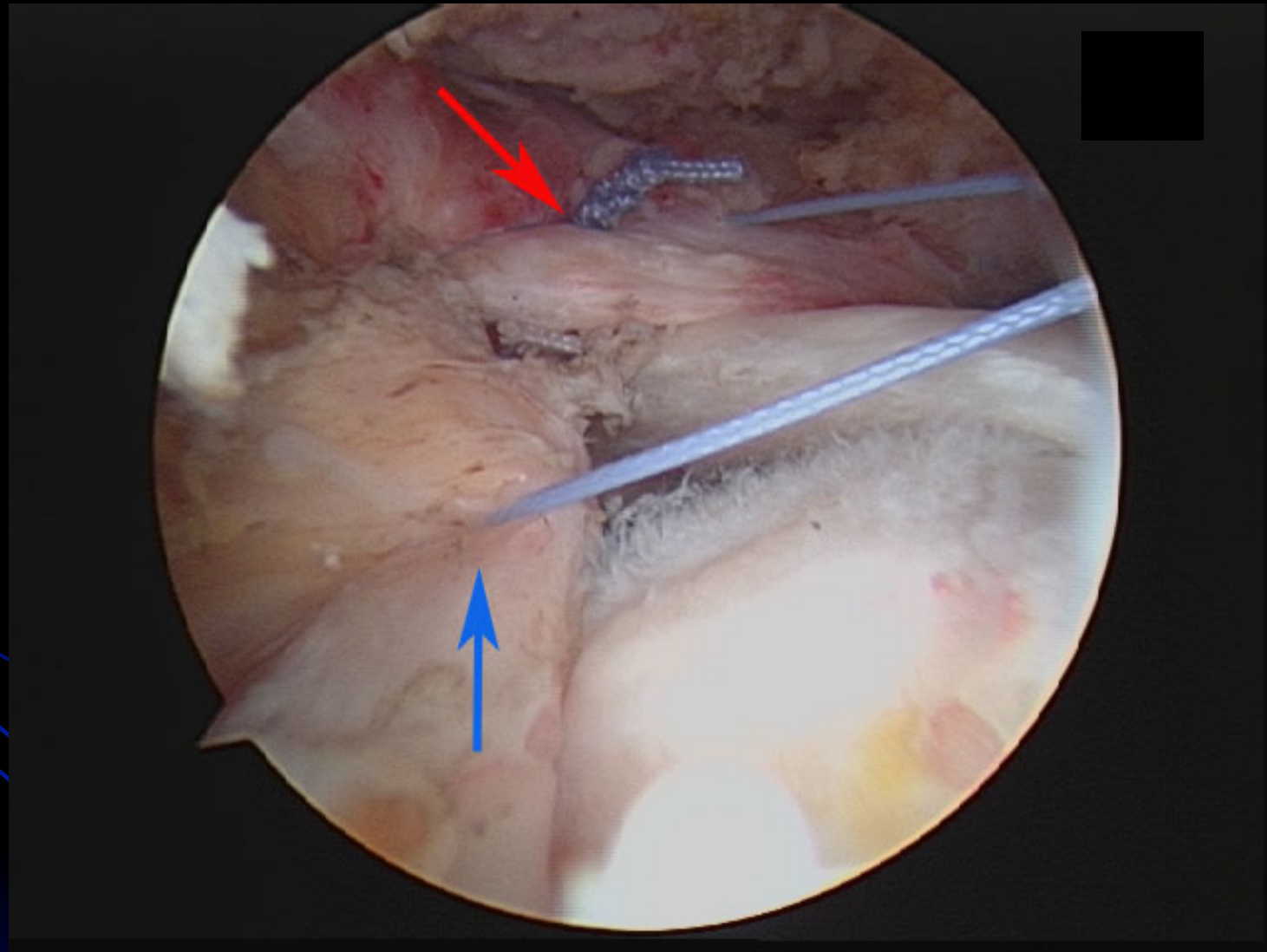




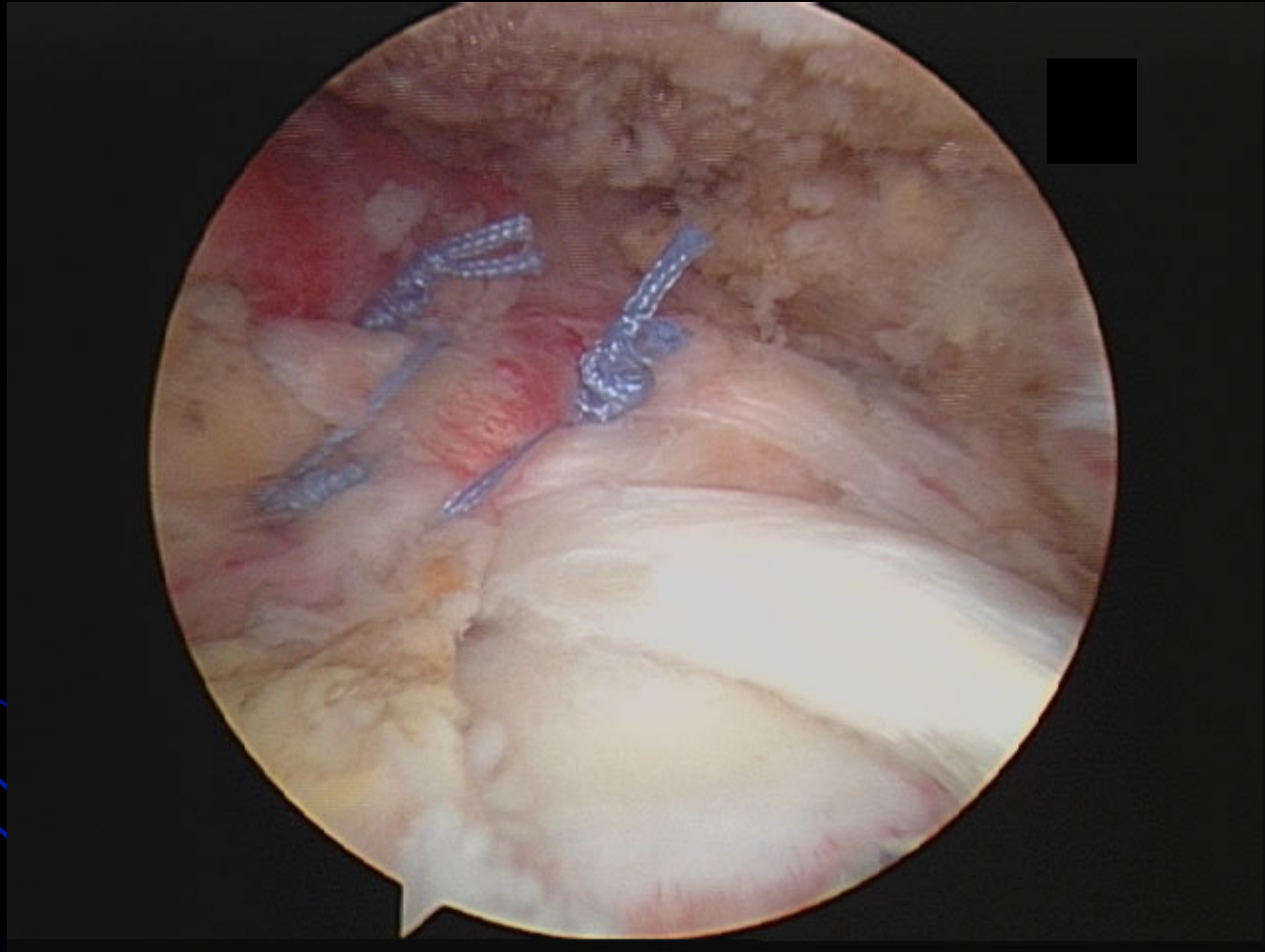
# Massive RC Tears



# Massive RC Tears



# Massive RC Tears



# Παγίδευση Υπερπλάτιου Νεύρου

